



## Editorial

# Retinal fundus image for neurologists and headache medicine specialists

Fernando Korn Malerbi 

Federal University of Sao Paulo, Sao Paulo, Brazil



fernandokmalerbi@gmail.com

The ocular fundus examination is an essential part of the neurological examination, and has long been a fundamental step of headache patients' evaluation; it is especially relevant in the identification of conditions that affect the optic disc, such as optic disc edema (Figure 1).<sup>1</sup> Clinical signs present in the ocular fundus may prompt life- and vision-saving interventions.<sup>1,2</sup>

We conclude that there has been a drastic change in the way humans communicate in the last two years, possibly even with a return to a situation without Covid-19 or living with mild endemics, the world will never go back to what it was in 2019. Exposure to certain precipitating factors of migraine attacks may have changed in frequency and intensity, or even clustering of factors that can trigger a headache attack together. Great adaptations occurred, we would even consider that they were established because of the pandemic, but they proved to be come to stay, facilitating work performance and academic activities.

### Edited by:

Mario F. P. Peres

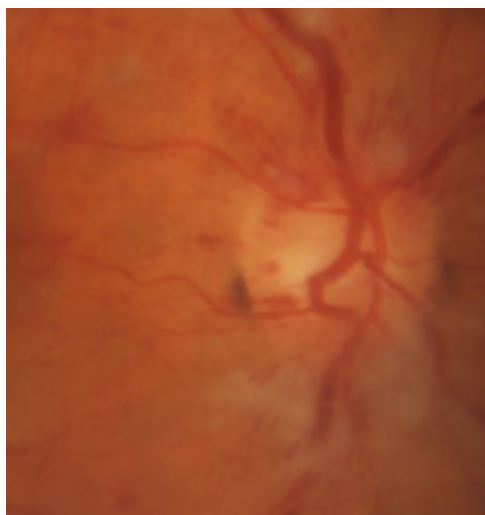


Figure 1. Optic disc edema.

In Neurology, ocular fundus evaluation is also relevant for patients with a transitory ischemic accident (TIA) or acute stroke, since they may present abnormal retinal microvascular signs.<sup>3</sup> In addition, ocular fundus signs evaluation plays a role in the screening of stroke risk, as fundus signs are surrogates for systemic conditions related to such outcome, especially diabetes and systemic arterial hypertension.

Received: August 4, 2022  
Accept: August 15, 2022



Traditionally, ocular fundus examination was performed with the aid of the direct ophthalmoscope, a device created in 1851 by Helmholtz<sup>4</sup> which provides a high magnification but a narrow field of view (5-25°).<sup>2</sup> However, direct ophthalmoscopy is technically difficult to perform; it lacks adequate training and is even sometimes discouraged by preceptors in medical school,<sup>2,5</sup> since medical students also face difficulty of interpreting the findings.<sup>1</sup>

Direct ophthalmoscopy is infrequently and poorly performed by most neurologists; besides the technical difficulty, this skill requires frequent practice.<sup>5,2</sup> Hence, alternative methods to evaluate ocular fundus in clinical practice that are easier to perform would be welcomed by the neurologist. Digital fundus photography is an increasingly popular method which allows efficient and reliable evaluation of the ocular fundus<sup>5</sup>, as well as storage and remote sharing of images with telemedicine integration; it provides a wider field of view (30-45°) in comparison with direct ophthalmoscopy.<sup>2</sup> Retinal photographs may be obtained with traditional, tabletop retinal cameras or, more recently, portable retinal cameras. The quality of images obtained with portable retinal cameras has been assessed, as well as the potential of such method to provide high quality images without pharmacologic pupil dilation in neurology practice.

The Fundus Photography vs Ophthalmoscopy Trial Outcomes in the Emergency Department (FOTO-ED) study<sup>5</sup> included patients with headaches, focal neurological changes, acute visual changes, or diastolic blood pressure  $\geq 120$  mmHg, symptoms and signs generally warranting ocular fundus examination; relevant ocular fundus findings were defined as optic disc edema, retinal hemorrhages, severe hypertensive retinopathy, retinal vascular occlusion, and ocular disc pallor. This study showed that Emergency Department (ED) physicians failed to correctly identify relevant ocular fundus findings by direct ophthalmoscopy, and that nonmydriatic fundus photography was an effective way of evaluating the ocular fundus in the ED.<sup>5</sup>

Other recent studies<sup>2,6</sup> have also evaluated the performance of non-mydriatic fundus photography for cognitive impairment and cerebrovascular disease patients, both in the emergency department and in ambulatory clinics. The performance of portable fundus non-mydriatic cameras in neurological ED patients that presented with headache, cerebrovascular disorder, or acute confusional state was considered superior to regular ophthalmoscopy in defining critical optic disc findings;<sup>6</sup> such images obtained in patients who had suffered from a minor stroke or TIA showed a high prevalence of optic nerve atrophy and retinal ar-

teriolar anomalies, which suggests that the telemedical assessment of the optic nerve head and the retinal vessels is an important part of the neurological examination of such patients.<sup>7</sup>

Even though the quality of fundus images for the evaluation of retinal pathological signs has been reported to improve after pupil dilation<sup>8</sup>, ocular fundus photographs obtained without pupil dilation for neurological purposes, with emphasis on the evaluation of the optic disc, have been considered adequate<sup>5</sup>; in agreement with ophthalmological studies that aimed to evaluate the optic disc for glaucoma.<sup>9</sup> In Headache Medicine, nonmydriatic fundus photography is a promising tool, likely to improve a secondary headache diagnosis due to intracranial hypertension, useful for screening and monitoring, for assessing the vascular component in primary headache disorders, potentially reducing cost (by replacing unnecessary neuroimaging), improving alleviating the burden of disease.

In conclusion, as technology advances, fundoscopic examination based on fundus photography will offer the neurologist the advantages of easier use, portability, and connectivity<sup>2</sup>, thereby circumventing the need to master the use of the direct ophthalmoscope; the proper visualization of the ocular fundus is more important than the method used.<sup>5</sup> In addition, since the neurosensory retina is the only human tissue which allows for direct noninvasive in vivo visualization of the microvascular circulation and the central nervous system, and due to the established association between retinal characteristics – the structure of the neurosensory retina, the retinal microvascular density - and neurological conditions - neurodegenerative diseases such as Alzheimer's and cerebrovascular disease - retinal biomarkers have been searched which could help evaluate the risk and predict the evolution and treatment response of such chronic complex systemic disorders.<sup>2,10</sup> Modern artificial intelligence techniques may provide exciting opportunities for characterization, risk stratification and the predictive value of such associations; current initiatives are already underway for the creation of datasets that will allow the creation of such algorithms.<sup>10</sup>

**Conflict of interest:** The author is a medical advisor for Phelcom Technologies.

**Funding:** The author declares he did not receive any funding for this work.

Fernando Korn Malerbi  
<https://orcid.org/0000-0002-6523-5172>



## References

1. Mackay DD, Garza PS, Bruce BB, Newman NJ and Biousse V. **The demise of direct ophthalmoscopy.** *Neurology: Clinical Practice* 2015;5(2):150-157 Doi:10.1212/cpj.0000000000000115
2. Rodenbeck SJ and Mackay DD. **Examining the ocular fundus in neurology.** *Current Opinion in Neurology* 2019;32(1):105-110 Doi:10.1097/wco.0000000000000637
3. Wang JJ, Baker ML, Hand PJ, Hankey GJ, Lindley RI, Rochtchina E, . . . Mitchell P. **Transient ischemic attack and acute ischemic stroke: associations with retinal microvascular signs.** *Stroke* 2011;42(2):404-408 Doi:10.1161/strokeaha.110.598599
4. Sherman SE. **The history of the ophthalmoscope.** *Doc Ophthalmol* 1989;71(2):221-228 Doi:10.1007/bf00163473
5. Biousse V, Bruce BB and Newman NJ. **Ophthalmoscopy in the 21st century: The 2017 H. Houston Merritt Lecture.** *Neurology* 2018;90(4):167-175 Doi:10.1212/wnl.0000000000004868
6. Alm M, Hautala N, Bloigu R and Huhtakangas J. **Comparison of optic disc evaluation methods in neurology emergency patients.** *Acta Neurol Scand* 2019;140(6):449-451 Doi:10.1111/ane.13167
7. Wolz J, Audebert H, Laumeier I, Ahmadi M, Steinicke M, Ferse C and Michelson G. **Telemedical assessment of optic nerve head and retina in patients after recent minor stroke or TIA.** *Int Ophthalmol* 2017;37(1):39-46 Doi:10.1007/s10792-016-0222-7
8. Malerbi FK, Morales PH, Farah ME, Drummond KR, Mattos TC, Pinheiro AA, . . . Dib SA. **Comparison between binocular indirect ophthalmoscopy and digital retinography for diabetic retinopathy screening: the multicenter Brazilian Type 1 Diabetes Study.** *Diabetol Metab Syndr* 2015;7:116 Doi:10.1186/s13098-015-0110-8
9. Upadhyaya S, Agarwal A, Rengaraj V, Srinivasan K, Newman Casey PA and Schehlein E. **Validation of a portable, non-mydratic fundus camera compared to gold standard dilated fundus examination using slit lamp biomicroscopy for assessing the optic disc for glaucoma.** *Eye (Lond)* 2022;36(2):441-447 Doi:10.1038/s41433-021-01485-2
10. Wagner SK, Fu DJ, Faes L, Liu X, Huemer J, Khalid H, . . . Keane PA. **Insights into Systemic Disease through Retinal Imaging-Based Oculomics.** *Transl Vis Sci Technol* 2020;9(2):6 Doi:10.1167/tvst.9.2.6