

# Histomorphometric analysis of mast cells in different regions of human intracranial dura mater

## Análise histomorfométrica de mastócitos em diferentes regiões da dura-máter intracraniana humana

Emanuela Paz Rosas<sup>1</sup>  
 Silvania Tavares Paz<sup>2</sup>  
 Ana Clara de Souza Neta<sup>3</sup>  
 Raisa Ferreira Costa<sup>4</sup>  
 Ana Paula Fernandes da Silva<sup>1</sup>  
 Manuela Figueiroa Lyra de Freitas<sup>5</sup>  
 Marcelo Moraes Valença<sup>1,4</sup>

<sup>1</sup>Programa de Pós-graduação em Biologia Aplicada à Saúde-LIKA/UFPE;

<sup>2</sup>Programa de Pós-graduação em Saúde Translacional - CCS/UFPE;

<sup>3</sup>Departamento de Nutrição - CCS/UFPE;

<sup>4</sup>Programa de Pós-graduação em Ciências Biológicas - CB/UFPE.

<sup>5</sup>Departamento de Anatomia - CB/UFPE, Recife, Pernambuco, Brazil.

### ABSTRACT

**Objective:** To analyze mast cell histomorphometry in three different regions of the human intracranial dura mater. **Method:** Three specimens of dura mater were collected after approval by the Ethics Committee (CAAE No. 57692216.5.0000.5208). Each dura mater was obtained from human cadavers between 7 and 24 hours after death. After collection, the samples were fixed, cut into two fragments and longitudinally placed in the following way: external (periosteum) and internal (meningeal) sides. The fragments (1.5 cm<sup>2</sup>) were taken from three different regions: proximity of the right middle meningeal artery, the proximity of the left middle meningeal artery and superior sagittal sinus. These fragments were submitted to microtomy (10 Qm), stained with 0.1% toluidine blue and analyzed by optical microscopy. The histomorphometric parameters adopted were: the distance from the mast cells to the vessels, the number and if the mast cells were degranulated. Five fields from each case were analyzed. For this analysis, the Image J 1.52a 2019 software was used. **Results:** A higher number of mast cells was observed in the periosteal layer when compared with the meningeal layer ( $p=0.026$ ). When the distribution of the mast cells was evaluated, we observed that the cells were localized in the proximity of the middle meningeal artery ( $p<0.05$ ). **Conclusion:** In human dura mater, the mast cells are localized in the proximity of dural arteries.

**Keywords:** Mast cell; Dura mater; Human; Meningeal artery; Migraine.

### RESUMO

**Objetivo:** Analisar a histomorfometria dos mastócitos em três regiões diferentes da dura-máter intracraniana humana. **Método:** Três amostras de dura-máter foram coletadas após aprovação pelo Comitê de Ética (CAAE nº 57692216.5.0000.5208). Cada dura-máter foi obtida de cadáveres humanos entre 7 e 24 horas após a morte. Após a coleta, as amostras foram fixadas, cortadas em dois fragmentos e dispostas longitudinalmente da seguinte maneira: face externa (periósteo) e interna (meníngeo). Os fragmentos (1,5 cm<sup>2</sup>) foram retirados de três regiões diferentes: proximidade da artéria meníngeo média direita, proximidade da artéria meníngeo média esquerda e seio sagital superior. Esses fragmentos foram submetidos à microtomia (10 Qm), corados com azul de toluidina a 0,1% e analisados por microscopia óptica. Os parâmetros histomorfométricos adotados foram: distância dos mastócitos aos vasos, número e se os mastócitos estavam desgranulados. Foram analisados cinco campos de cada espécime. Para esta análise, foi utilizado o software Image J 1.52a 2019. **Resultados:** Observou-se maior número de mastócitos na camada periosteal quando comparada à camada meníngeo ( $p = 0,026$ ). Quando avaliada a distribuição dos mastócitos, observamos que as células estavam localizadas nas proximidades da artéria meníngeo média ( $p < 0,05$ ). **Conclusão:** Na dura-máter humana, os mastócitos estão localizados nas proximidades das artérias durais.

**Descritores:** Mastócito; Dura-máter; Humano; Artéria meníngeo; Enxaqueca.

#### \*Correspondence

Emanuela Paz Rosas  
 E-mail: manu\_pathy@hotmail.com

Received: April 2, 2019.

Accepted: May 4, 2019.

## INTRODUCTION

Recent evidence strongly suggests a vital role of dura mater mast cell in the genesis of migraine.<sup>1-5</sup>

Gupta and Harvima described the mast cells as a “powerhouse” since they release “algogenic and pruritogenic mediators, which initiate a reciprocal communication with specific nociceptors on sensory nerve fibers.”<sup>6</sup>

Mast cells are cells found in abundance in the dura mater and by local mechanism regulates vascular and neural functions, releasing substances such as histamine. Scientific evidence suggests that mast cells participate in the pathophysiology of triggering a migraine attack by inducing local sterile inflammation near the dura mater nociceptors.

Curiously, the mast cells are located in the proximity of the arteries in the dura mater, in close association with neurons. These cells appear to be activated through the trigeminal nerve. It is postulated that many neuropeptides, namely calcitonin gene-related peptide (CGRP), hemokinin A, neurotensin (NT), pituitary adenylate cyclase-activating peptide (PACAP), and substance P may activate mast cells, resulting in the release of vasoactive and pro-inflammatory mediators, involved in the pathophysiology of migraine.<sup>4</sup> Mast cells can also release substances with pro-inflammatory and vasoactive actions (e.g., interleukin-6 and vascular endothelial growth factor (VEGF)).<sup>4</sup>

The objective of the present study was to analyze mast cell histomorphometry in three different regions of the human intracranial dura mater.

## METHOD

Three specimens of dura mater were collected after approval by the Ethics Committee (CAAE No. 57692216.5.0000.5208).

Each dura mater was obtained from human cadavers between 7 and 24 hours after death.

After collection, the samples were fixed, cut into two fragments and longitudinally placed in the following way: external (periosteum) and internal (meningeal) sides.

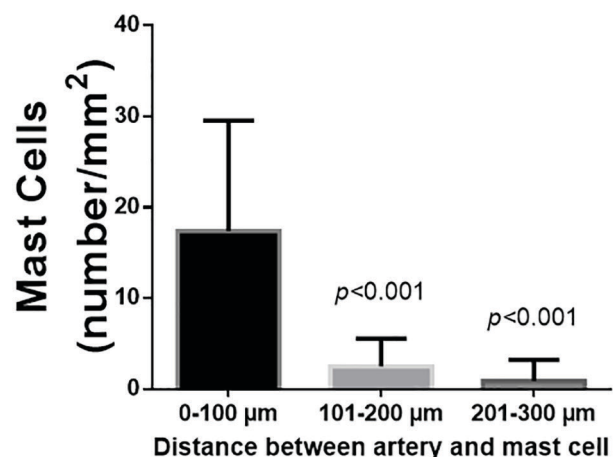
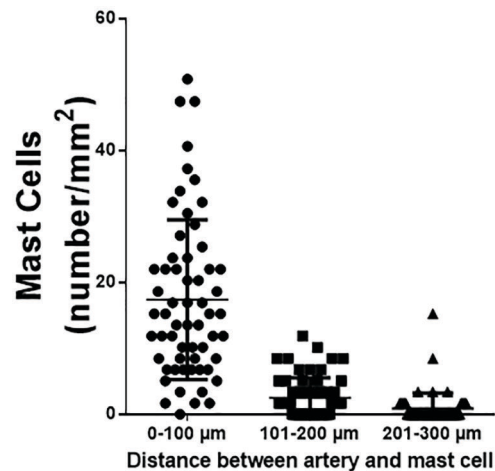
The fragments (1.5 cm<sup>2</sup>) were taken from three different regions: proximity of the right middle meningeal artery, the proximity of the left middle meningeal artery and superior sagittal sinus.

These fragments were submitted to microtomy (10 Qm), stained with 0.1% toluidine blue and analyzed by optical microscopy. The histomorphometric parameters adopted were: the distance from the mast cells to the vessels, the number and if the mast cells were degranulated. Five fields from each case were analyzed. For this analysis, the Image J 1.52a 2019 software was used.

## RESULTS AND DISCUSSION

A higher number of mast cells was observed in the periosteal layer when compared with the meningeal layer ( $p=0.026$ ).

When the distribution of the mast cells was evaluated, we observed that the cells were localized in the proximity of the middle meningeal artery (Figure 1), suggesting that there is a significant role played by the mast cells in dura mater to regulate vascular function. Probably the relationship between mast cells and meningeal arteries is an essential component in the migraine pathogenesis.



**Figure 1.** Mast cell density per mm<sup>2</sup> in relation to the distance to the vessel. P versus 0-100 Qm group, Kruskal-Wallis test and Dunn’s multiple comparisons test.

The distance between the artery and the mast cell was measured in 153 cells (57 65 m, min 0 - max 247; median 33, 95%IC 46-67). No differences were observed in the concentration of mast cells in convexity of the dura mater versus the superior sagittal sinus.

In his study, with human dura mater postmortem, 60-70% of the mast cells were degranulated. Migraine is a disorder with significant autonomic dysfunction. Clinically, long-lasting flushing suggests degranulation of mast cells.<sup>5</sup>

In conclusion, in human dura mater, the mast cells are localized in the proximity of dural arteries.

## REFERENCES

- Okragly AJ, Morin SM, DeRosa D, Martin AP, Johnson KW, Johnson MP, Benschop RJ. Human mast cells release the



- migraine-inducing factor pituitary adenylate cyclase-activating polypeptide (PACAP). *Cephalalgia*. 2018 Aug;38(9):1564-1574. doi: 10.1177/0333102417740563. Epub 2017 Nov 5.
2. Kilinc E, Dagistan Y, Kukner A, Yilmaz B, Agus S, Soyler G, Tore F. Salmon calcitonin ameliorates migraine pain through modulation of CGRP release and dural **mast cell degranulation in rats**. *Clin Exp Pharmacol Physiol*. 2018 Jun;45(6):536-546. doi: 10.1111/1440-1681.12915. Epub 2018 Feb 13.
  3. Baun M, Pedersen MH, Olesen J, Jansen-Olesen I. Dural mast cell degranulation is a putative mechanism for headache induced by PACAP-38. *Cephalalgia*. 2012 Mar;32(4):337-45. doi: 10.1177/0333102412439354.
  4. Theoharides TC, Donelan J, Kandere-Grzybowska K, Konstantinidou A. The role of mast cells in migraine pathophysiology. *Brain Res Brain Res Rev*. 2005 Jul;49(1):65-76.
  5. Jansen-Olesen I, Hougaard Pedersen S. PACAP and its receptors in cranial arteries and mast cells. *J Headache Pain*. 2018 Feb 20;19(1):16. doi: 10.1186/s10194-017-0822-2.
  6. Kalpna Gupta, Ilkka T. Harvima. Mast cell-neural interactions contribute to pain and itch *Immunol Rev*. Author manuscript; available in PMC 2019 Mar 1. Published in final edited form as: *Immunol Rev*. 2018 Mar; 282(1): 168-187. doi: 10.1111/imr.12622