



Case Report

Frontal brain cavernoma in a 14-year-old boy: differential diagnosis of secondary headache

Eduardo de Almeida Guimarães Nogueira , Marcos Vinicius de Queiroz, Philipe Rachas Saccab, Marcelo Motta Zanatelli 

Portuguese Society of Beneficence of Santos, Clinical Medicine, Santos, São Paulo, Brazil



Eduardo de Almeida Guimarães
Nogueira
eduagn@hotmail.com

Edited by

Mario Fernando Prieto Peres

Keywords:

Headache
Cerebral Hemorrhage
Frontal Lobe

Abstract

Cavernoma consists of a rare type of vascular anomaly that can present with different neurological manifestations. This article reports a case of cavernoma in a 14-year-old boy, whose first symptom was headache

Received: September 20, 2020
Accepted: November 30, 2020



Introduction

Cavernoma is a rare type of vascular anomaly¹ characterized by constituting a space lacking in the brain parenchyma, filled mainly by dilated sinusoidal veins.² It affects mostly males in the third decade of life and is divided into sporadic or familial.³ The aim of this article is to report a case of cavernoma in a young patient and draw attention to this pathological entity as a cause of secondary headache.

Material and Methods

The data contained in this report were obtained through interview with the patient and his family members, and review of the medical record.

Case Report

A 14-year-old male patient was brought to the emergency room on the morning of Nov. 11th, 2020, with a complaint of frontal shooting headache, fever (38°C), and an episode of vomiting preceded by nausea the night before.

The patient was previously healthy, was not taking any medication continuously, and had never undergone any surgical procedures. The mother reported that during intrauterine life, the patient developed only one umbilical artery, and that he was followed by a neurosurgeon during the first four years of life, due to an above average brain girth. As he never manifested any neurological symptoms, he was discharged. She also informed that her son had suffered two head traumas throughout his life, both in the frontal region of the skull, the last one three years prior to the report. Both accidents did not cause major repercussions.

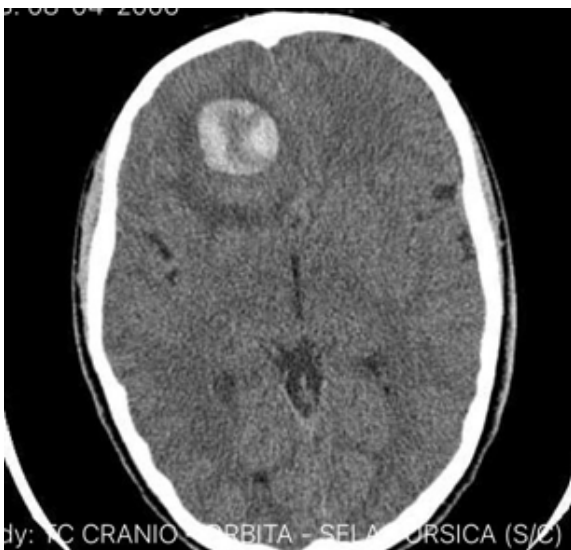

Figure 1. Entry CT scan showing right frontal cavernoma.

The physician on duty requested a complete blood count and urine test, both within normal limits. Besides the laboratory tests, the patient had a chest X-ray and a CT scan of the skull without contrast. The X-ray showed no changes, but the CT scan showed a rounded, heterogeneous lesion with well-defined contours in the right frontal lobe, compressing the ventricle and deviating the midline.

The patient was evaluated by the neurosurgery team, which suggested the possibility of a vascular malformation and advised that a magnetic resonance imaging of the brain be performed. The patient was sent to the intensive care unit (ICU) with a prescription for intravenous corticosteroids and prophylactic intravenous phenytoin.

He was admitted to the ICU asymptomatic, with a completely normal neurological examination without any focal deficits, speech, or ocular changes.

Magnetic resonance imaging (MRI) of the brain was performed and revealed a recent hemorrhagic lesion with slight contrast enhancement with mild deviation of midline structures and compression of the frontal horns of the lateral ventricles, more accentuated on the right, measuring 2.6 x 3.5 x 2.7 cm, confirming the hypothesis of cerebral cavernoma.

The patient underwent surgery with no major intercurrents and was released 72 hours later after a control CT scan was performed.

Discussion

Cryptic hemangiomas or cerebral hamartomas, also called cavernomas are lesions easily visualized on CT scans due to their hyperdense nodular formation. The most common symptoms reported are epileptic seizures, headache, and dizziness.⁴

Vaquero et al.³ reported 16 cases of brain cavernomas, with 50% presenting with seizures, 37.5% manifesting focal symptoms and 12.5% intracerebral hemorrhages. The frontal lobe was the second site with the highest incidence of hamartoma (25%), second only to the parietal lobe (31%). The exam of choice for the diagnosis of cavernoma is magnetic resonance imaging of the brain. Since most of the time the anomaly is not connected to adjacent arteries, angiography is unnecessary.

In 1994, Zabramski et al.⁵ created a classification that groups cavernomas into groups I through IV according to their appearance on MRI.⁴ The most encountered type is II, also called "popcorn" lesion due to the heterogeneous appearance, since in many cases, the nodulation is surrounded by a hyperintense halo due to the presence of hemorrhage.¹

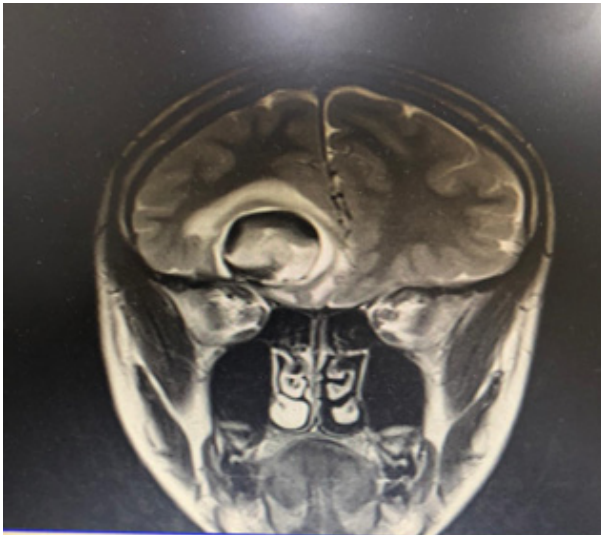

Figure 2. Magnetic resonance imaging of the brain showing Zabramski cavernoma 1.

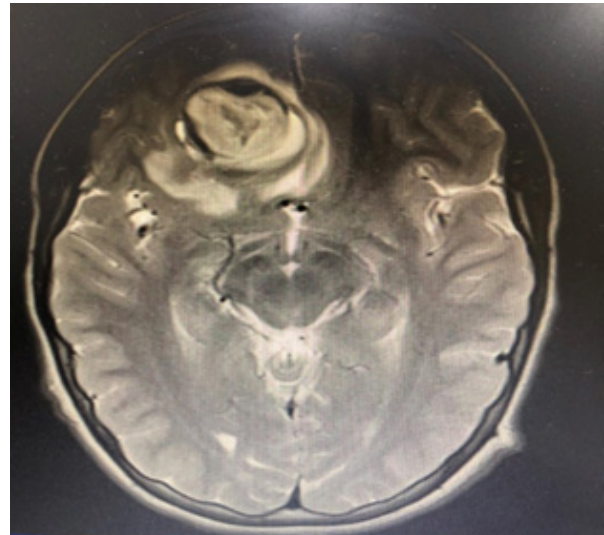


Figure 3. Coronal MRI section of the brain Cavernoma Zabramski 1

The case we report presented with sudden headache of strong intensity, originating from an intracerebral hemorrhage that through a mass effect raised the intracranial pressure and shifted the midline.

Studies show that up to 18% of patients who go to the emergency room with headache complaints have a secondary cause for their pain.⁶

SNNOOP 10 (Systemic, Neoplasm, Neurologic, Onset, Older, Pattern) is a mnemonic tool for physicians to remember the warning signs for further investigation when encountering a headache in the emergency.⁶

The patient had a sudden onset headache (Onset) and the first crisis of his life (Pattern), so investigation with the imaging exam that found the lesion was necessary.

The third revision of the International Classification of Headache Disorders (ICHD-3) classifies headache due to non-traumatic intracranial hemorrhage as item 6.2, in the secondary headache session.⁷

There are eight sessions devoted to secondary headaches, with the one attributed to cranial or cervical vascular disorder being the second session.

Author's contributions: EAGN- methodology, writing, preparation of the original; MNVQ- data collect; PRS- investigation, supervision; MZ- methodology, writing, review and editing, supervision

Financing source: No
Conflict of interests: No

Eduardo de Almeida Guimarães Nogueira

<https://orcid.org/0000-0002-6035-560X>

Marcelo Motta Zanatelli

<https://orcid.org/0000-0001-7146-082X>

References

1. Cisneros O, Rehmani R, Garcia de de Jesus K. Cerebellar Cavernous Malformation (Cavernoma): A Case Report. *Cureus*. 2019; 11(4): e4371. DOI 10.7759/cureus.437.
2. Boukobza M et. al. Cerebral Developmental Venous Anomalies Associated with Head and Neck Venous Malformations. *AJNR*. 1996; 17:987–994.
3. Vaquero J, Leunda G, Martínez R, Bravo G. Cavernomas of the Brain. *NEUROSURGERY*. 1983; 12(2):208-210
4. Lefaucher R, Derrey S, Lebas A, Wallon D, Maltête D. Unilateral postural tremor caused by frontal cavernoma. *Clinical Neurology and Neurosurgery*. 2014; 125: 237-238.
5. Zabramski, J. M., Wascher, T. M., Spetzler, R. F., Johnson, B., Golfinos, J., Drayer, B. P., Brown, B., Rigamonti, D., & Brown, G. (1994). The natural history of familial cavernous malformations: results of an ongoing study, *Journal of Neurosurgery*, 80(3), 422-432.
6. Phu Do T, Schakin C, Schytz HW, Obermann M. Red and orange flags for secondary headaches in clinical practice: SNNOOP10 list. *Neurology*. 2018; 92(3): 10.1212/WNL.0000000000006697
7. Headache Classification Committee of the International Headache Society (IHS). The International Classification of Headache Disorders, 3rd edition. *Cephalalgia*. 2018; 38(1): 1–211.