

Headache as a single clinical manifestation of a colloid cyst in the third ventricle

Cefaleia como manifestação clínica única de um cisto colóide do terceiro ventrículo

Marcelo Moraes Valença¹, Helysânia Shádylla Santos de Farias¹, Laryssa Crystinne Azevedo Almeida¹,
Cassia Luana dos Santos França¹, Karolyne Ernesto Luiz Nobre², Marcelo Andrade Valença¹,
Mário Luciano de Mélo Silva Júnior¹, Luciana Patrícia Alves de Andrade Valença¹

¹Neurosurgery and Neurology Unit, Federal University of Pernambuco, Recife, Pernambuco, Brazil
²FCM, Campina Grande, Paraíba, Brazil

Valença MM, Farias HSS, Almeida LCA, França CLS, Nobre K, Valença MA, Silva Júnior MLM, Valença LPAA.
Headache as a single clinical manifestation of a colloid cyst in the third ventricle. Headache Medicine. 2017;8(1):25

INTRODUCTION

The colloid cyst of the third ventricle is a rare tumor. Its estimated incidence is 3 cases per million inhabitants per year.⁽¹⁾ With the more frequent use of neuroimaging, many of the colloid cysts of the third ventricle are incidental findings, so they are asymptomatic lesions.⁽¹⁾

In a large series of 163 cases, only 40% of the individuals with colloid cyst of the third ventricle were symptomatic.

CASE REPORT

In this article, the authors wish to show the images (Figure 1) obtained by MR of a 32-year-old woman complaining of one week of a history of severe, pulsatile, holocranial and continuous headache, partially alleviated

with analgesics. There was a progressive increase in pain intensity until a week later when she had a very severe headache, referred to as the worst she experienced in her life, associated with visual impairment, nausea, photo- and phonophobia. Vomiting was not present and she had no previous history of primary headache.

This type of headache associated with colloid cyst of the third ventricle should be valued because the cyst may obstruct the foramen of Monro, causing obstruction in the CSF passage, leading to acute hydrocephalus and sudden death.^(1,2)

REFERENCE

1. Beaumont TL, Limbrick DD Jr, Rich KM, Wippold FJ 2nd, Dacey RG Jr. Natural history of colloid cysts of the third ventricle. *J Neurosurg.* 2016 Dec;125(6):1420-1430. Epub 2016 Mar 11.
2. Spears RC. Colloid cyst headache. *Curr Pain Headache Rep.* 2004 Aug;8(4):297-300.

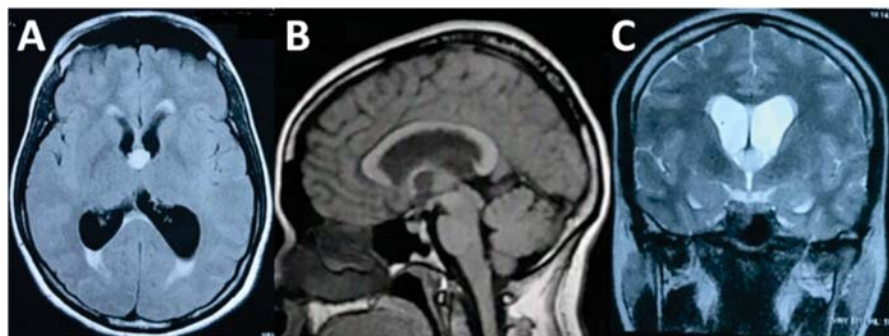


Figure 1. Images obtained by magnetic resonance of the encephalon in the transverse, sagittal and coronal sections.

Received: January 29, 2017
Accepted: February 5, 2017