



# Tourette's Syndrome cervical dystonia induced occipital neuralgia remedied by peripheral nerve stimulation: A case report

Crystal Joseph<sup>1</sup> , Anishinder Parkash<sup>2</sup>, John Gallagher<sup>2</sup>, Ahish Chitneni<sup>3</sup>, Hirsh Kaveeshvar<sup>4</sup>

<sup>1</sup>Department of Anesthesiology, Beth Israel Deaconess Medical Center, Boston, MA, PA, United States

<sup>2</sup>Department of Physical Medicine and Rehabilitation, Tower Health Reading Hospital, West Reading, Berks County, PA, United States

<sup>3</sup>Department of Rehabilitation and Regenerative Medicine, New York-Presbyterian Hospital-Columbia and Cornell, New York, New York County, NY, United States

<sup>4</sup>Synergex Med, Los Angeles, Los Angeles County, CA, United States



Crystal Joseph  
crystaljoseph14@gmail.com

**Edited by:**  
Marcelo Moraes Valença

### Background

Dystonia is uncommon in Tourette's syndrome, and occipital neuralgia secondary to Tourette's dystonia is more rare, affecting quality of life. Occipital peripheral nerve stimulation (PNS) is an excellent alternative by being adjustable and minimally invasive. Our case demonstrates occipital PNS as an effective option for refractory Tourette's dystonia.

### Case Presentation

A thirty-four-year-old male with poorly controlled Tourette's cervical dystonia presented with severe occipital neuralgia. Various medications were prescribed including propranolol and amitriptyline, and bilateral third-occipital nerve rhizotomies and occipital nerve blocks were trialed. Distal nerve blocks at the occipital protuberance were most effective. Therefore, an occipital PNS trial was done, and a PNS was implanted with no complications. Upon follow-up, the patient reported drastic pain reduction.

### Conclusion

Our case illustrates neuromodulation benefits for a rare presentation of refractory occipital neuralgia secondary to Tourette's-related dystonia. Occipital PNS should be considered for refractory cases because it is safe, easy to implant, and effective.

### Keywords:

Pain medicine  
Acute pain  
Chronic pain  
Occipital neuralgia  
Tourette's syndrome  
Peripheral nerve stimulation



## Introduction

First described by neurologist Georges Gilles la Tourette, Tourette's syndrome is a neuropsychiatric disorder characterized by simple and complex motor and phonic tics and instances of obsessive-compulsive behavior.<sup>1</sup> According to the Diagnostic and Statistical Manual of Mental Disorders, Tourette's is diagnosed before the age of 18, and persists for greater than one year without a secondary cause.<sup>1</sup> Sensory urges commonly occur prior to the tic.

Sustained motor tics, defined as dystonia, are uncommon and can be life-altering.

According to the Tourette Syndrome International Database Consortium, approximately 9 cases describe dystonia in Tourette's syndrome, translating to a prevalence of 1352 per 1,000,000.<sup>(2)</sup> Moreover, the incidence of Tourette's dystonia ranges from as uncommon as 300 to 500 per 1,000,000 to as common as 5% in the general population.<sup>2</sup> However, in the Tourette Syndrome International Database Consortium, only one case involved cervical dystonia, which was drug related.<sup>3</sup>

Even more uncommon is occipital neuralgia secondary to Tourette's cervical dystonia.

According to the International Classification of Headache Disorders (ICHD), occipital neuralgia, or C2 neuralgia, is described as persistent, paroxysmal, aggravating, shooting, or stabbing pain covering greater and lesser occipital nerve dermatomes.<sup>4</sup> The pain originates at the occiput and radiates throughout the upper neck, rising superiorly on the posterior scalp, with potential retro-orbital sensations. Hyperesthesia or dysesthesia can also occur. Occipital neuralgia occurs from compression of the greater (90%) or lesser (10%) occipital nerves. Cervical dystonia and occipital neuralgia in Tourette's syndrome can severely affect well-being. Although there are treatments for occipital neuralgia, there is variability in their efficacy.<sup>5,6</sup> Currently, there are no treatment consensus guidelines for occipital neuralgia.<sup>5</sup>

Pharmacologic treatment, which includes tricyclic antidepressants, anticonvulsants, opioids, and non-steroidal anti-inflammatory agents, is first line. In refractory cases, minimally invasive procedures, such as nerve blocks, epidural blocks, and botulinum injections, are considered followed by more aggressive surgery, which includes rhizotomy, gangliotomy, root decompression, and neurectomy. Despite these interventions, there is a lack of evidence indicating success.<sup>5</sup>

A few recent cases showed the success of peripheral nerve stimulation (PNS).<sup>7</sup>

Occipital PNS is a neuromodulation technique involving use of electrodes in the C1-2 region of the posterior cervical spine, stimulating the A-beta fibers to prevent nociceptive input and signaling to the cortex.<sup>7</sup> Regarding management of intractable headaches such as occipital neuralgia, some studies have shown effective pain relief.<sup>8,9</sup> PNS is preferable because it is adjustable, minimally invasive, and reversible unlike invasive surgeries. If successful, occipital PNS can effectively provide long-term relief for chronic occipital neuralgia.

Neuromodulation has potential for treatment-refractory occipital neuralgia, especially in cases involving Tourette's-related cervical dystonia. Current literature has not documented a case involving peripheral nerve stimulation in refractory occipital neuralgia secondary to Tourette's cervical dystonia. Our case may be the first to demonstrate how effective occipital nerve stimulation is for Tourette's Syndrome Cervical Dystonia Induced Occipital Neuralgia, an uncommon manifestation.

## Case Description

A 34-year-old male with poorly-controlled Tourette's cervical dystonia presents with progressively worsening occipital neuralgia. He described his pain as bilateral, severe, sharp, stabbing, and localized at the skull base, worse with touch. Various interventions were trialed with temporary and minimal relief. Prior medications included propranolol, gabapentin, hydrocodone-acetaminophen, and amitriptyline, which were prescribed at standard initial doses in alignment with conventional clinical protocols for headache management. Specifically, the treatment regimen began with propranolol at an initial dose of 40 mg daily, administered at two divided doses of 20 mg each. Gabapentin was started at 300 mg daily in the evening. Concurrently, the patient was prescribed hydrocodone 5 mg/acetaminophen 325 mg every 4 to 6 hours as needed for pain. Additionally, amitriptyline was initiated at a nightly dose of 25 mg at bedtime. These dosages represent the typical starting points in clinical practice, with the intention of gradual titration based on patient response, tolerability, and efficacy. It is pertinent to note that the patient's treatment journey, as detailed in our case report, involved discontinuation of these medications due to adverse effects or lack of effectiveness prior to any substantial dosage modification. This early cessation precluded further dose adjustments that might have been considered under different circumstances.

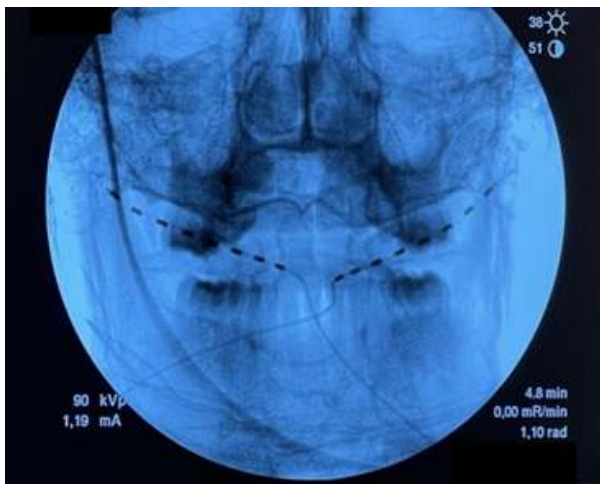
Additionally, the patient had undergone bilateral third occipital nerve rhizotomy, cervical epidural injections,



botulinum injections, and multiple occipital nerve blocks. He had physical therapy and chiropractic treatment sessions. He also had bilateral C2 and third occipital nerve blocks, which were minimally effective, but distal nerve blocks at the occipital protuberance provided the most analgesia, approximately 85% pain relief. Therefore, a PNS trial was completed at the level of the occipital protuberance, and a peripheral nerve stimulator was implanted after a successful trial.

The patient was positioned prone on the operating table. Routine monitors were present, and pressure points were padded. The surgical site was prepped and draped in sterile fashion. A fluoroscopy machine was used to obtain appropriate views of the cervical and thoracic spine.

The occipital ridge was identified, and the overlying skin was anesthetized with lidocaine 1% local injection. At C1, a 14-gauge Coudé needle was inserted, and serial fluoroscopic views were done to access the subcutaneous space (Figure 1). A NALU (Carlsbad, CA) octrode array lead was inserted, and under continuous fluoroscopy, it was positioned with the top contact at the left lateral edge of the occipital ridge. The lead was placed along the superior nuchal line because the patient had relief from nerve blocks placed in this area as opposed to a more proximal location. Real-time testing, both sensory and motor, confirmed adequate placement. The procedure was repeated on the right side. The patient received one stimulator with two leads on each side at the end of the procedure.



**Figure 1.** Occipital peripheral nerve stimulator lead placement.

During lead placement, the patient did not report any paresthesia. The peripheral nerve stimulator lead was then connected to the stimulator via temporary wire. Utilizing direct interaction with the patient and fluoroscopic guidance, the lead positioning was modified

until an optimal stimulation pattern was obtained. The patient confirmed the paresthesia coverage was in the region of his usual pain pattern. Once adequate stimulator coverage was obtained, the introducer needle and stimulator guidewire were removed. Stable lead positioning was fluoroscopically confirmed. The lead was secured with StayFix dressing. Stable positioning of the stimulator lead was again fluoroscopically confirmed. Standard surgical dressings were applied.

Following the procedure, the patient was in stable condition with no postoperative complications. On four-week follow up, he reported significant pain relief, approximately 90%, and he stated that his pain was almost resolved. Although both the trial and device were implanted, permanent implantation of the nerve stimulator was delayed due to lack of insurance coverage. Currently, the patient is looking for more financially viable options to have the occipital PNS permanently placed.

## Discussion

Tourette's syndrome was thought to be a rare pediatric disorder. However, it is more common than originally thought with studies estimating that 1 out of every 162 children have Tourette's.<sup>10</sup> Despite increased prevalence, Tourette's-induced cervical dystonia is uncommon, with refractory occipital neuralgia even rarer. Our patient suffered from chronic, treatment-resistant occipital neuralgia secondary to Tourette's-related cervical dystonia.

Literature and consensus guidelines are lacking in pain management of refractory occipital neuralgia secondary to Tourette's cervical dystonia.

Treatment of occipital neuralgia should be initially conservative to avoid severe complications associated with invasive procedures. Although rhizotomy, neurectomy, angliotomy, and ganglionectomy are used in treatment-resistant cases, these surgeries pose increased risks of neuroma, failure of symptom resolution, deafferentation syndrome, complex regional pain syndrome, neurological deficits such as hemiplegia, infection, and other symptoms such as nausea and dizziness postoperatively.<sup>5, 11, 12</sup> For the aforementioned reasons, surgery is the last option.

Peripheral nerve stimulation is an excellent alternative for treatment-resistant cases by providing effective analgesia while avoiding extensive risks associated with invasive surgeries.<sup>13,14</sup> The theory behind PNS is stimulation of A-beta fibers, inhibiting nociceptive input and C-fibers from signaling the cortex.<sup>6</sup> By continuously stimulating A-beta fibers, pain signals are blocked at the level of the spinal cord and medulla.<sup>14</sup>



As technology advances, peripheral nerve stimulation has the potential for various indications including occipital neuralgia. Additionally, current literature reports positive outcomes with occipital nerve stimulation.<sup>14,15</sup> PNS is less invasive and safer compared to other procedures for occipital neuralgia. It is also easy to implant and adjustable.<sup>14</sup> Because of its ease of removal, the procedure is entirely reversible.

In our case, occipital PNS was successful, with significant analgesia and no postoperative complications for our patient. His quality of life significantly improved postoperatively.

Common interventions such as nerve blocks, medications, physical therapy, and surgery may be ineffective for Tourette's-induced occipital neuralgia, especially in refractory cases. Therefore, we strongly recommend considering occipital nerve stimulation for Tourette's-related cervical dystonia and subsequent refractory occipital neuralgia. Future studies should elucidate the benefits and efficacy of occipital PNS, such as short-term and long-term pain relief, device sustainability (especially with frequent head movement), adverse events, and clinical indications, because the literature is either limited or does not include large cohorts. Literature is especially lacking in PNS use in Tourette's-induced occipital neuralgia refractory cases. Pain providers should be well-informed in peripheral nerve stimulation and understand its benefits for refractory occipital neuralgia, particularly with concurrent Tourette's cervical dystonia. Provider education can help better understand PNS indications for occipital neuralgia and Tourette's cervical dystonia. Quality of life should be the goal, and with Tourette's-related dystonia and occipital neuralgia, it is even more imperative to remedy debilitating symptoms and improve wellbeing. However, equally important is provider education of procedure-related complications. Complications related to PNS implantation include lead or electrode migration, wrongful placement, nerve injury, infection, hardware erosion, and loss of effect.<sup>14,15</sup>

Research should focus on preventative measures, nerve stimulator implantation techniques, and stimulator technology to prevent complications.

**Founded:** There are no financial disclosures.

**Conflicts of Interest:** There are no conflicts of interest to disclose.

**Authors Contributions:**

CJ, AP, Draff, and revise the manuscript, approve the version submitted, and agree to be accountable for all sections of the work; CJ, AP, AC, JG, HK, Draff, and revise the manuscript thoroughly, approve the version submitted, and agree to be accountable for all parts of the work.

## References

1. Jankovic J and Kurlan R. **Tourette syndrome: Evolving concepts.** *Movement Disorders* 2011;26(6):1149-1156 Doi: 10.1002/mds.23618
2. Stone LA and Jankovic J. **The Coexistence of Tics and Dystonia.** *Archives of Neurology* 1991;48(8):862-865 Doi: 10.1001/archneur.1991.00530200104028
3. Pringsheim T, Freeman R and Lang A. **Tourette syndrome and dystonia.** *Journal of Neurology, Neurosurgery & Psychiatry* 2006;78(5):544-544 Doi: 10.1136/jnnp.2006.0102442
4. **Headache Classification Committee of the International Headache Society (IHS) The International Classification of Headache Disorders, 3rd edition.** *Cephalalgia* 2018;38(1):1-211 Doi: 10.1177/0333102417738202
5. Choi I and Jeon SR. **Neuralgias of the Head: Occipital Neuralgia.** *Journal of Korean Medical Science* 2016;31(4):Doi: 10.3346/jkms.2016.31.4.479
6. Finiels PJ and Batifol D. **The treatment of occipital neuralgia: Review of 111 cases.** *Neurochirurgie* 2016;62(5):233-240 Doi: 10.1016/j.neuchi.2016.04.004
7. Harsh V, Mishra P, Gond PK and Kumar A. **Peripheral nerve stimulation: black, white and shades of grey.** *British Journal of Neurosurgery* 2019;33(3):332-336 Doi: 10.1080/02688697.2018.1538479
8. Weiner RL and Reed KL. **Peripheral Neurostimulation for Control of Intractable Occipital Neuralgia.** *Neuromodulation: Technology at the Neural Interface* 1999;2(3):217-221 Doi: 10.1046/j.1525-1403.1999.00217.x
9. Oh MY, Ortega J, Bellotte JB, Whiting DM and Aló K. **Peripheral Nerve Stimulation for the Treatment of Occipital Neuralgia and Transformed Migraine Using a C1-2-3 Subcutaneous Paddle Style Electrode: A Technical Report.** *Neuromodulation: Technology at the Neural Interface* 2004;7(2):103-112 Doi: 10.1111/j.1094-7159.2004.04014.x
10. Knight T, Steeves T, Day L, Lowerison M, Jette N and Pringsheim T. **Prevalence of Tic Disorders: A Systematic Review and Meta-Analysis.** *Pediatric Neurology* 2012;47(2):77-90 Doi: 10.1016/j.pediatrneurol.2012.05.002
11. Ducic I, Felder JM, Khan N and Youn S. **Greater Occipital Nerve Excision for Occipital Neuralgia Refractory to Nerve Decompression.** *Annals of Plastic Surgery* 2014;72(2):184-187 Doi: 10.1097/SAP.0b013e3182898736



12. Jose A, Nagori SA, Chattopadhyay PK and Roychoudhury A. **Greater Occipital Nerve Decompression for Occipital Neuralgia.** *Journal of Craniofacial Surgery* 2018;29(5):e518-e521 Doi: 10.1097/scs.0000000000004549
13. Salmasi V, Olatoye OO, Terkawi AS, Hah JM, Ottestad E and Pingree M. **Peripheral Nerve Stimulation for Occipital Neuralgia.** *Pain Medicine* 2020;21(Supplement\_1):S13-S17 Doi: 10.1093/pm/pnaa083
14. Urits I, Schwartz RH, Patel P, Zeien J, Connor D, Hasoon J, . . . Viswanath O. **A Review of the Recent Findings in Minimally Invasive Treatment Options for the Management of Occipital Neuralgia.** *Neurology and Therapy* 2020;9(2):229-241 Doi: 10.1007/s40120-020-00197-1
15. Keifer OP, Diaz A, Campbell M, Bezchlibnyk YB and Boulis NM. **Occipital Nerve Stimulation for the Treatment of Refractory Occipital Neuralgia: A Case Series.** *World Neurosurgery* 2017;105:599-604 Doi: 10.1016/j.wneu.2017.06.064