▪ Headache Medicine 2023, 14(1):65-68 ▪ p-ISSN 2178-7468, e-ISSN 2763-6178

Headache Medicine

▪ DOI: 10.48208/HeadacheMed.2023.13

Short communication

Presence of mast cells in the rat pericranium – a tissue very sensitive to pain

Rita Santana dos Reis[1], Regina Lúcia Gomes Botter[1], Maria Rosana de Souza Ferreira[1], Sandra Lopes de Souza[1], Juliana Ramos de Andrade[1], Sarah Louise Tangsgaard Christensen[2], Marcelo Moraes Valença[1]

[1]Universidade Federal de Pernambuco, Recife, Brazil.
[2]Danish Headache Center, Copenhagen University Hospital - Rigshospitalet, Copenhagen, Denmark.

Rita Santana dos Reis
rita.santanareis@hotmail.com

Edited by:
Mario Fernando Prieto Peres

Abstract

Objective
To evaluate mast cell presence in the pericranium of Wistar rats.

Methods
Five male rats of the Wistar strain were used. The animals were housed under a 12 h light cycle with *ad libitum* access to food and water and allowed 10 days of acclimatization before tissue sampling.

The five rats were anesthetized by intraperitoneal injection of ketamine/xylazine, 10/20 mg/kg. Following aseptic preparation of the head skin, a midline longitudinal incision was made to expose the pericranium. Two samples of the pericranium were taken, one from the right and one from the left. These samples were fixed in 10% buffered formaldehyde for 24 h. After fixation, tissue samples were paraffin-embedded and sectioned at 4 μm. Then, slides were deparaffinized, stained with a concentration of 0.1% toluidine blue for 1 min, and washed with distilled water. Last, slides were photomicrographed under 400x magnification to identify mast cells.

Results
Mast cells were identified in the dura mater and the five rats' pericranium. In the dura mater, mast cells were also found in these rats. We found both granulated (intact) and degranulated mast cells.

Conclusion
We suggest that future preclinical studies investigating the involvement of dural mast cells and other meningeal cell populations should also include pericranium samples to explore this structure's relevance in migraine pain and other headache disorders.

Keywords:
Mast cells
Pericranium
Rats
Dura mater

Submitted: March 16, 2023
Accepted: March 20, 2023
Published online: March 31, 2023

© Copyright 2023

Introduction

The periosteum is a membrane surrounding the external surface of the bones. The periosteum is a pain sensitive structure innervated by nociceptor containing sensory neurons. As a result, any injury is perceived as painful.[1]

The periosteum consists of an outer fibrous layer of dense connective tissue with fibroblasts and an inner cambium layer (also called osteogenic layer), which is highly populated byprogenitor cells from which the osteoblast developed.[1,2]

The periosteum that covers the external surface of the skull bones (notably the frontal and parietal bones) is termed the pericranium. Along with the dura mater, the pericranium is one of the head structures most sensitive to painful stimuli.[3,4] Blood supply to the skull bones pass through the pericranium. Both sympathetic and fibers immunoreactive for VIP and CGRP[1,2] have been identified in the periosteum and seem to play a regulatory role in osteogenesis and protection against possible tissue damage by mechanisms of nociceptive regulation.[2] The sympathetic nervous system regulates bone remodeling by controlling bone formation and resorption.[1]

A very similar arrangement is seen in the dura mater, which covers the inner surface of the frontal and parietal bones. The dura mater is a highly studied structure in migraine as a site with localization of several structures suggested to be involved in migraine. Mast cells, known as pro-inflammatory effector cells, are immunocytes present in the dura mater and may be involved in the pathophysiology of migraine.[5-7] Several studies have looked at the involvement of dura mater mast cells as a co-factor in the generation of migraine pain, particularly regarding the hypothesis of neurogenic inflammation.[8-10] Little is known about mast cells in the pericranium.

Objective

To evaluate mast cell presence in the pericranium of Wistar rats.

Methods

Five male rats of the Wistar strain were obtained from the Department of Antibiotics - Danti of the Federal University of Pernambuco - UFPE and used with authorized use by the Ethics Committee on Animal Use - CEUA of UFPE (protocol No. 0084/2019). The animals were housed under a 12 h light cycle with *ad libitum* access to food and water and allowed 10 days of acclimatization before tissue sampling.

The five rats were anesthetized by intraperitoneal injection of ketamine/xylazine, 10/20 mg/kg. Following aseptic preparation of the head skin, a midline longitudinal incision was made to expose the pericranium. Two samples of the pericranium were taken, one on the right side and one on the left side. These samples were fixed in 10% buffered formaldehyde for 24h. After fixation, tissue samples were paraffin embedded and sectioned at 4μm. Then, slides were deparaffinized, stained with concentration 0.1% toluidine blue for 1 min, and washed with distilled water. Last, slides were photomicrographed under 400x magnification to identify mast cells.

Results

Mast cells were identified in the dura mater and in the pericranium of all five rats (Figure 1). We found both granulated (intact) and degranulated mast cells.

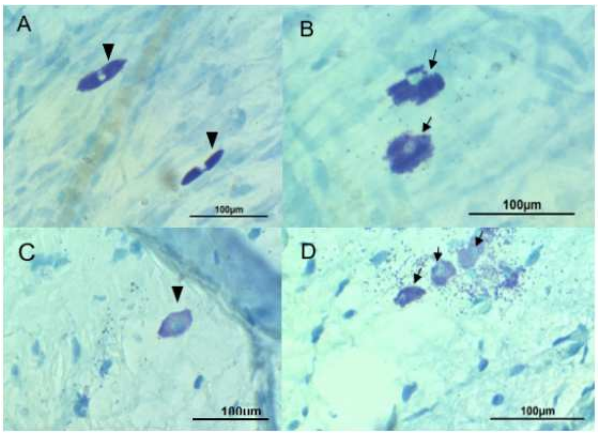

Figure 1. Photomicrographs at 400X magnification. A- granulated mast cells (black arrowhead) in the dura mater; B- Degranulated mast cells (black arrow) in the dura mater; C- Granulated mast cells (black arrowhead) in the pericranium; D- Degranulated mast cells (black arrow) in the pericranium.

Discussion

This study clearly demonstrated that mast cells are present in the pericranium of adult rats. The role of these needs to be further investigated as we have yet to find literature on the presence and function of mast cells in the pericranium. We speculate that the pericranium may have a function

similar to the dura mater in the pathophysiology of migraine and other headaches. This hypothesis is based on the anatomical similarities between the two structures. The pericranium not only has mast cells as the dura mater. The tissue is also innervated by both blood vessels and nerves of sensory and autonomic origin. The observation during surgical procedures that the pericranium is very pain sensitive adds to the relevance of the proposed notion.

In several tissues, mast cells are found close to nerve endings of primary afferent neurons involved in nociception to signal pain.[9,11] Upon activation, mast cells release granules containing substances that induce inflammation and may activate nociceptors.[9] These events are central in the hypothesis of sterile neurogenic inflammation as part of complex pathophysiology on migraine. Mast cells may degranulate in response to various events, including chemical activation by pituitary adenylate cyclase activating peptide 38 (PACAP38) which may play a causative role in migraine when released into the trigeminovascular system.

Recently, we described the histomorphometric aspects of mast cells located in the convexity of the human dura mater.[8] We observed that the mast cells are located close to blood vessels, with a more significant number of cells next to the venous vessels of the periosteal layer and in the proximal region of the superior sagittal sinus.[8] Different from rat (with two), three distinctive dural layers (periosteal, meningeal, and dural border cell layers) are identified in the human dura mater, with a thickness of 564 ± 50 μm.[12] The cells are slightly erratically oriented in the periosteal and meningeal layers. The meningeal layer contained more fibroblasts per unit area than the periosteal layer.[12] The dural border cell layer is visible and has 3-8 cells thickness. Large blood vessels are allocated primarily in the periosteal layer, whereas small blood vessels (maximum diameter, 42 μm) are present within the border between the meningeal and dural border cell layers.[12]

Dimitriadou and collaborators[13] have described the phenotype of mast cells in rat dura mater and their topological and functional relationships with C-fibers in normal and inflammatory conditions. Using confocal microscopy, the mast cells were observed in close apposition (distance <100 nm) to calcitonin gene-related peptide- and substance P-immunoreactive nerve fibers in both controls and animals infected with the nematode Nippostrongylus brasiliensis. This suggests a possible role in the genesis of headache disorders since there is a vascular reactivity linked to migraine attack.

Kinaci and coworkers examined the interaction between mast cells and the dura mater catecholaminergic nerve fibers. As a result of chemical sympathectomy or surgical removal of the right superior cervical ganglion, a rapid decrease of fluorescence in both nerve fibers and mast cells (nerve fibers 19 ± 1.1 *versus* 1.3 ± 0.6; mast cell 10.8 ± 1.9 *versus* 2.1 ± 0.3) was observed. On the other hand, after electrical nerve fiber stimulation, the fluorescence increased in both the nerve fibers and the mast cells (nerve fibers 43.4 ± 2.4; mast cells 18.6 ± 1.6).[14]

Conclusion

We suggest that future preclinical studies investigating the involvement of dural mast cells and other meningeal cell populations should also include samples of the pericranium to explore the relevance of this structure in migraine pain and other headache disorders.

Conflict of Interest

The authors have no competing interests to declare.

Funding

This work was supported by Conselho Nacional de Desenvolvimento Científico e Tecnológico –CNPq and Keizo Asami Institute resources.

Authors' contributions

RSR, MMV and SLSC concept and interpretation of data for the study; RLGB, MRSF, collected the data; SLTC and JRA, refinement of the manuscript. All authors approved the final version of the manuscript.

Rita Santana dos Reis
https://orcid.org/0000-0002-9868-2411
Regina Lúcia Gomes Botter
https://orcid.org/0000-0002-1827-4443
Maria Rosana de Souza Ferreira
https://orcid.org/0000-0003-1166-5342
Sandra Lopes de Souza
https://orcid.org/0000-0003-4562-6042
Juliana Ramos de Andrade
https://orcid.org/0000-0002-5445-8872
Sarah Louise Tangsgaard Christensen
https://orcid.org/0000-0002-7985-4783
Marcelo Moraes Valença
https://orcid.org/0000-0003-0678-3782

References

1. Mauprivez C, Bataille C, Baroukh B, Llorens A, Lesieur J, Marie PJ, . . . Cherruau M. **Periosteum Metabolism and Nerve Fiber Positioning Depend on Interactions between Osteoblasts and Peripheral Innervation in**

Rat Mandible. *PLoS One* 2015;10(10):e0140848 Doi: 10.1371/journal.pone.0140848

2. Hassan B, Fouilloux I, Baroukh B, Llorens A, Biosse Duplan M, Gosset M, . . . Saffar JL. **Coordination of early cellular reactions during activation of bone resorption in the rat mandible periosteum: An immunohistochemical study.** *Heliyon* 2017;3(10):e00430 Doi: 10.1016/j.heliyon.2017.e00430
3. Castien R, Duineveld M, Maaskant J, De Hertogh W and Scholten-Peeters G. **Pericranial Total Tenderness Score in Patients with Tension-type Headache and Migraine**. **A Systematic Review and Meta-analysis.** *Pain Physician* 2021;24(8):E1177-E1189
4. Aaseth K, Grande RB, Lundqvist C and Russell MB. **Pericranial tenderness in chronic tension-type headache: the Akershus population-based study of chronic headache**. *The Journal of Headache and Pain* 2014;15(1):Doi: 10.1186/1129-2377-15-58
5. Jansen-Olesen I and Hougaard Pedersen S. **PACAP and its receptors in cranial arteries and mast cells.** *The Journal of Headache and Pain* 2018;19(1):Doi: 10.1186/s10194-017-0822-2
6. Conti P, D'Ovidio C, Conti C, Gallenga CE, Lauritano D, Caraffa A, . . . Ronconi G. **Progression in migraine: Role of mast cells and pro-inflammatory and anti-inflammatory cytokines.** *European Journal of Pharmacology* 2019;844(87-94 Doi: 10.1016/j.ejphar.2018.12.004
7. Levy D. **Migraine pain, meningeal inflammation, and mast cells.** *Curr Pain Headache Rep* 2009;13(3):237-240 Doi: 10.1007/s11916-009-0040-y
8. Rosas EP, Paz ST, Costa RF, da Silva AA, da Silva RL, da Silva APF, . . . Valenca MM. **Histomorphometry of mast cells in the convexity of human intracranial dura mater.** *J Anat* 2022;240(4):724-734 Doi: 10.1111/joa.13585
9. Levy D, Kainz V, Burstein R and Strassman AM. **Mast cell degranulation distinctly activates trigemino-cervical and lumbosacral pain pathways and elicits widespread tactile pain hypersensitivity.** *Brain Behav Immun* 2012;26(2):311-317 Doi: 10.1016/j.bbi.2011.09.016
10. Balcziak LK and Russo AF. **Dural Immune Cells, CGRP, and Migraine.** *Front Neurol* 2022;13(874193 Doi: 10.3389/fneur.2022.874193
11. Barbara G, Wang B, Stanghellini V, de Giorgio R, Cremon C, Di Nardo G, . . . Corinaldesi R. **Mast cell-dependent excitation of visceral-nociceptive sensory neurons in irritable bowel syndrome.** *Gastroenterology* 2007;132(1):26-37 Doi: 10.1053/j.gastro.2006.11.039
12. Kinaci A, Bergmann W, Bleys RL, van der Zwan A and van Doormaal TP. **Histologic Comparison of the Dura Mater among Species.** *Comp Med* 2020;70(2):170-175 Doi: 10.30802/AALAS-CM-19-000022
13. Dimitriadou V, Rouleau A, Trung Tuong MD, Newlands GJ, Miller HR, Luffau G, . . . Garbarg M. **Functional relationships between sensory nerve fibers and mast cells of dura mater in normal and inflammatory conditions.** *Neuroscience* 1997;77(3):829-839 Doi: 10.1016/s0306-4522(96)00488-5
14. Artico M, De Santis S and Cavallotti C. **Cerebral dura mater and cephalalgia: relationships between mast cells and catecholaminergic nerve fibers in the rat.** *Cephalalgia* 1998;18(4):183-191 Doi: 10.1046/j.1468-2982.1998.1804183.x