



Pain as an alarm signal in cervical carotid dissection: report of a case with catastrophic evolution

Marcelo Moraes Valença¹ , Martina Falcão Valença² , Marcelo Andrade Valença¹ , Laécio Batista Leitão¹ 
Luciana Patrícia Alves de Andrade Valença¹ , Raimundo Pereira Silva-Néto³ 

¹Federal University of Pernambuco, Recife, Pernambuco, Brazil

²Städtisches Klinikum Dresden, Dresden, Germany

³Federal University of the Parnaíba Delta, Parnaíba, Piauí, Brazil



Marcelo Moraes Valença
mmvalenca@yahoo.com.br

Edited by:

Juliana Ramos de Andrade

Keywords:

Arterial dissection
Carotid artery
Stroke

Abstract

Background

Cervical carotid dissection is a commonly reported arteriopathy and is associated with stroke in young, healthy patients.

Case report

The authors present a case of a woman with pain of recent onset secondary to a dissection of the cervical segment of the carotid artery on the same side and that evolved with stroke.

Conclusion

The diagnosis of arterial dissection is based on clinical suspicion and angiographic images of the encephalic vessels.

Submitted: November 8, 2022

Accepted: December 10, 2022

Published: December 29, 2022



Introduction

Cervical carotid dissection is a commonly reported arteriopathy and is associated with stroke in young, healthy patients.¹ Cases of patients who seek a medical emergency with recent and lateralized pain in the head and neck segment are not rare, and their symptoms are not thoroughly evaluated.^{2,5} The authors present a case of a woman with pain of recent onset secondary to a dissection of the cervical segment of the carotid artery on the same side. Although she sought an emergency and being evaluated by neuroimaging, the diagnosis was not suspected. As a result, there was a dramatic evolution with a stroke in the territory of the middle cerebral artery due to thromboembolism.

Case Report

A 48-year-old woman with a medical history of neck pain radiating to the occipital region on the right side for two weeks was admitted to the Hospital Esperança, Recife, Brazil. It was a continuous, non-pulsating pain of mild to moderate intensity. The pain came after going to the hairdresser, where she stayed for more than 60 minutes with her neck hyperextended. She sought a hospital emergency one week after the onset of the pain, performed a computed tomography scan of the skull, which was considered normal, and was discharged. Eight hours before the present admission (two weeks after the beginning of the pain), she presented a sudden severe motor deficit of the left limbs and paralysis of the left hemiface.

The medical management was initially conservative. A head computed tomography scan showed slight edema in the right cerebral parenchyma without deviation of the midline structures (Figure 1A). Twenty-four hours later, the patient became drowsy, and a new CT scan of the skull showed considerable edema (hypodensity) in the right cerebral hemisphere involving the middle cerebral artery territory, now with a significant deviation of the structures located in the midline (Figure 1B).

Angiography of the encephalic vessels was also performed, showing a dissection of the right carotid artery and occlusion of the right middle cerebral artery in the M1 segment (Figure 1C). A decompressive craniectomy was indicated, which was performed immediately. There was an improvement in the level of consciousness, and the patient was discharged three weeks later with left hemiplegia but lucid and oriented.

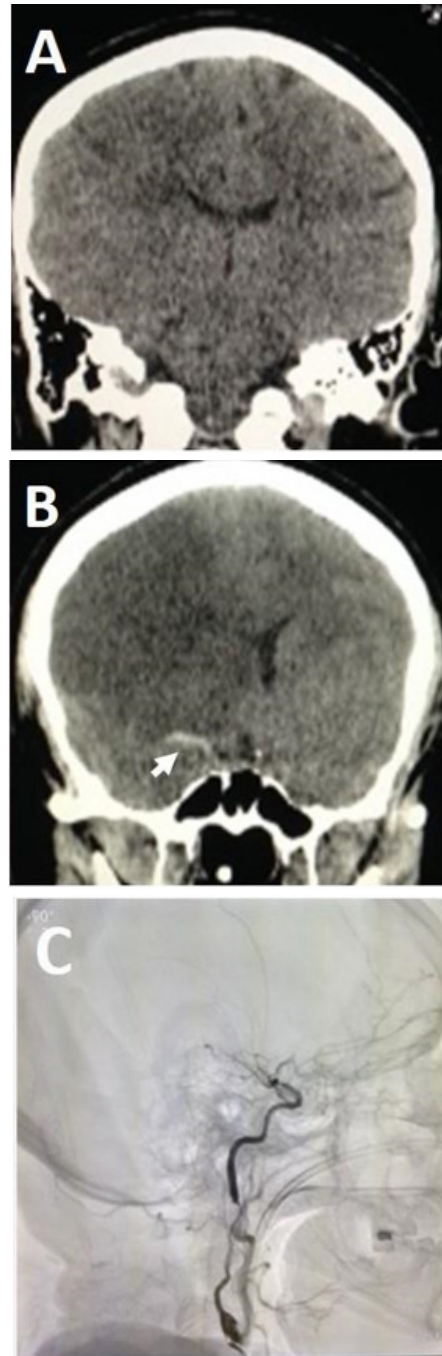


Figure 1. A. A head computed tomography scan showed slight edema in the right cerebral parenchyma without deviation of the midline structures. B. Twenty-four hours later, the patient became drowsy, and a new CT scan of the skull showed considerable edema (hypodensity) in the right cerebral hemisphere involving the middle cerebral artery (MCA) territory. See the hyperdense MCA sign or Gács sign, representing thromboembolic material within the arterial lumen (arrow). C. Arteriography of the neck and head vessels showing a dissection of the right carotid artery and occlusion of the right middle cerebral artery in the M1 segment.



Comments

Unilateral neck pain is a warning sign the emergency physician should value; often benign, but it may represent a sign of cervical arterial dissection. Sometimes, unilateral neck may be accompanied by oculosympathetic palsy, amaurosis fugax, and symptoms of focal brain ischemia.⁶ An antiplatelet or anticoagulant drug should be used chronically in diagnosing the dissection.⁷⁻¹² However, there are risks of extending the dissection through the vessel wall, or even an increased risk of systemic bleeding.¹ There is a renewal of the arterial endothelium every three years. We must understand that the arterial wall is a living tissue, with apoptosis and the emergence of new cells, with permanent cell renewal, which allows tissue repair, if necessary. Surgical interventions can also be performed.^{8,11}

Cases of carotid arterial dissection have been misdiagnosed with different headache types, in particular with cluster headache.^{2,13-25} The detection of Horner syndrome in a patient with a new-onset headache may help promptly diagnose a cervical arterial dissection.^{6,26,27} A case of a patient with traumatic internal carotid artery dissection with a clinical picture mimicking hemicrania continua was reported, and this painful entity responded to indomethacin.¹⁴

A case of a man who presented to the emergency department with a 2-week persistent headache was recently reported.² He complained of tension-type headaches for several years. However, he had no history of diagnosed migraines until he was seen four days prior for empiric migraine therapy in the same emergency department and left without improvement in symptoms.² On his second visit, a visual deficit in the left upper quadrant was detected. On his return visit, a computerized tomography scan with intravenous contrast revealed a left vertebral artery dissection, a hematoma, and a small infarction of the right lingual gyrus cortex on magnetic resonance imaging.² The authors emphasized maintaining a wide differential diagnosis and high index of suspicion in the patient with new focal neurologic findings to diagnose a potentially fatal disease.²

Usually, the prognosis of spontaneous carotid dissection is benign, especially when anticoagulant treatment or antiplatelet therapy is given early. As with our patient, some evolve to cerebral infarction with complications, requiring surgical intervention.⁶

Conclusions

The diagnosis of arterial dissection is based on clinical suspicion and angiographic images of the encephalic vessels.

Marcelo Moraes Valença
<https://orcid.org/0000-0003-0678-3782>

Martina Falcão Valença
<https://orcid.org/0000-0002-4085-3118>

Marcelo Andrade Valença
<https://orcid.org/0000-0002-0824-0928>

Laécio Batista Leitão
<https://orcid.org/0000-0001-5081-2689>

Luciana Patrícia Alves de Andrade Valença
<https://orcid.org/0000-0002-3487-0325>

Raimundo Pereira Silva-Néto
<https://orcid.org/0000-0002-2343-9679>

Authors' contribution: All authors had the same contribution.

Funding: No.

Conflict of interests: The authors report no conflict of interest.

Ethical declaration: The patient authorized the publication of her clinical case with neuroimaging results.

References

- Jensen MB, Chacon MR and Aleu A. **Cervicocerebral arterial dissection.** *Neurologist* 2008;14(1):5-6 Doi:10.1097/NRL.0b013e3180d0a380
- Lloyd ML, Billingslea S and Slama R. **Atraumatic vertebral artery dissection in a patient with a migraine headache.** *Mil Med* 2021 Apr 20;usab135 Doi:10.1093/milmed/usab135
- Manabe H, Yonezawa K, Kato T, Toyama K, Haraguchi K, and Ito T. **Incidence of intracranial arterial dissection in non-emergency outpatients complaining of headache: preliminary investigation with MRI/MRA examinations.** *Acta Neurochir Suppl* 2010;107:41-44 Doi:10.1007/978-3-211-99373-6_6
- Maruyama H, Nagoya H, Kato Y, Deguchi I, Fukuoka T, Ohe Y, ... Tanahashi N. **Spontaneous cervicocephalic arterial dissection with headache and neck pain as the only symptom.** *J Headache Pain* 2012;13(3):247-53 Doi:10.1007/s10194-012-0420-2



5. Matsumoto H, Hanayama H, Sakurai Y, Minami H, Masuda A, Tominaga S, ... Hirata Y. **Investigation of the characteristics of headache due to unruptured intracranial vertebral artery dissection.** *Cephalalgia* 2019;39(4):504-514 Doi:10.1177/0333102418791818
6. Anson J and Crowell RM. **Cervicocranial arterial dissection.** *Neurosurgery* 1991;29(1):89-96 Doi:10.1097/00006123-199107000-00015
7. Maderia LM, Hoffman MK and Shlossman PA. **Internal carotid artery dissection as a cause of headache in the second trimester.** *Am J Obstet Gynecol* 2007;196(1):e7-8 Doi:10.1016/j.ajog.2006.09.044
8. Sultan S, Hynes N, Acharya Y, Kavanagh E, and Jordan F. **Systematic review of the effectiveness of carotid surgery and endovascular carotid stenting versus best medical treatment in managing symptomatic acute carotid artery dissection.** *Ann Transl Med* 2021;9(14):1212 Doi:10.21037/atm-20-7279
9. Vineetha VS, Sreedharan SE, Sarma OS and Sylaja PN. **Antiplatelets versus anticoagulants in the treatment of extracranial carotid and vertebral artery dissection.** *Neurol India* 2019;67(4):1056-1059 Doi:10.4103/0028-3886.266290
10. Daou B, Hammer C, Mouchtouris N, Starke RM, Koduri S, Yang S, ... Tjounmakaris S. **Anticoagulation vs antiplatelet treatment in patients with carotid and vertebral artery dissection: A study of 370 patients and literature review.** *Neurosurgery* 2017;80(3):368-379 Doi:10.1093/neuros/nyw086
11. Bajenaru O, Tiu C, Dorobat B and Antochi F. **Why antiplatelet treatment in spontaneous internal carotid dissection?** *J Neural Transm (Vienna)* 2013;120(2):335-338 Doi: 10.1007/s00702-012-0942-4
12. Bontinis V, Antonopoulos CN, Bontinis A, Koutsoumpelis A, Zymvragoudakis V, Rafailidis V, ... Ktenidis K. **A systematic review and meta-analysis of carotid artery stenting for the treatment of cervical carotid artery dissection.** *Eur J Vasc Endovasc Surg* 2022;64(4):299-308 Doi:10.1016/j.ejvs.2022.07.048
13. Aymerich N, Gallego J, Soriano G and Villanueva JA. **Extracranial carotid dissection presenting with cluster headache.** *Rev Neurol* 2000;31(6):594-595
14. Ashkenazi A, Abbas MA, Sharma DK and Silberstein SD. **Hemicrania continua-like headache associated with internal carotid artery dissection may respond to indomethacin.** *Headache* 2007;47(1):127-130 Doi:10.1111/j.1526-4610.2006.00637.x
15. Borelli P, Baldacci F, Nuti A, Lucetti C, Berti C, Logi C, ... Bonuccelli U. **Postpartum headache due to spontaneous cervical artery dissection.** *Headache* 2011; 51(5): 809-813 Doi: 10.1111/j.1526-4610.2011.01881.x
16. Buyle M, Engelborghs S, Kunnen J and De Deyn PP. **Headache as only symptom in multiple cervical artery dissection.** *Headache* 2001;41(5):509-511 Doi:10.1046/j.1526-4610.2001.01090.x
17. Candeloro E, Canavero I, Maurelli M, Cavallini A, Ghiotto N, Vitali P, ... Micieli G. **Carotid dissection mimicking a new attack of cluster headache.** *J Headache Pain* 2013;14(1):84 Doi:10.1186/1129-2377-14-84
18. Chen YC, Ou YH, Chang MC, Chen WL and Lin CM. **Vertebral artery dissection stroke in evolution presented with postural headache as initial manifestation.** *Neurol Int* 2018;10(2):7694 Doi:10.4081/ni.2018.7694
19. Elhfnawy AM, Solymosi L and Sommer C. **Carotid dissection presenting as a prolonged cluster-like headache in a patient with episodic cluster headache.** *BMJ Case Rep* 2017;2017 Doi:10.1136/bcr-2017-220845
20. Frigerio S, Buhler R, Hess CW and Sturzenegger M. **Symptomatic cluster headache in internal carotid artery dissection--consider anhidrosis.** *Headache* 2003;43(8): 896-900 Doi: 10.1046/j.1526-4610.2003.03169.x
21. Godeiro-Junior C, Kuster GW, Felicio AC, Porto PP, Jr., Pieri A and Coelho FM. **Internal carotid artery dissection presenting as cluster headache.** *Arq Neuropsiquiatr* 2008; 66(3B): 763-764 Doi: 10.1590/s0004-282x2008000500034
22. Haraguchi K, Toyama K, Ito T, Hasunuma M and Sakamoto Y. **A case of posterior cerebral artery dissection presenting with migraine-like headache and visual field defect: usefulness of fast imaging employing steady-state acquisition (FIESTA) for diagnosis.** *J Stroke Cerebrovasc Dis* 2012; 21(8): 906e5-7 Doi:10.1016/j.jstrokecerebrovasdis.2011.07.012
23. Hardmeier M, Gobbi C, Buitrago C, Steck A, Lyrer P and Engelter S. **Dissection of the internal carotid artery mimicking episodic cluster headache.** *J Neurol* 2007;254(2):253-254 Doi:10.1007/s00415-006-0337-2
24. Hsu YC and Sung SF. **Spontaneous vertebral artery dissection with thunderclap headache: a case report and review of the literature.** *Acta Neurol Taiwan* 2014;23(1):24-28
25. Mainardi F, Maggioni F, Dainese F, Amista P and Zanchin G. **Spontaneous carotid artery dissection with cluster-like headache.** *Cephalalgia* 2002;22(7):557-559 Doi:10.1046/j.1468-2982.2002.00421.x



26. Creavin ST, Rice CM, Pollentine A and Cowburn P. **Carotid artery dissection presenting with isolated headache and Horner syndrome after minor head injury.** *Am J Emerg Med* 2012;30(9):2103e5-7
Doi:10.1016/j.ajem.2012.03.010
27. Datta S and Candido KD. **Incidental discovery of carotid artery dissection as a cause of horner's syndrome and headache in a patient presenting for follow-up of lumbar epidural steroid injection: a case report with a three year follow-up.** *Pain Physician* 2004;7(4):483-485