




Headache and cranial nerve dysfunction secondary to carotid artery aneurysm: two case reports

Pedro Neves Fortunato², Danilo Takashi Yoshimatsu Ueno², Mariana Suemi Sukessada¹, Gabriel Santaterra Barros¹, João Fernando Cloclét Pio da Silva¹, Bruna Franchito Freire¹, Daniela Alves Gulhote¹, Ana Beatriz Barbosa Piffer¹, Hilton Mariano da Silva Junior¹

¹Faculty of Medicine of Pontifical Catholic University of Campinas - PUC, Campinas, Sao Paulo, Brazil

²Department of Neurology and Neurosurgery of Hospital Municipal Dr. Mário Gatti, Campinas, Sao Paulo, Brazil



João Fernando Cloclét Pio da Silva
johnygrievous@gmail.com

Edited by:

Raimundo Silva-Néto

Keywords:

Aneurysm
Internal carotid artery
Cavernous sinus
Painful ophthalmoplegia

Abstract

The cavernous sinus is a venous plexus located at the base of the skull. Several pathologies, such as inflammatory, aneurysmal, or metastatic processes, can affect this plexus. Cavernous sinus syndrome occurs when the nerves are involved in this region (cranial nerves III, IV, VI, and divisions of V). These anatomical relationships explain that diplopia and pain are these patients' most common onset symptoms. Carotid cavernous aneurysms (CCAs) account for 2% to 9% of aneurysms. We report two patients who showed cavernous sinus syndrome resulting from carotid artery aneurysms. The recognition of the etiology of this distinguished clinical picture is vital to avoid complications and address the best approach for each patient.

Submitted: December 12, 2022.
Accept: December 21, 2022
Published online: December 28, 2022



Introduction

The cavernous sinus is a dural venous plexus lateral to the sella turcica and above the clivus. Inside this plexus pass critical anatomical structures such as the cavernous part of the internal carotid artery, cranial nerves (CN) III, IV, VI, and the ophthalmic and maxillary branches of V, in addition to sympathetic fibers.^{1,2} The Cavernous Sinus Syndrome (CSS) consists of paresis of the motor nerves that run through it, as well as paresthesia of the sensory branches of the trigeminal. The CSS frequently presents with either retroorbital pain or unilateral headaches due to distension of the dural tissue that composes this structure. This condition can have different etiologies: inflammatory, aneurysmal, metastatic, thrombotic, and autoimmune.³ Aneurysms in the cavernous portion of the internal carotid arteries represent only 2% to 9% of all intracranial aneurysms, and from 18% to 34% of the cases are asymptomatic⁴⁻⁶ and an increasing number of such aneurysms are discovered incidentally, usually when evaluating another intracranial aneurysm.

We report two patients with noticeable clinical presentations of CSS and discuss their anatomical relationships and treatment options. Informed consent was obtained from both participants.

Cases presentation

Patient 1

A 73-year-old woman with a previous history of type 2 diabetes mellitus, systemic arterial hypertension, well-controlled asthma, glaucoma, and osteoporosis, started with progressive holocranial headache radiating to the retro-orbital region associated with photophobia. The patient was admitted to the emergency care unit due to the persistence of symptoms seven days later. She received analgesic medication and was discharged with partial relief of pain. After two days, the picture evolved with right palpebral ptosis, worsening visual acuity, and proptosis. On examination, in addition to ptosis, she had right mydriasis (more visible in a bright environment) associated with ipsilateral paresis of III, IV, and VI cranial nerves. The

patient also complained of hypoesthesia in the territory of the right ophthalmic nerve (V1).

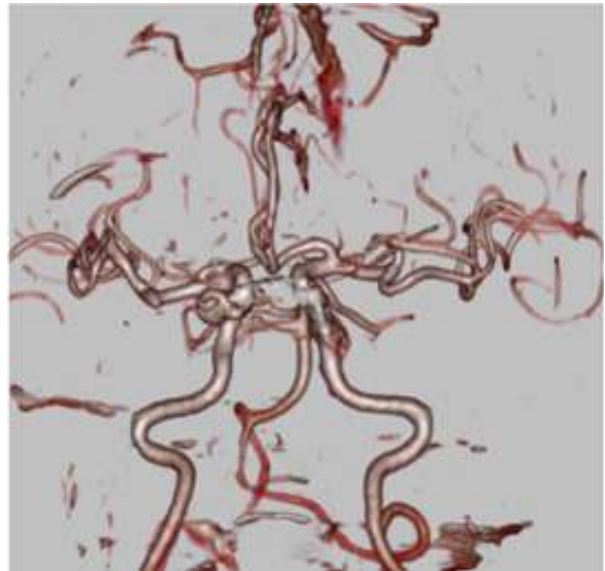


Figure 1. Brain computerized tomography angiography image with 3D reconstruction demonstrating a 93 mm internal carotid aneurysm in the right cavernous sinus.

The brain computerized tomography angiography (CTA) (Figure 1) and magnetic resonance image (MRI) studies disclose a saccular aneurysm in the cavernous portion (C4 segment of Bouthillier classification)⁷ of the right internal carotid artery. The patient was referred to a neurovascular center for further treatment.

Patient 2

A 79-year-old woman came to the emergency room complaining of ocular pain and diplopia for four days. She denies nausea or vomiting, loss of consciousness, or seizures. She reports no relevant morbid antecedents, except glaucoma. On neurological examination, she had a preserved consciousness level, equal pupils, and a right CN VI paresis (Figure 2).



Figure 2. The neurological examination of patient 2 revealed a right abducent palsy.

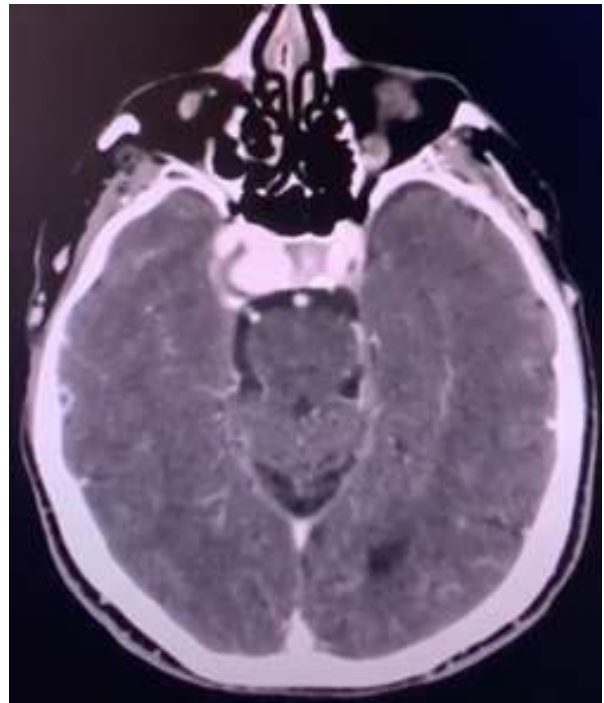


Figure 3. Brain CTA image demonstrating an 11x15x10mm internal carotid aneurysm in the right cavernous sinus.

A brain CTA discloses an aneurysm of the right internal carotid artery's C4 segment (Bouthillier classification)⁷, which insinuates into the ipsilateral cavernous sinus (Figure 3). The patient was referred to a neurovascular center for further treatment.



Discussion

Epidemiology

Cavernous sinus aneurysms are more frequent in white females, with symptoms beginning around the 5th and 6th decades.⁸ Noteworthy, this clear female predominance was also present in other patient series, and there is no known explanation for this.⁵⁻⁹

The exact cause of most cavernous sinus aneurysms is unknown, but a combination of degenerative changes in the tissues could explain them. They may be idiopathic or iatrogenic, and rarely, they can result from trauma or infection.^{10,11} These aneurysms are not as strongly associated with atherosclerosis, smoking, or hypertension as other intracranial aneurysms are.¹¹

Clinical picture

Due to the anatomical relationships of the cavernous sinus, the clinical presentation of compression syndromes in this region is rich in semiological signs. The most common symptoms from these aneurysms result from a mass effect on the adjacent cranial nerves. When headache is present, the conditions described constitute an essential differential diagnosis of Tolosa-Hunt syndrome and diabetic ophthalmoparesis, among other diseases. Stiebel-Kalish et al.⁴ evaluated 206 patients with CSS secondary to the internal carotid aneurysm. The most frequent symptoms at presentation were diplopia (134 cases, 65%) and pain (122 cases, 59%). Pain occurred in various forms and combinations, including retroorbital pain (70 out of 206 cases, 34%) and unilateral headaches (68 out of 206 cases, 33%). In 16.5% of their patients, isolated paresis of CN VI occurred, similar to our patient 1, which highlights the need for investigation with neuroimaging in the face of painful ophthalmoplegia, even in diabetic patients. Among the 35 patients presented with carotid cavernous aneurysm studied by Vasconcellos et al.⁵, headache was the most common symptom (33 patients, 94%), followed by diplopia secondary to a lesion of the VI cranial nerve (82.8%). Sequentially, retrobulbar pain in 18 patients (54.5%), decreased visual acuity in 9 patients (17.8%), photophobia in two cases, and facial pain in one case. The clinical manifestation of subarachnoid hemorrhage is improbable for aneurysms of the CCA since they are usually separated from the brain by the dura of the cavernous sinus.¹² Accordingly, the risk of CCA rupture is low, ranging from 0% in aneurysms smaller than 13 mm to 6.4% in those larger than 25 mm.^{13,14} Some patients have complications of CCA, such as disabling pain, diplopia/

decline in vision, a cavernous carotid fistula resulting from aneurysm rupture, erosion of an aneurysm through the bone into the sphenoid sinus resulting in life-threatening epistaxis, and extension into the subarachnoid space.¹⁵⁻¹⁸ Other possible complications of the CCA include vascular thromboembolism and acute thrombosis, although these were infrequently described. Stiebel-Kalish et al.⁴ even reported two patients (1,5%) who developed thrombotic stroke and another two with embolic cerebral infarction due to thrombosis and embolization of their CCA, but again, these are infrequent events.

Investigation

Evaluation of cavernous aneurysms and other intracranial aneurysms can usually be performed with noninvasive brain CT or MRI angiography. Conventional digital subtraction angiography remains the gold standard for aneurysm detection and anatomic characterization.⁵

Treatment and management

As pointed out by van der Schaaf et al.¹⁹, surgical treatment of CCA is difficult because of the surrounding cavernous sinus. Aneurysms of this location have proven technically challenging for microsurgery owing to the anatomical relationships and morphology, which often include partially thrombosed components and frequently incorporation of the parent internal carotid artery (ICA) in a fusiform or fusi-saccular morphology. As reported by van Rooij et al.⁸, CCA is a rare focus of surgical approach when it comes to intracranial aneurysms, representing less than 3% in their study. That's because most of these aneurysms have a low risk of rupturing and causing subarachnoid hemorrhage, especially when they're considered small (less than 12 mm) and asymptomatic. When identified, these lesions should be followed up with a series of computerized tomography (CT) scans or MRI exams. In 1991, Linskey et al.⁶ reported 43 cavernous sinus aneurysms over 6 1/2 years. Of 23 that fulfilled indications for treatment, 19 were treated (8 surgically and 11 with interventional radiological techniques). The mean follow-up period was 25 months. At follow-up examination, three patients in the surgical group were asymptomatic, two had improved, and three had worsened. Three of these patients had asymptomatic infarctions apparent on CT scans. Four radiologically treated patients were asymptomatic; five had improved, two were unchanged, and none had worsened. One patient had asymptomatic, and one minimally symptomatic infarction was apparent on CT scans; both lesions were embolic foci after aneurysm embolization with preservation of the ICA. The authors concluded that treatment risk depends more on the adequacy



of collateral circulation than on the size of the aneurysm. In accordance, it was pointed out that the efficacy of carotid occlusion to induce thrombosis of the aneurysm is inversely proportional to the degree of existing collateral circulation. Hence, the more proximal the ICA aneurysm, the lower the potential influence of an eventual collateral flow and the greater the expectation of treatment success.²⁰

During the past three decades, the endovascular treatment of cerebral aneurysms has quickly evolved from a nascent technology to a front-line therapy using sophisticated disease and anatomy-specific devices that allow the minimally invasive treatment of even the most complex cerebrovascular lesions. The advent of endovascular therapies has presented alternative strategies in the form of parent vessel occlusion (PVO), coiling with or without stent-assistance, and, more recently, flow diversion (FD). A thorough overview of these currently available endovascular techniques is beyond the scope of this paper and has been reviewed in detail elsewhere.^{3,9}

Van der Schaaf et al.¹⁹ reported a systematic review on balloon occlusion of the parent vessel and embolization with coils to treat CCA. They found 35 studies reporting on 316 patients. Twenty-five studies reported balloon occlusion. Complications during or in the first 24 hours after the balloon occlusion occurred in 4 of 247 patients, and late ischemic complications in 5 of 148 patients. Clinical follow-up was performed in 21 of 25 studies on treatment using balloon occlusion (148 of the 247 patients). None of the 68 patients treated by embolization with coils had a complication. Of 157 aneurysms treated by balloon occlusion, 153 were completely thrombosed. After coiling, 52 of 65 aneurysms were occluded by >90%. The authors concluded that both balloon occlusion and endosaccular coiling are reasonably safe and result in aneurysm occlusion in most patients. Nevertheless, they highlighted the absence of long-term outcomes studies in this field. In a single-institution series, Aguiar et al.²¹ conducted a descriptive, retrospective, and prospective study of patients with aneurysms of the cavernous portion of the ICA or with direct carotid-cavernous fistulas undergoing endovascular treatment. The authors evaluated 26 patients with CCA treated with ICA occlusion. The incidence of retro-orbital pain decreases from 84.6% to 30.8% after treatment. Despite having an ICA occlusion test negative for deficits, one patient evolved with motor deficit contralateral to the occluded side 72 hours after the procedure, the only complication observed in this group. They concluded that the endovascular treatment significantly improved the symptoms in the patients studied, especially those related to pain and oculomotor nerve dysfunction. Another single-center study was reported by Lee et al.²² Fourteen patients with CCA were

treated with FD, and 12 underwent PVO after passing a balloon test occlusion. There was no significant difference between treatment modalities in aneurysmal occlusion, degree of sac regression, or near-complete to complete symptom improvement. Significant complications included subarachnoid hemorrhage from aneurysmal rupture in 1 patient post-FD and two ischemic strokes following PVO.

They conclude that both endovascular techniques are effective and safe. Furthermore, they reported insufficient evidence to recommend one method over the other and that the decision-making should be individualized to the patient, their aneurysm morphology, and operator experience. More recently, Kaiser et al.²³ performed a systematic review and meta-analysis of the flow diversion use for compressive unruptured internal carotid artery aneurysms with neuro-ophthalmological symptoms. The authors reviewed 22 studies reporting on 594 patients. Pooled proportions of neuro-ophthalmological symptoms recovery, improvement, transient and permanent worsening were: 47.4%; 7.4%; 7.1%; and 4.9%, respectively. Rates of complete recovery and improvement in patients with isolated visual symptoms were 30.6% and 56.6%. Morbidity occurred in 5% and mortality in 3.9% of patients. An increased likelihood of symptom improvement was observed when treatment was performed early (<1 month) after symptom onset. In summary, the authors state that FD is an effective and valuable treatment strategy for patients with CCA and neuro-ophthalmological symptoms. Conversely, it is essential to treat patients early after symptom onset and to be aware of the non-negligible morbidity and mortality rate.

Conclusion

We emphasize that even in diabetic patients, the investigation using neuroimaging in CSS is essential and can prevent irreversible damage to orbital structures and visual loss due to vascular and other lesions. Adequate and early diagnosis of the internal carotid artery aneurysm in the cavernous portion avoids serious complications, such as irreversible damage to orbital structures and visual loss, and allows a more appropriate therapeutic decision. More observational studies with sufficient patients are paramount to developing evidence-based management guidelines.

Pedro Neves Fortunato

<https://orcid.org/0000-0003-2299-5734>

Danilo Takashi Yoshimatsu Ueno

<https://orcid.org/0000-0002-6585-0108>

Mariana Suemi Sukessada

<https://orcid.org/0000-0003-0015-984X>

Gabriel Santaterra Barros



<https://orcid.org/0000-0001-6831-379X>

João Fernando Cloquet Pio da Silva

<https://orcid.org/0000-0002-7093-2415>

Bruna Franchito Freire

<https://orcid.org/0000-0001-6090-6347>

Daniela Alves Gulhote

<https://orcid.org/0000-0003-2471-9709>

Ana Beatriz Barbosa Piffer

<https://orcid.org/0000-0001-7928-3952>

Hilton Mariano da Silva Junior

<https://orcid.org/0000-0002-9778-9946>

Author contributions: The authors contributed equally in the preparation of the manuscript.

Conflict of interest: There is no conflict of interest.

Funding: The authors received no financial support for the research, authorship, and/or publication of this article

References

1. Lana MA and Barbosa AS. **Síndrome do seio cavernoso: estudo de 70 casos.** *Arq Bras Oftalmol* 1998;61:635-639 Doi:10.5935/0004-2749.19980005
2. Nambiar R and Nair SG. **Cavernous sinus syndrome.** *Proc (Bayl Univ Med Cent)* 2017;30(4):455-456 Doi:10.1080/08998280.2017.11930227
3. Ambekar S, Madhugiri V, Sharma M, Cuellar H and Nanda A. **Evolution of management strategies for cavernous carotid aneurysms: a review.** *World Neurosurg* 2014;82(6):1077-1085 Doi:10.1016/j.wneu.2014.03.042
4. Stiebel-Kalish H, Kalish Y, Bar-On RH, Setton A, Niimi Y, Berenstein A and Kupersmith MJ. **Presentation, natural history, and management of carotid cavernous aneurysms.** *Neurosurgery* 2005;57(5):850-857; discussion 850-857 Doi:10.1227/01.neu.0000179922.48165.42
5. Vasconcellos LP, Flores JA, Veiga JC, Conti ML and Shiozawa P. **Presentation and treatment of carotid cavernous aneurysms.** *Arq Neuropsiquiatr* 2008;66(2a):189-193 Doi:10.1590/s0004-282x2008000200009
6. Linskey ME, Sekhar LN, Horton JA, Hirsch WL, Jr. and Yonas H. **Aneurysms of the intracavernous carotid artery: a multidisciplinary approach to treatment.** *J Neurosurg* 1991;75(4):525-534 Doi:10.3171/jns.1991.75.4.0525
7. Bouthillier A, van Loveren HR and Keller JT. **Segments of the internal carotid artery: a new classification.** *Neurosurgery* 1996;38(3):425-432; discussion 432-423 Doi:10.1097/00006123-199603000-00001
8. van Rooij WJ. **Endovascular treatment of cavernous sinus aneurysms.** *AJNR Am J Neuroradiol* 2012;33(2):323-326 Doi:10.3174/ajnr.A2759
9. Brown B and Hanel RA. **Endovascular management of cavernous and paraclinoid aneurysms.** *Neurosurg Clin N Am* 2014;25(3):415-424 Doi:10.1016/j.nec.2014.04.017
10. Lam JJH, Shah M, Chung SL and Ho CL. **Persistent primitive trigeminal artery associated with a cavernous carotid aneurysm. Case report and literature review.** *J Radiol Case Rep* 2018;12(11):1-11 Doi:10.3941/jcr.v12i11.3500
11. Neifert SN, Chapman EK, Martini ML, Shuman WH, Schupper AJ, Oermann EK, . . . Macdonald RL. **Aneurysmal Subarachnoid Hemorrhage: the Last Decade.** *Transl Stroke Res* 2021;12(3):428-446 Doi:10.1007/s12975-020-00867-0
12. Wiebers DO, Whisnant JP, Huston J, 3rd, Meisner I, Brown RD, Jr., Piepgras DG, . . . Torner JC. **Unruptured intracranial aneurysms: natural history, clinical outcome, and risks of surgical and endovascular treatment.** *Lancet* 2003;362(9378):103-110 Doi:10.1016/s0140-6736(03)13860-3
13. Hodes JE, Fletcher WA, Goodman DF and Hoyt WF. **Rupture of cavernous carotid artery aneurysm causing subdural hematoma and death. Case report.** *J Neurosurg* 1988;69(4):617-619 Doi:10.3171/jns.1988.69.4.0617
14. Lee AG, Mawad ME and Baskin DS. **Fatal subarachnoid hemorrhage from the rupture of a totally intracavernous carotid artery aneurysm: case report.** *Neurosurgery* 1996;38(3):596-598; discussion 598-599 Doi:10.1097/00006123-199603000-00038
15. Goldenberg-Cohen N, Curry C, Miller NR, Tamargo RJ and Murphy KP. **Long term visual and neurological prognosis in patients with treated and untreated cavernous sinus aneurysms.** *J Neurol Neurosurg Psychiatry* 2004;75(6):863-867 Doi:10.1136/jnnp.2003.020917
16. Ghorbani M, Hejazian SE, Dastmalchi A, Chavoshinejad M and Asaadi S. **Orbital Compartment Syndrome Secondary to Direct Carotid Cavernous Fistula After Carotid Cavernous Aneurysm Rupture: Case Report and Review of Literature.** *World Neurosurg* 2020;133:409-412 Doi:10.1016/j.wneu.2019.08.037
17. Wanke I, Doerfler A, Stolke D and Forsting M. **Carotid cavernous fistula due to a ruptured intracavernous aneurysm of the internal carotid artery: treatment with selective endovascular occlusion of the aneurysm.** *J Neurol Neurosurg Psychiatry* 2001;71(6):784-787 Doi:10.1136/jnnp.71.6.784



18. Arai N, Nakamura A, Tabuse M and Miyazaki H. **Late-Onset Massive Epistaxis due to a Ruptured Traumatic Internal Carotid Artery Aneurysm: A Case Report.** *NMC Case Rep J* 2017;4(1):33-36 Doi:10.2176/nmccrj.cr.2016-0139
19. van der Schaaf IC, Brilstra EH, Buskens E and Rinkel GJ. **Endovascular treatment of aneurysms in the cavernous sinus: a systematic review on balloon occlusion of the parent vessel and embolization with coils.** *Stroke* 2002;33(1):313-318 Doi:10.1161/hs0102.101479
20. Elhammady MS, Wolfe SQ, Farhat H, Ali Aziz-Sultan M and Heros RC. **Carotid artery sacrifice for unclippable and uncoilable aneurysms: endovascular occlusion vs common carotid artery ligation.** *Neurosurgery* 2010;67(5):1431-1436; discussion 1437 Doi:10.1227/NEU.0b013e3181f076ac
21. Aguiar GB, Silva JM, Paiva AL, Jory M, Conti ML and Veiga JC. **Endovascular treatment of carotid-cavernous vascular lesions.** *Rev Col Bras Cir* 2017;44(1):46-53 Doi:10.1590/0100-69912017001007
22. Lee H, Marotta TR, Spears J, Sarma D, Montanera W and Bharatha A. **Endovascular treatment of cavernous carotid artery aneurysms: A 10-year, single-center experience.** *Neuroradiol J* 2021;34(6):568-574 Doi:10.1177/19714009211013487
23. Kaiser DPO, Cuberi A, Linn J and Gawlitza M. **Flow diversion for compressive unruptured internal carotid artery aneurysms with neuro-ophthalmological symptoms: a systematic review and meta-analysis.** *J Neurointerv Surg* 2022;Doi:10.1136/jnis-2022-019249