

Coexistence of SUNCT Syndrome and pituitary tumor: A possible association to be recognized

Coexistência entre Cefaleia do tipo SUNCT e tumor pituitário:
Uma associação que deve ser reconhecida

Julia Vescovi Vieira¹
Amanda dos Santos Cintra¹
Ana Paula Alves Fonseca²
Antônio José da Rocha²
Renan Barros Domingues¹

¹ Department of Neurology, Irmandade Santa Casa de Misericórdia de São Paulo, São Paulo, Brazil.

² Department of Neuroradiology, Irmandade Santa Casa de Misericórdia de São Paulo, São Paulo, Brazil.

A 46-year-old woman reported headache with migraine without aura and SUNCT symptoms. A previous diagnosis of pituitary macroadenoma was confirmed with MR and an increased prolactin. Cabergoline was started with improvement of symptoms. An imaging follow-up showed a reduction of the macroadenoma (Figure 1). Pituitary adenoma is an intracranial tumor that has been reported in about 8% of patients with SUNCT. Dural stretch and hormonal dysfunction are possible mechanisms for this association. The fact that tumor and SUNCT were ipsilateral and that headache improved after cabergoline may suggest an association between these entities, supporting MR investigation when this type of headache is diagnosed.

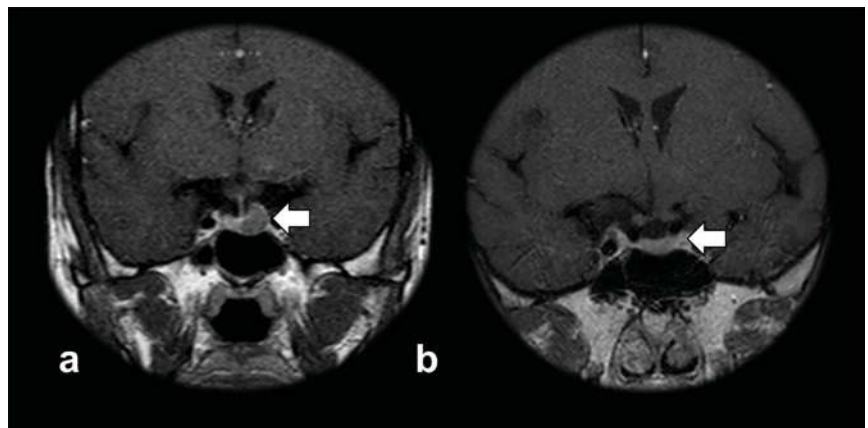


Figure 1. Pituitary MRI, coronal post-gadolinium T1-weighted sequence (a) demonstrate a rounded region of delayed enhancement in the left pituitary compared to the rest of the gland, compatible with adenoma. (b) Imaging follow-up showed a significant reduction of the lesion.

REFERENCES

1. Levy M, Matharu M, Meeran K, Powell M. The clinical characteristics of headache in patients with pituitary tumours. *Brain*. 2005;128(8):1921-30.
2. Chitsantikul P, Becker WJ. SUNCT, SUNA and pituitary tumors: Clinical characteristics and treatment. *Cephalalgia*. 2013;33(3):160-70.
3. Pareja J, Caminero A, Sjaastad O. SUNCT syndrome: diagnosis and treatment. *Headache*. 2003;43(306).

*Correspondence

Julia Vescovi Vieira
E-mail: jvescovivieira@gmail.com

Received: January 31, 2019.
Accepted: February 15, 2019.