



Chronic subdural hematoma that developed after a diagnostic lumbar puncture: headache worsens with bilateral compression of jugular veins (Queckenstedt's maneuver)

Marcelo Moraes Valença¹ , Luiz Severo Bem Junior¹ , Ana Cristina Veiga da Silva¹ ,
Ubiratan Alves Viturino da Silva¹ , Marcelo Andrade Valença¹ ,
Alberto Henrique Torres Trindade da Silva² , Déborah Emmily de Carvalho² ,
Henry Martins Soares Fortes² , Martina Falcão Valença³ , Luciana Patrícia Alves de Andrade-Valença¹ 

¹Federal University of Pernambuco, Recife, Pernambuco, Brazil

²University of Pernambuco, Recife, Pernambuco, Brazil

³International Neuroscience Institute-Hannover, Germany



Marcelo Moraes Valença
mmvalenca@yahoo.com.br

An MRI image of the skull is shown in Figure 1. The image is consistent with the presence of a chronic subdural hematoma on the right. This is a case of a 40-year-old man who, a month earlier, underwent a lumbar puncture with CSF withdrawal to investigate a headache. The CSF was considered normal. After lumbar puncture, he continued to have headaches for days, but with a change in the pattern: it got worse when he sat or walked. The headache continued and became continuous, worsening with Valsalva maneuvers (e.g., coughing, physical exertion). The patient had suffering facies on physical examination and, even lying down, he had severe pain. The pain worsened when the jugular veins were manually compressed by pressure on the neck (Queckenstedt's maneuver). On examination of the fundus of the eye, incipient papilla edema was observed. It was then decided that the patient underwent an urgent magnetic resonance imaging of the skull.

Edited by:

Juliana Ramos Andrade

When the jugular veins undergo bilateral compression in the neck (Queckenstedt's maneuver), there is a reduction in blood volume of cephalic origin that goes to the heart. As a result, there is an increase in the intracranial venous pressure and a consequent increase in intracranial pressure. Increased venous pressure due to compression of the jugular veins increases this already high intracranial pressure with greater severity and, consequently, the headache intensity. High intracranial hypertension is the cause of headache suffering in this patient. There is most likely intracranial hypertension in a patient with an extensive subdural hematoma with a deviation of the midline structures, as is the case of our patient. In a study of 84 patients with a chronic unilateral subdural hematoma, the hematoma volume was 176 ± 48 ml.¹ The mean maximum midline displacement was 12.5 ± 3.7 mm in this group.¹

In terms of historical curiosity, Naffziger described a similar maneuver in examining a patient with sciatic pain, when compression of the jugular veins causes pain or dysesthesia in the affected limb (Naffziger test or sign).

Chronic subdural hematoma is a neurological disease that occurs more frequently in the elderly, mainly with a history of alcoholism (with blood dyscrasia due to liver dysfunction) and the use of anticoagulant/antiplatelet drugs.^{2,3} In this age group, there is encephalic involution with an increase in the subarachnoid space; this explains why there is no headache in many patients with chronic subdural hematoma of this age group, with more frequent cognitive or focal deficits (e.g., motor deficit). Parkinsonism, although rare, has been associated with chronic subdural hematoma.⁴

Submitted: March 26, 2022
Accepted: March 27, 2022

Our patient is a young adult without brain atrophy, and the headache was predominant and severe.

In most cases, there are reports of head trauma, often mild, that occurred 1-3 months before diagnosis. There are reports of chronic subdural hematoma arising after lumbar puncture, diagnosis, or spinal anesthesia.⁵ Generally, before the diagnosis of intracranial hematoma, these

patients presented a clinical picture typical of post-dural puncture headache.⁵⁻⁶ In some patients, the cause is unknown (idiopathic etiology).

Treatment is most often surgical.³ A conservative approach can be adopted, especially in small-volume hematomas.³ Recently, an endovascular procedure with the middle meningeal artery occlusion has been performed.^{2,7}

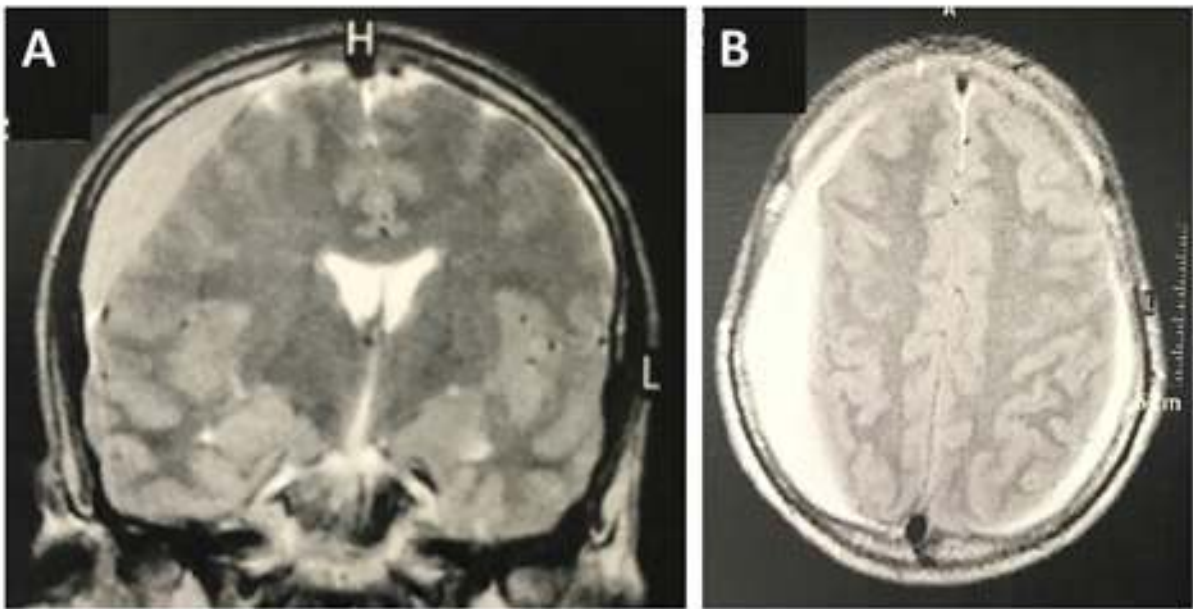


Figure 1. A, coronal view on MRI of the skull showing a supratentorial subdural hematoma with features of chronicity and deviation of midline structures. B, MRI transverse view showing the typical image of a right supratentorial chronic subdural hematoma.

In Figure 2 can be seen the chronic subdural hematoma drainage through a burr hole and exit through the orifice with high pressure of hematic material typically dark in color like petroleum. After drainage, the headache improved.

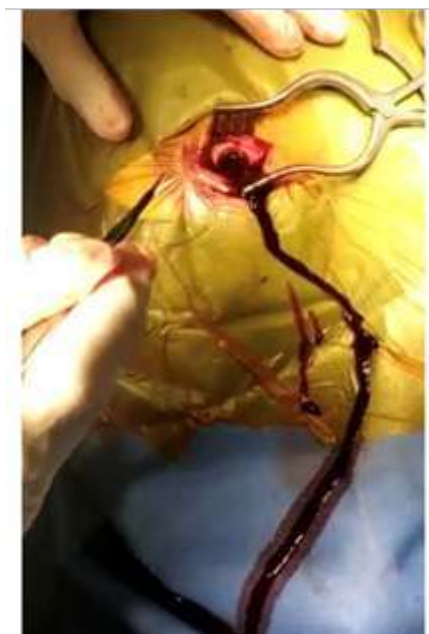

Figure 2. Chronic subdural hematoma drainage through a burr hole and exit through the orifice with high pressure of hematic material typically dark in color like petroleum.

Funding: This study did not receive any funding.

Conflict of interest: There is no conflict of interest to declare.

Authors Contribution: The authors contributed equally to the writing of the manuscript.

Marcelo Moraes Valença

<https://orcid.org/0000-0003-0678-3782>

Luiz Severo Bem Junior

<https://orcid.org/0000-0002-0835-5995>

Ana Cristina Veiga da Silva

<https://orcid.org/0000-0002-1149-4427>

Ubiratan Alves Viturino da Silva

<https://orcid.org/0000-0002-7715-8258>

Marcelo Andrade Valença

<https://orcid.org/0000-0002-0824-0928>

Alberto Henrique Torres Trindade da Silva

<https://orcid.org/0000-0003-2356-4426>

Déborah Emmily de Carvalho

<https://orcid.org/0000-0002-8068-3598>

Henry Martins Soares Fortes

<https://orcid.org/0000-0003-3963-9058>

Martina Falcão Valença

<https://orcid.org/0000-0002-4085-3118>

Luciana Patrícia Alves de Andrade-Valença

<https://orcid.org/0000-0002-3487-0325>

References

1. Stanisic M, Hald J, Rasmussen IA, Pripp AH, Ivanovic J, Kolstad F, . . . Lindegaard KF. **Volume and densities of chronic subdural haematoma obtained from CT imaging as predictors of postoperative recurrence: a prospective study of 107 operated patients.** *Acta Neurochir (Wien)* 2013; 155(2):323-333; discussion 333 Doi:10.1007/s00701-012-1565-0
2. Valença MM, Valença MF, Martins C, Andrade-Valença LPA, Valença MA, Silva ACV and Azevedo Filho HRC. **Guidance for chronic subdural hematoma surgery in the novel coronavirus pandemic (Covid-19).** *Avanços em Medicina* 2021; 1(1):65-74 Doi:10.52329/AvanMed.14
3. Shlobin NA, Kedda J, Wishart D, Garcia RM and Rosseau G. **Surgical Management of Chronic Subdural Hematoma in Older Adults: A Systematic Review.** *J Gerontol A Biol Sci Med Sci* 2021; 76(8):1454-1462 Doi:10.1093/gerona/glaa293
4. Fahmi A, Kustono H, Adhistira KS, Subianto H, Utomo B and Turchan A. **Chronic subdural hematoma-induced parkinsonism: A systematic review.** *Clin Neurol Neurosurg* 2021; 208:106826 Doi:10.1016/j.clineuro.2021.106826
5. Amorim JA, Remigio DS, Damazio Filho O, de Barros MA, Carvalho VN and Valença MM. **Intracranial subdural hematoma post-spinal anesthesia: report of two cases and review of 33 cases in the literature.** *Rev Bras Anesthesiol* 2010; 60(6):620-629, 344-629 Doi:10.1016/S0034-7094(10)70077-5
6. Amorim JA, Gomes de BMV and Valença MM. **Post-dural (post-lumbar) puncture headache: risk factors and clinical features.** *Cephalalgia* 2012; 32(12):916-923 Doi:10.1177/0333102412453951
7. Ironside N, Nguyen C, Do Q, Ugiliweneza B, Chen CJ, Sieg EP, . . . Ding D. **Middle meningeal artery embolization for chronic subdural hematoma: a systematic review and meta-analysis.** *J Neurointerv Surg* 2021; 13(10):951-957 Doi:10.1136/neurintsurg-2021-017352