




## Image in Headache Medicine

### Brainstem tumor as a cause of headache triggered by Valsalva maneuver

Marcelo Moraes Valença<sup>1</sup>  Martina Falcão Valença<sup>2</sup>  Juliana Ramos de Andrade<sup>1</sup>  Elayne Cristina de Oliveira Ribeiro<sup>1</sup>  Luiz Severo Bem Junior<sup>1</sup>  Ana Cristina Veiga Silva<sup>1</sup>  Rita de Cássia Ferreira Valença Mota<sup>1</sup>  Ubiratan Alves Vitorino da Silva<sup>1</sup>  José Ronaldo Lessa Angelo Júnior<sup>1</sup> 

<sup>1</sup>Federal University of Pernambuco, Recife, Pernambuco, Brazil.

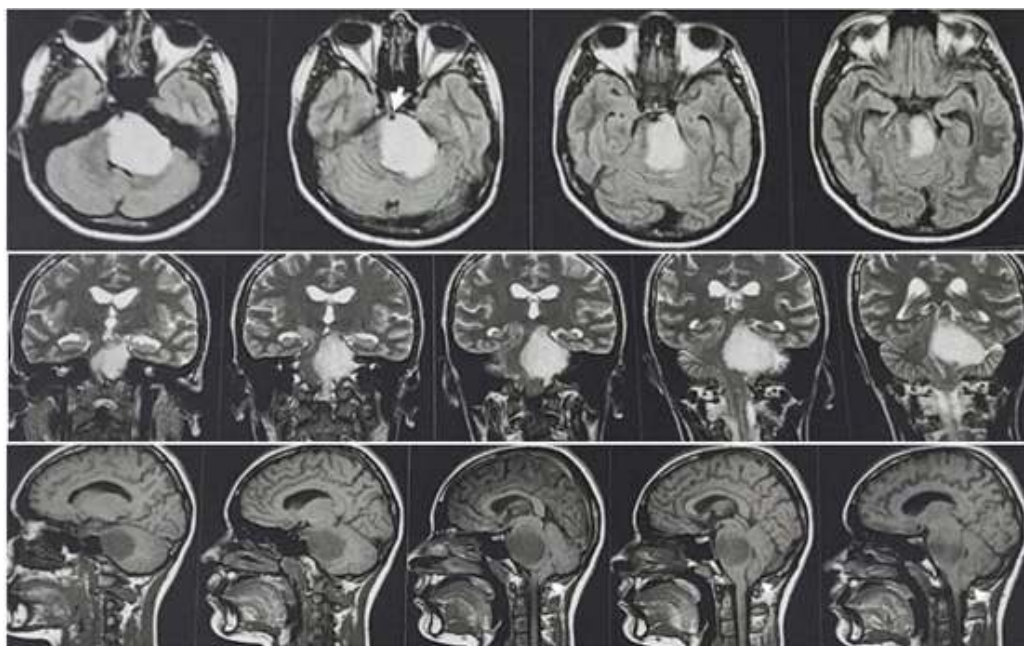
<sup>2</sup>International Neuroscience Institute-Hannover, Germany

  
Marcelo Moraes Valença  
mmvalenca@yahoo.com.br

**Edited by**  
Mario Fernando Prieto  
Peres

Expansive lesions of the posterior fossa or the malformation in the occipitocervical transition can cause headache triggered by Valsalva maneuver, usually of sudden onset and of significant intensity, which usually lasts for a short time.<sup>1-7</sup> Brainstem tumor is rarely related to cause headache<sup>8</sup>, hence the interest in documenting this patient's case in this article.

Figure 1 shows an MRI image of the head of a 26-year-old woman who reported a history of headaches from straining to defecate and when sneezing, with a gradual progression in the previous three years. Pain is holocranial, of sudden onset, very severe, lasting a few seconds or minutes.



**Keywords:**  
Valsalva Maneuver  
Intracranial Pressure  
Sneezing  
Magnetic Resonance  
Imaging  
Brain Stem Neoplasms  
Neuroimaging

**Figure 1.** MRI of an expansive/infiltrative lesion affecting the brainstem, particularly the left pons and the left middle cerebellar peduncle, and partially the cerebellar hemisphere, extending beyond the midline to the right in the pons. The lesion expands anteriorly, significantly reducing the prepontine cistern, partially involving the basilar artery (arrow), slightly shifting to the right. Due to compression of the cerebrospinal fluid pathways, there is a slight dilation of the supratentorial ventricles, without signs of ependymal transudation. There is a herniation of the cerebellar tonsils through the foramen magnum (arrow heads).

Received: August 26, 2021  
Accepted: August 27, 2021

She now has a mild motor deficit in the right lower limb, mild peripheral facial palsy on the left, and hypoesthesia in the left hemiface.

The secondary herniation of the cerebellar tonsils through the foramen magnum may change the cerebrospinal fluid dynamic significantly, causing abrupt elevation of the intracranial pressure, triggering painful mechanisms.<sup>9,10</sup> Although headaches triggered by the Valsalva maneuver may be considered benign, patients with such complaints should be investigated by neuroimaging.<sup>11,12</sup>

**Author's contribution:** MMV – Conceptualization, Investigation, Writing - Original Draft and Supervision; MFV, JRA, ECOR, LSBJr, ACVS, RCFVM, UV - Writing - Review & Editing and Visualization; JRLA – Investigation, Data Curation and Supervision

Marcelo Moraes Valença

<https://orcid.org/0000-0003-0678-3782>

Martina Falcão Valença

<https://orcid.org/0000-0002-4085-3118>

Juliana Ramos de Andrade

<https://orcid.org/0000-0002-5445-8872>

Elayne Cristina de Oliveira Ribeiro

<https://orcid.org/0000-0002-5243-3356>

Luiz Severo Bem Junior

<https://orcid.org/0000-0002-0835-5995>

Ana Cristina Veiga Silva

<https://orcid.org/0000-0002-1149-4427>

Rita de Cássia Ferreira Valença Mota

<https://orcid.org/0000-0003-3588-788X>

Ubiratan Alves Viturino da Silva

<https://orcid.org/0000-0002-7715-8258>

José Ronaldo Lessa Angelo Júnior

<https://orcid.org/0000-0002-4772-3471>

## References

- Buzzi MG, Formisano R, Colonese C and Pierelli F. **Chiari-associated exertional, cough, and sneeze headache responsive to medical therapy.** *Headache* 2003;43(4):404-406 Doi: 10.1046/j.1526-4610.2003.03076.x
- Martins HA, Ribas VR, Lima MD, Oliveira DA, Viana MT, Ribas KH and Valença MM. **Headache precipitated by Valsalva maneuvers in patients with congenital Chiari I malformation.** *Arq Neuropsiquiatr* 2010;68(3):406-409 Doi: 10.1590/s0004-282x2010000300015
- Dawes BH, Lloyd RA, Rogers JM, Magnussen JS, Bilston IE and Stoodley MA. **Cerebellar Tissue Strain in Chiari Malformation with Headache.** *World Neurosurg* 2019;130:e74-e81 Doi: 10.1016/j.wneu.2019.05.211
- Huang CWC, Chang YM, Brook A, Bezuidenhout AF and Bhadelia RA. **Clinical utility of 2-D anatomic measurements in predicting cough-associated headache in Chiari I malformation.** *Neuroradiology* 2020;62(5):593-599 Doi: 10.1007/s00234-019-02356-0
- Bezuidenhout AF, Chang YM, Heilman CB and Bhadelia RA. **Headache in Chiari Malformation.** *Neuroimaging Clin N Am* 2019;29(2):243-253 Doi: 10.1016/j.nic.2019.01.005
- Olszewski AM and Proctor MR. **Headache, Chiari I malformation and foramen magnum decompression.** *Curr Opin Pediatr* 2018;30(6):786-790 Doi: 10.1097/MOP.0000000000000679
- Suwanwela N, Phanthumchinda K and Kaorophum S. **Headache in brain tumor: a cross-sectional study.** *Headache* 1994;34(7):435-438 Doi: 10.1111/j.1526-4610.1994.hed3407435.x
- Duman O, Goksu E, Akyuz M, Haspolat S and Senol U. **Brain stem lipoma presenting as paroxysmal headache with autonomic features.** *Headache* 2004;44(1):105 Doi: 10.1111/j.1526-4610.2004.04019.x
- Ibrahimy A, Huang CC, Bezuidenhout AF, Allen PA, Bhadelia RA and Loth F. **Association Between Resistance to Cerebrospinal Fluid Flow Near the Foramen Magnum and Cough-Associated Headache in Adult Chiari Malformation Type I.** *J Biomech Eng* 2021;143(5):Doi: 10.1115/1.4049788
- Arnautovic KI, Qaladize BF, Pojskic M, Gienapp AJ, Splavski B and Boop FA. **The 270 degrees Circumferential Microsurgical Decompression of the Foramen Magnum in Adult Chiari Malformation Type I: Single Surgeon Series of 130 Patients with Syringomyelia, Neurologic, and Headache Outcomes.** *World Neurosurg* 2021;146:e1103-e1117 Doi: 10.1016/j.wneu.2020.11.102
- Hadidchi S, Surento W, Lerner A, Liu CJ, Gibbs WN, Kim PE and Shiroishi MS. **Headache and Brain Tumor.** *Neuroimaging Clin N Am* 2019;29(2):291-300 Doi: 10.1016/j.nic.2019.01.008
- Taylor LP. **Mechanism of brain tumor headache.** *Headache* 2014;54(4):772-775 Doi: 10.1111/head.12317