



Image in Headache Medicine

Eye pain in 13-year-old teenager: a case report of idiopathic orbital myositis

Renata Barbosa Paolilo Paula da Cunha Pinho

Department of Neurology, Samaritano Hospital of São Paulo, São Paulo, Brazil



Renata Barbosa Paolilo
renatabpaolilo@gmail.com

A previously healthy 13-year-old male presented with sporadic headache that evolved to continuous right eye pain and blurred vision within a week. There was no previous infection or relevant family history. Neurological examination revealed restricted abduction of right eye and horizontal diplopia. Contrast-enhanced orbital magnetic resonance imaging (MRI) is shown in Figures 1 and 2. Cerebrospinal fluid analysis and extensive laboratory workup were normal. He was treated with intravenous corticosteroid for 5 days and oral tapering for 2 weeks. Orbital MRI performed within 2 months resulted normal. After a three-year follow-up, the patient keeps asymptomatic.

Edited by

Mario Fernando Prieto Peres
Marcelo Moraes Valença

Orbital myositis is a non-infectious inflammatory condition of unknown etiology.¹ Pediatric cases account for 6-17% of all orbital inflammatory disorders.² Besides being rare, prompt recognition, diagnosis, and treatment are important. Axial and coronal orbital MRI is a sensitive diagnostic tool.³

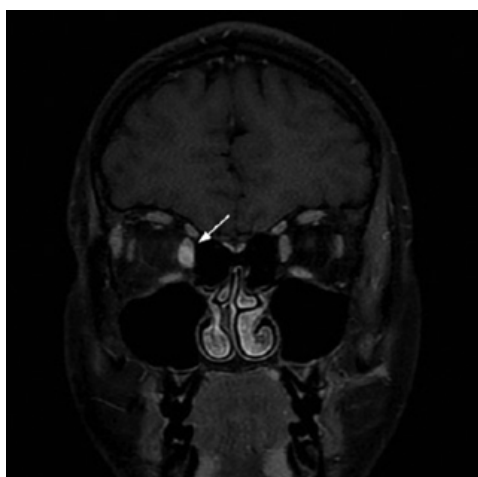


Figure 1. Coronal fat-suppressed contrast-enhanced T1 shows enlarged right medial muscle and mild infiltration of the surrounding fat.

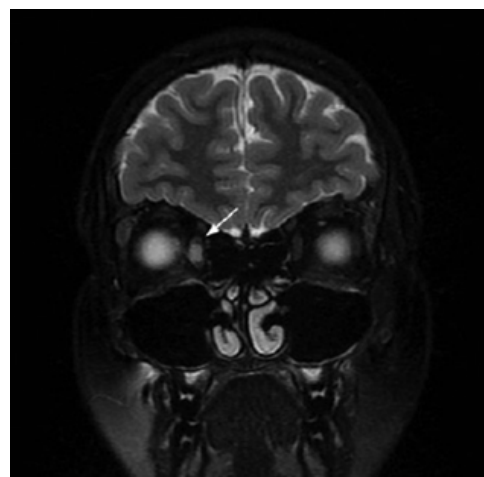


Figure 2. Coronal fat-suppressed T2 shows high signal in the right medial muscle. The classic appearance of extraocular muscle (EOM) myositis includes a unilateral thickening of one or two EOMs, often also involving the surrounding fat, tendon and myotendinous junction.

Keywords:

Orbital myositis
Eye pain
Orbital diseases

Author's Contribution: RBP, data collection, conceptualization and writing; PCP, Data collection, review and editing.

Financing: No

Conflict of interests: No

Renata Barbosa Paolilo. <https://orcid.org/0000-0003-3548-8467>

Paula da Cunha Pinto. <https://orcid.org/0000-0002-9558-2693>

References

1. Mombaerts I, Bilyk JR, Rose GE, Mcnab AA, Fay A, Dolman PJ, . . . Harris GJ. **Consensus on Diagnostic Criteria of Idiopathic Orbital Inflammation Using a Modified Delphi Approach.** *JAMA Ophthalmol* 2017;135(7):769-776 Doi: 10.1001/jamaophthalmol.2017.1581
2. Briones MR, Morgan GA, Amoroso MC, Rahmani B, Ryan ME and Pachman LM. **Decreased CD3-CD16+CD56+ natural killer cell counts in children with orbital myositis: a clue to disease activity.** *RMD Open* 2017;3(1):e000385 Doi: 10.1136/rmdopen-2016-000385
3. Utsunomiya S, Yamamoto D and Uchiyama T. **Orbital myositis presenting with only unilateral orbital pain.** *BMJ Case Rep* 2017; Doi: 10.1136/bcr-2017-220615

Received: March 18, 2021
Accepted: March 30, 2021