



Clinical and physiopathological aspects of the glossopharyngeal neuralgia

Victor Souza  Maria Passerini  Bianca Sobral  Vinicius Baiardi  Hilton Mariano da Silva Junior 

Department of Neurology, Pontifícia Universidade Católica de Campinas, Campinas, São Paulo, Brazil



Hilton Mariano da Silva Junior
drhiltonm@gmail.com

Edited by

Mario Fernando Prieto Peres
Marcelo Moraes Valença

Keywords:

Glossopharyngeal neuralgia
Drug therapy
Glossopharyngeal nerve diseases
Microvascular decompression
Surgery
Anticonvulsant
Carbamazepine

Abstract

Introduction

Glossopharyngeal neuralgia is a rare syndrome characterized by paroxysms of unilateral and severe stabbing pain occurring in the 9th cranial nerve's distribution. Although other neuralgias are well described in the medical literature, glossopharyngeal neuralgia and its physiopathology are scarcely contemplated. The vascular compression at the nerve root entry zone is the primary explanation for the disease. The first-line treatment is pharmacological, including carbamazepine, oxcarbazepine, and gabapentin. Surgical treatment is offered to medication-refractory patients, and microvascular decompression surgery has presented the best outcomes.

Objective

To investigate the pathophysiological and clinical aspects of the different presentations of glossopharyngeal neuralgia.

Method

A narrative review of literature including case reports and clinical trials were carried out. The articles were systematically obtained and assessed by the authors.

Results

A search of literature yielded 31 papers that regarded glossopharyngeal neuralgia or its variants. Among them, eight considered vagoglossopharyngeal neuralgia; and seven focused on the glossopharyngeal neuralgia followed or caused by another disease.

Conclusion

Glossopharyngeal neuralgia is a rare disease and requires further studies on its mechanism and clinical assessment; the physician needs to know how to distinguish it from its variants and underlying causes.



Introduction

Glossopharyngeal neuralgia (GN) is an uncommon craniofacial and pharyngeal pain syndrome characterized by paroxysms of unilateral and severe stabbing pain occurring in the 9th cranial nerve's distribution. According to the International Classification of Headache Disease¹, glossopharyngeal neuralgia is a disorder characterized by a severe, transient, stabbing, unilateral pain experienced in the ear, base of the tongue, tonsillar fossa and/or beneath the angle of the jaw. It also involves the pharyngeal and auricular branches of CN X. The pain may be spontaneous or precipitated by swallowing, chewing, coughing, or talking. It arises from compression, demyelination, or dysfunction of the IX or X nerves. Vasomotor, trophic, or neurovegetative disorders may occur concomitantly with GN, and central or peripheral nerve compromise may be present. This neuralgia may be associated with bradycardia, asystole, convulsions, and even life-threatening syncopal episodes in some patients. GN prevalence is considerably rare, and its diagnosis presents some challenges given the diversity of its clinical picture. The first-line therapy for GN is pharmacologic, using neuromodulating agents, including carbamazepine, oxcarbazepine, gabapentin, pregabalin. For patients with medication-refractory GN, surgical treatment is an alternative, including microvascular decompression (MVD), glossopharyngeal and vagal rhizotomy, gamma knife surgery (GKS), alcohol or glycerol rhizolysis, and pulsed radiofrequency ablation. Glossopharyngeal neuralgia only represents 0.2-1.3% of the facial pain syndromes, which requires a careful investigation during for an accurate diagnosis.

Methods

Articles were obtained through Medline, Embase, and Web of Science databases. The chosen search terms were "neuralgia" AND "glossopharyngeal" AND "physiopathology". These terms were searched independently by the authors, and they have found the same number of articles. These researches happened between 1st and 15th, November, 2020. Only articles from 2000 to 2020 and written in English or Portuguese were eligible. Articles reporting GN and associated syndromes were selected; those that emphasized other diseases were not included. Book chapters, incomplete articles, technical reports, and other reviews were not included. The authors assessed the risk of bias across studies, including trials whose patients were randomly assigned to the study.

Results e discussion

The primary search identified 158 articles (Figure 1). After removing 50 duplicates, title and abstract screening of 108 articles yielded 38 articles for full-text reading. A total of 7 full-text assessed articles were excluded, 5 for addressing other themes but adult GN, and two had their full-text not found. The assessment included 31 articles at the final inclusion.

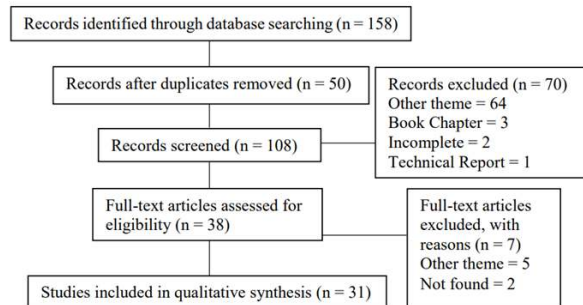


Figure 1. Description of the systematic articles assessment.

Anatomy of the glossopharyngeal nerve

The glossopharyngeal nerve emerges from the medulla between the inferior olive and the inferior cerebellar peduncle, close to the facial and vagus nerves. It exits the skull through the jugular foramen, along with the vagus and accessory nerves. Moreover, the internal jugular vein and the internal carotid artery surround the IX nerve, which courses in front of the carotid artery. At the jugular foramen, the IX nerve divides into three branches: the tympanic nerve (Jacobson's nerve), its only motor branch, supplying the stylopharyngeus muscle, and the carotid sinus nerve.

Physiopathology and etiology

According to the ICHD-3¹, GN is a disorder characterized by paroxysms of unilateral severe stabbing pain, with abrupt onset and termination, in the distributions of the glossopharyngeal nerve and the auricular nerve and pharyngeal branches of the vagus nerve. It is commonly provoked by swallowing, talking, or coughing.²

This neuralgia is classified as classical, secondary, or idiopathic. The classic GN diagnose relies on the association of a suggestive clinical picture and the demonstration on MRI or during surgery of neurovascular compression of the glossopharyngeal nerve root. The secondary GN is caused by an underlying disease, such as neck trauma, multiple sclerosis, tonsillar or regional tumors, cerebello-pontine angle tumors, and Arnold-Chiari malformation.¹ The primary GN mechanism is unclear, although there is a role in vascular



compression at the root entry zone (REZ) of the IX nerve. Even though the posterior inferior cerebral artery (PICA) rarely crosses the glossopharyngeal nerve, it may make an upward loop and compress the supraolivary fossette. The manipulation of a microcatheter and guidewire within the cerebral arteries showed, for the first time, that the PICA compresses IX nerve.³ It is known that not only PICA, but the Anterior Inferior Cerebral Artery (AICA) and the Vertebral Artery (VA) can be offending vessels, which makes the GN diagnosis considerably challenging before surgery.⁴ Ferroli et al.⁵ identified, between 1990 and 2007, vascular compression of the IX nerve in 31 patients with GN. Accordingly, the compressing vessels are as follows: VA in 7, PICA in 22, AICA in one, and a vein in one case. Kawashima et al.² also found their majority offending vessel as arterials, although PICA was the major vessel in just 10 cases, with the AICA accounting for 2 cases. Concerning the causes of secondary GN, it is possible to mention Eagle syndrome (ES), compression by a tumor, aneurysms, parapharyngeal space lesion, multiple sclerosis, trauma, malformations, hyperactive dysfunction syndrome, or post-surgical damages. Many studies⁶⁻¹³ reported GN with the presence of bradycardia, asystole, syncope, or seizure. Most cases are due to vagoglossopharyngeal neuralgia (VGN), which is a rare presentation that accounts for only 2% of GN cases. The most accepted mechanism for VGN is that the excessive painful stimuli from the IX nerve are transmitted through the nucleus of the solitary tract, and then activates the dorsal motor nucleus of the vagus nerve. As a result, it will lead to parasympathetic hyperactivity, inhibiting sympathetic activity, explaining the bradycardia and the asystole in VGN.

This vagal reflex may also reduce cerebral perfusion, leading to syncope and seizures in proportion to the duration of asystole.⁸ Nonetheless, seizures are a rare presentation, as they are a consequence of severe cerebral hypoxia induced by bradycardia and asystole.⁶

Similarly, the solitary tract nucleus may also activate the facial nerve and result in a hemifacial spasm (HFS). Thiarawat et al.¹³ reported a patient with abnormal sternocleidomastoid muscle spasms, while turning his head to the opposite side of the neck pain; according to them, the accessory nerve might have caused the symptom, due to an abnormal synapse with the glossopharyngeal nerve.

Electron microscopic observations have found that the glossopharyngeal and vagus nerves have a short length and a small volume of the central myelin portion. This may explain the low incidence of VGN in the general population. This study found a positive directly proportional correlation between the

dimension of the central myelin portion and the incidences of these neuralgias.¹⁴

Clinical presentation and symptoms

In most common clinical pictures, the onset of GN is subacute, as patients experience unpleasant sensations on one side of the jaw, inside the mouth, and in the ear. Pain distribution is usually unilateral, shock-like, and with successive attacks of pain, not only including the glossopharyngeal nerve, since it may extend to the pharyngeal and auricular branches. When these vagal branches are involved, vagal-damage manifestations are more exacerbated, which may include changes in the voice such as hoarseness and cough. In uncommon cases, pain may be bilateral, since it is present on the other side.¹⁵⁻¹⁷

Pain may also be present in the middle ear, ear canal, posterior portion of the oropharynx, retromolar region, throat, posterior part of the tongue, larynx, and jaw or below the angle of the jaw. This is generally paroxysmal, from 2 seconds to 2 minutes (average duration is 8 to 50 seconds), and can wake the patient up during the night. Thus, GN is divided into two clinical types, based on the distribution of pain: the tympanic (affects the ear) and the oropharynx (affects the oropharyngeal area).¹⁷ In order to confirm the diagnosis, local anesthesia is applied to the pharynx and tonsils, which may pause paroxysms.

The intervals between attacks and exacerbation of the disease are from days to years, and they are irregular.⁴ About 10% of patients with excessive GN have vagal effects during an attack, which can trigger bradycardia, hypotension, syncope, seizures, or even cardiac arrest.^{12,18-24} In uncommon cases, GN may present as syncope without associated pain²⁵, making diagnosis considerably challenging. In addition, because of severe GN pain, patients may experience pallor, followed by hypotension associated with bradycardia. Consequently, this might lead to loss of consciousness and associated tonic-clonic seizure. Other less common features are tinnitus, vomiting, dizziness, a feeling of swelling, involuntary movements, sensory loss of the area innervated by the glossopharyngeal nerve, sweating, salivation, and unilateral mydriasis.²⁶

Pain attacks may occur spontaneously. Yet, they are usually associated with a specific triggering stimulus, such as chewing, swallowing, coughing, yawning, sneezing, clearing your throat, blowing your nose, rubbing your ear, speaking, or laughing^{4,27}. Some patients may experience pain triggered by sweet, acidic, cold, or hot¹⁷, or even turning their heads to the side.¹⁵



Differential diagnosis

Glossopharyngeal neuralgia may be confused with other conditions, like TN, its main differential diagnosis. Although TN pain is more intense, the quality of pain in both may be similar. Besides, trigger zones are more characteristic in TN than in GN. These diseases prevalently occur unilaterally and in weeks to months episodes.²⁸ GN normally affects the left side (88%) and TN, the right (58%).²⁹ There may also be similarities in motor and sensory deficits associated with them. Nevertheless, association with multiple sclerosis only occurs in TN.²⁶ Finally, it should be noted that even if both occur concomitantly, it is possible to separate them by the distinction of pain and trigger factors. In TN, infranasal or cheek pain added to cold or touching face triggers are common. However, in GN, there is tonsillar fossa and pharynx pain, added to swallowing triggers.

The superior laryngeal neuralgia diagnosis may be misleading and challenging, because of the throat pain with an urge to swallow, talking, swallowing, yawning, or coughing as triggers like in GN. The nervus intermedius neuralgia, a further differential diagnosis, is not usually triggered, but occurs spontaneously, and it is always unilateral.

Eagle syndrome is another differential diagnosis of idiopathic GN. Both have a diffuse nature of symptoms, and the pain characterization and location may be similar, but the pain is more constant in ES, which does not manifest tic-like pain attacks. Moreover, the physical exam is important to differentiate them³⁰ because the distance between the styloid process tip and the tonsillar fossa is preserved in idiopathic GN, but it is elongated in the ES.^{31,32} Temporomandibular joint disorders (TMDs) are an important differential diagnosis when manifested unilateral and intermittently similarly to GN. There is temporomandibular joint noise in those diseases, pain on palpation, and worsening pain with chewing.

Swallow syncope may be a differential diagnosis for reflex cardiac syncope by GN, as both occur due to the vasovagal reflex and usually express arterial hypotension. But only in swallow syncope occur structural and functional esophageal and cardiac repercussions without pain or insensibility to swallow.

Finally, ear or sinus infections, dental pain, certain short-lasting headaches, and local affections are other possibilities of GN misdiagnosis.

Pharmacological treatment

Pharmacotherapy is the first line of treatment for glossopharyngeal neuralgia.

Using common analgesics is inefficient. Nevertheless, the most successful medications are anticonvulsants. Drug intolerance, inefficacy, allergy, or associated side effects, such as sedation, dizziness, muscle weakness, cognitive impairment, inhibition of bone marrow, and appearance of dermatological lesions could limit pharmacotherapy and may be an indication for surgical treatment.^{33,34}

Also, a nerve block may be used as a complement to pharmacological treatment for acute pain, with the administration of a local anesthetic agent, such as lidocaine (2%) and bupivacaine (0.5%), with or without steroids, ketamine, phenol, glycerol, and alcohol. Some undesirable effects deserve attention, such as swallowing difficulties and hoarseness. Finally, it is important to highlight that a bilateral nervous block may cause vocal cord paralysis.

For vagoglossopharyngeal neuralgia, when syncope episodes are present, atropine should be used as a drug of choice. Atropine ceases bradycardia¹¹ Notwithstanding, pain attacks tend to persist. Continued administration of carbamazepine may decrease painful symptomatology, as well as heart symptoms³. but it has been known to fail after initial success.³⁵

Using a temporary pacemaker to manage reflex cardiac syncope until ideal therapeutic levels of carbamazepine were reached was initially proposed in 1971 by Khero and Mullins.³⁶ Regarding the use of a definitive pacemaker, the literature is controversial. Kazemi et al.⁷ stated that what led his team to implant a permanent pacemaker in a patient with syncopal storm caused by glossopharyngeal neuralgia was based on the efficacy of this therapy in the treatment of idiopathic carotid hypersensitivity syndrome and on the likelihood of future recurrence of GN.³⁷ However, it is believed that the pharmacological and surgical approaches make the use of the pacemaker unnecessary.⁹

Surgical Treatment

Surgical treatment is indicated for patients whose pharmacotherapy is unsuccessful, for patients with tumors, or those whose interaction between nerves and vessels causes cardiac syndrome.³⁸ This therapy has been described as better successful than pharmacological treatment, but with higher mortality and morbidity rates.³⁹

Surgical therapies include MVD, glossopharyngeal and vagal rhizotomy, GKS, alcohol or glycerol rhizolysis, and pulsed radiofrequency ablation. Furthermore, recurrence rates are shown to be lowered with the surgical approach.⁶ It is important to highlight that the rhizotomy and the MVD



of the IX and the X nerves ensure higher pain relief rates for GN. MVD has the highest initial and long-term success; rhizotomy is a safe and useful backup procedure if MVD is technically difficult.⁴⁰

Microvascular decompression is very effective in decompressing the REZ.⁴¹ Immediate pain relief is found in up to 90% of patients, persisting in 73% of them for 5 years.⁴² Kawashima et al.² report MVD through transcondylar fossa with positive results. MVD is also the treatment of choice in the coexistence of cranial nerve root compression diseases.⁴³ Liu et al.⁴⁰ pointed to the first case of the coexistence of HFS and GN. It is believed that, in this case, MVD is the only option to relieve the compression of the VII and IX nerves, without permanent nerve damage, such as in the rhizotomy.⁴²

Other surgical techniques are options in the management of GN. Notwithstanding, they are considered destructive⁴⁴, such as glycerol or alcohol rhizolysis, GKS, vagus nerve rhizotomy, and radiofrequency thermocoagulation. In these procedures, about 90% of the patients also attended the cessation of symptoms. However, after 5 years, the pain returns in approximately 50% of them.⁴¹ Regarding GKS, the surgery is very expensive, and initial pain relief can take 6 to 8 weeks. The best results are obtained by special neural images.

For elderly patients, a peripheral glycerol injection is an option due to the risk of invasive treatments in patients that have some age-related underlying diseases. Yue et al.⁴⁵ had shown in their study with 21 elderly patients that peripheral glycerol injection can be applied for GN management in patients with a trigger zone around the tonsil. The results indicate that such a method is a safe and effective treatment for the control of idiopathic glossopharyngeal neuropathy in elderly patients since, at the last follow-up evaluation, 15 patients were classified as an excellent outcome. Four cases had a recurrence of pain after 2 and 13 months, and there is no evidence of glossopharyngeal nerve palsy. Complications were not observed.⁴⁵ The therapeutic effect of this procedure is attributed to the toxic effect (demyelination and axonal destruction) of glycerol on peripheral nerves. The mechanism that leads to pain relief is not fully understood but is probably related to a reduction in afferent entry.⁴⁶ Glossopharyngeal or vagal rhizotomy is usually reserved for cases where vascular effects are not evident.¹⁰ Resection of the elongated styloid process utilizing a minimally invasive approach can successfully cure pain in swallow syncope.⁴⁷

An important caveat is that methods such as MVD do not apply to secondary GN. It is in this context that pulsed radiofrequency (PRF) falls. PRF comprises a non-destructive and minimally invasive neuromodulatory method, which can be

used in the management of neuropathic pain. It can be performed by an extraoral posteromedial styloid approach in the presence of rigorous hemodynamic monitoring. Short radiofrequency energy pulses, supplied at a constant temperature produce central and peripheral neuromodulatory effects.⁴⁸ The application of PRF to secondary glossopharyngeal neuralgia had been previously described by Shah et al., in 2003.⁴⁹

Still, like all methods, PRF has its limitations. Bradycardia and hypotension may prevent complete nerve ablation due to vagal stimulation. Besides, all destructive or ablative neural procedures present the risk of neuritis and neurovascular injury. Radiofrequency thermocoagulation of the glossopharyngeal nerve carries the risk of potential damage to the vagus nerve.⁵⁰ Kandan et al.⁶ recommend in their study that both PRF and GKS have shown benefits in the treatment of both primary and secondary GN.⁴⁹

Conclusion

This study aims to gather a sizable amount of information about glossopharyngeal neuralgia, addressing its etiology and physiopathology to its forms of clinical presentation and treatment. Further studies over its specific physiopathology, as well as other glossopharyngeal-related syndromes, are required. The possibilities of treatment vary from the use of drugs to surgical intervention in cases of failure in pharmacological treatment.

Contribution authors: all authors had the same contribution

Funding: No

Conflict of interests: The authors report no conflict of interest

Victor Souza

<https://orcid.org/0000-0003-0974-5474>

Maria Passerini

<https://orcid.org/0000-0002-6096-7171>

Bianca Sobral

<https://orcid.org/0000-0001-8690-2061>

Vinicius Baiardi

<https://orcid.org/0000-0002-6976-9577>

Hilton Junior

<https://orcid.org/0000-0002-9778-9946>

References

1. **The International Classification of Headache Disorders, 3rd edition (beta version).** *Cephalalgia* 2013;33(9):629-808 Doi: 10.1177/0333102413485658
2. Kawashima M, Matsushima T, Inoue T, Mineta T, Masuoka J and Hirakawa NJON. **Microvascular decompression**



- for glossopharyngeal neuralgia through the transcondylar fossa (supracondylar transjugular tubercle) approach. 2010;66(suppl_2):ons275-ons280 Doi: 10.1227/01.neu.0000369662.36524.cf
3. Matsushima T, Goto Y, Ishioka H, Mihara F and Fukui M. **Possible role of an endovascular provocative test in the diagnosis of glossopharyngeal neuralgia as a vascular compression syndrome.** *Acta Neurochir (Wien)* 1999;141(11):1229-1232 Doi: 10.1007/s007010050423
 4. Bruyn GW. **Glossopharyngeal neuralgia.** *Cephalalgia* 1983;3(3):143-157 Doi: 10.1046/j.1468-2982.1983.0303143.x
 5. Ferroli P, Fioravanti A, Schiaritti M, Tringali G, Franzini A, Calbucci F and Broggi G. **Microvascular decompression for glossopharyngeal neuralgia: a long-term retrospective review of the Milan-Bologna experience in 31 consecutive cases.** *Acta Neurochir (Wien)* 2009;151(10):1245-1250 Doi: 10.1007/s00701-009-0330-5
 6. Barbash GI, Keren G, Korczyn AD, Sharpless NS, Chayen M, Copperman Y and Laniado S. **Mechanisms of syncope in glossopharyngeal neuralgia.** *Electroencephalogr Clin Neurophysiol* 1986;63(3):231-235 Doi: 10.1016/0013-4694(86)90089-1
 7. Kandan SR, Khan S, Jeyaretna DS, Lhatoo S, Patel NK and Coakham HB. **Neuralgia of the glossopharyngeal and vagal nerves: long-term outcome following surgical treatment and literature review.** *Br J Neurosurg* 2010;24(4):441-446 Doi: 10.3109/02688697.2010.487131
 8. Kazemi B and Akbarzadeh F. **Syncopal storm caused by glossopharyngeal neuralgia.** *Am J Emerg Med* 2012;30(9):2101.e2105-2107 Doi: 10.1016/j.ajem.2012.03.003
 9. Korkes H, de Oliveira EM, Brollo L, Hachul DT, Andrade JC, Peres MF and Schubsky V. **Cardiac syncope induced by glossopharyngeal "neuralgia": a rare presentation.** *Arq Bras Cardiol* 2006;87(5):e189-191 Doi: 10.1590/s0066-782x2006001800025
 10. Lin HW, Rho MB, Amin-Hanjani S, Barker FG and Deschler DG. **Glossopharyngeal and limited vagal neurectomy for cancer-related carotid sinus syncope.** *Skull Base* 2009;19(5):369-373 Doi: 10.1055/s-0029-1220204
 11. Ozenci M, Karaoguz R, Conkbayir C, Altin T and Kanpolat Y. **Glossopharyngeal neuralgia with cardiac syncope treated by glossopharyngeal rhizotomy and microvascular decompression.** *Europace* 2003;5(2):149-152 Doi: 10.1053/eupc.2002.0298
 12. Saman Y, Whitehead D and Gleeson M. **Jugular foramen schwannoma presenting with glossopharyngeal neuralgia syncope syndrome.** *J Laryngol Otol* 2010;124(12):1305-1308 Doi: 10.1017/s0022215110001556
 13. Thiarawat P, Wangtheraprasert A and Jitprapaikulsan J. **Vago-glossopharyngeal Neuralgia Occurred Concomitantly with Ipsilateral Hemifacial Spasm and Versive Seizure-Like Movement: A First Case Report.** *J Med Assoc Thai* 2016;99(1):106-110
 14. Guclu B, Sindou M, Meyronet D, Streichenberger N, Simon E and Mertens P. **Cranial nerve vascular compression syndromes of the trigeminal, facial and vago-glossopharyngeal nerves: comparative anatomical study of the central myelin portion and transitional zone; correlations with incidences of corresponding hyperactive dysfunctional syndromes.** *Acta Neurochir (Wien)* 2011;153(12):2365-2375 Doi: 10.1007/s00701-011-1168-1
 15. Bohm E and Strang RJB. **Glossopharyngeal neuralgia.** *J Brain* 1962;85(2):371-388 Doi: 10.1093/brain/85.2.371
 16. Rushton JG, Stevens JC and Miller RH. **Glossopharyngeal (vagoglossopharyngeal) neuralgia: a study of 217 cases.** *Arch Neurol* 1981;38(4):201-205 Doi: 10.1001/archneur.1981.00510040027002
 17. Singh PM, Dehran M, Mohan VK, Trikha A and Kaur M. **Analgesic efficacy and safety of medical therapy alone vs combined medical therapy and extraoral glossopharyngeal nerve block in glossopharyngeal neuralgia.** *Pain Med* 2013;14(1):93-102 Doi: 10.1111/pme.12001
 18. Soh KB. **The glossopharyngeal nerve, glossopharyngeal neuralgia and the Eagle's syndrome--current concepts and management.** *Singapore Med J* 1999;40(10):659-665
 19. Thomson JL. **Glossopharyngeal neuralgia accompanied by unconsciousness.** *J Neurosurg* 1954;11(5):511-514 Doi: 10.3171/jns.1954.11.5.0511
 20. Kong Y, Heyman A, Entman ML and McIntosh HD. **Glossopharyngeal neuralgia associated with bradycardia, syncope, and seizures.** *Circulation* 1964;30(109-113) Doi: 10.1161/01.cir.30.1.109
 21. Acosta C and Clark K. **Glossopharyngeal neuralgia associated with cardiac arrest. Case report.** *J Neurosurg* 1970;32(6):706-707 Doi: 10.3171/jns.1970.32.6.0706
 22. St John JN. **Glossopharyngeal neuralgia associated with syncope and seizures.** *Neurosurgery* 1982;10(3):380-383 Doi: 10.1227/00006123-198203000-00015
 23. Ferrante L, Artico M, Nardacci B, Fraioli B, Cosentino F and Fortuna A. **Glossopharyngeal neuralgia with cardiac syncope.** *Neurosurgery* 1995;36(1):58-63; discussion 63 Doi: 10.1227/00006123-199501000-00007
 24. Wallin BG, Westerberg CE and Sundlöf G. **Syncope induced by glossopharyngeal neuralgia: sympathetic outflow to muscle.** *Neurology* 1984;34(4):522-524 Doi: 10.1212/wnl.34.4.522
 25. Esaki T, Osada H, Nakao Y, Yamamoto T, Maeda M, Miyazaki T, . . . Mori K. **Surgical management for glossopharyngeal neuralgia associated with cardiac syncope: two case reports.** *Br J Neurosurg* 2007;21(6):599-602 Doi: 10.1080/02688690701627138
 26. Reddy K, Hobson DE, Gomori A and Sutherland GR. **Painless glossopharyngeal "neuralgia" with syncope: a case report and literature review.** *Neurosurgery* 1987;21(6):916-919 Doi: 10.1227/00006123-198712000-00023



27. Elias J, Kuniyoshi R, Carloni WV, Borges MR, Peixoto CA and Pimentel D. **Glossopharyngeal neuralgia associated with cardiac syncope.** *Arq Bras Cardiol* 2002;78(5):510-519 Doi: 10.1590/s0066-782x2002000500008
28. Teixeira MJ, de Siqueira SR and Bor-Seng-Shu E. **Glossopharyngeal neuralgia: neurosurgical treatment and differential diagnosis.** *Acta Neurochir (Wien)* 2008;150(5):471-475; discussion 475 Doi: 10.1007/s00701-007-1493-6
29. Graff-Radford SB, Newman A and Ananda AJT. **Treatment options for glossopharyngeal neuralgia.** 2005;2(5):733-737 Doi: 10.1586/14750708.2.5.733
30. Katusic S, Williams DB, Beard CM, Bergstralh E and Kurland LT. **Incidence and clinical features of glossopharyngeal neuralgia, Rochester, Minnesota, 1945-1984.** *Neuroepidemiology* 1991;10(5-6):266-275 Doi: 10.1159/000110283
31. Okur A, Ozkırıs M, Serin HI, Gencer ZK, Karaçavuş S, Karaca L, . . . Saydam L. **Is there a relationship between symptoms of patients and tomographic characteristics of styloid process?** *Surg Radiol Anat* 2014;36(7):627-632 Doi: 10.1007/s00276-013-1213-2
32. Slavin KV. **Eagle syndrome: entrapment of the glossopharyngeal nerve? Case report and review of the literature.** *J Neurosurg* 2002;97(1):216-218 Doi: 10.3171/jns.2002.97.1.0216
33. Lenzi R, De Vito A, Dallan I and Muscatello L. **MRI findings in a patient with glossopharyngeal neuralgia.** *Ear Nose Throat J* 2010;89(5):210-212
34. Sampson JH, Grossi PM, Asaoka K and Fukushima T. **Microvascular decompression for glossopharyngeal neuralgia: long-term effectiveness and complication avoidance.** *Neurosurgery* 2004;54(4):884-889; discussion 889-890 Doi: 10.1227/01.neu.0000114142.98655.cc
35. Larsen A, Piepgras D, Chyatte D and Rizzolo D. **Trigeminal neuralgia: diagnosis and medical and surgical management.** *Jaapa* 2011;24(7):20-25 Doi: 10.1097/01720610-201107000-00005
36. Taylor PH, Gray K, Bicknell PG and Rees JR. **Glossopharyngeal neuralgia with syncope.** *J Laryngol Otol* 1977;91(10):859-868 Doi: 10.1017/s0022215100084486
37. Khero BA and Mullins CB. **Cardiac syncope due to glossopharyngeal neuralgia. Treatment with a transvenous pacemaker.** *Arch Intern Med* 1971;128(5):806-808
38. Jamshidi A and Masroor MA. **Glossopharyngeal neuralgia with cardiac syncope: treatment with a permanent cardiac pacemaker and carbamazepine.** *Arch Intern Med* 1976;136(7):843-845
39. Hupp WS and Firriolo FJ. **Cranial neuralgias.** *Dent Clin North Am* 2013;57(3):481-495 Doi: 10.1016/j.cden.2013.04.009
40. Chua NH, Beems T and Vissers KC. **Two cases of glossopharyngeal neuralgia successfully treated with pulsed radiofrequency treatment.** *Ann Acad Med Singap* 2011;40(8):387-389
41. Peet MM. **Glossopharyngeal neuralgia.** *Ann Surg* 1935;101(1):256-268 Doi: 10.1097/00000658-193501000-00026
42. Liu J, Shen Y, Jiang B, Yuan Y and Yu Y. **Ameliorating Effect of Microvascular Decompression on Patients with Coexistence of Hemifacial Spasm and Glossopharyngeal Neuralgia: A Retrospective Study.** *World Neurosurg* 2020;133(e62-e67 Doi: 10.1016/j.wneu.2019.08.069
43. Obermann M and Katsarava Z. **Update on trigeminal neuralgia.** *Expert Rev Neurother* 2009;9(3):323-329 Doi: 10.1586/14737175.9.3.323
44. Zhong J, Zhu J, Li ST and Guan HX. **Microvascular decompressions in patients with coexistent hemifacial spasm and trigeminal neuralgia.** *Neurosurgery* 2011;68(4):916-920; discussion 920 Doi: 10.1227/NEU.0b013e318208f5ac
45. Spencer CJ and Gremillion HA. **Neuropathic orofacial pain: proposed mechanisms, diagnosis, and treatment considerations.** *Dent Clin North Am* 2007;51(1):209-224, viii Doi: 10.1016/j.cden.2006.09.006
46. Papalexopoulou N, Hasegawa H, Selway R, Chong S and Ashkan K. **The treatment of combined trigeminal and glossopharyngeal neuralgia by glycerol rhizolysis of the trigeminal ganglion.** *Br J Neurosurg* 2015;29(1):92-93 Doi: 10.3109/02688697.2014.957155
47. Montalbetti L, Ferrandi D, Pergami P and Savoldi F. **Elongated styloid process and Eagle's syndrome.** *Cephalalgia* 1995;15(2):80-93 Doi: 10.1046/j.1468-2982.1995.015002080.x
48. Higuchi Y, Nashold BS, Jr., Sluijter M, Cosman E and Pearlstein RD. **Exposure of the dorsal root ganglion in rats to pulsed radiofrequency currents activates dorsal horn lamina I and II neurons.** *Neurosurgery* 2002;50(4):850-855; discussion 856 Doi: 10.1097/00006123-200204000-00030
49. Shah RV and Racz GB. **Pulsed mode radiofrequency lesioning to treat chronic post-tonsillectomy pain (secondary glossopharyngeal neuralgia).** *Pain Pract* 2003;3(3):232-237 Doi: 10.1046/j.1533-2500.2003.03028.x
50. Arias MJ. **Percutaneous radio-frequency thermocoagulation with low temperature in the treatment of essential glossopharyngeal neuralgia.** *Surg Neurol* 1986;25(1):94-96 Doi: 10.1016/0090-3019(86)90124-2