

Acute calcific retropharyngeal tendinitis: a three-case series and a literature review

Tendinite retrofaríngea calcificada aguda: série de três casos e revisão de literatura

Paulo Sérgio Faro Santos¹
Ana Carolina Andrade²

¹Neurologist, Head of the Headache and Orofacial Pain Sector, Department of Neurology, Institute of Neurology of Curitiba, PR, Brazil

²Resident doctor, Department of Neurology, Institute of Neurology of Curitiba, PR, Brazil

ABSTRACT

Acute retropharyngeal tendinitis is a rare, self-limiting, benign condition that is poorly described in the literature. It is clinically characterized by neck pain and stiffness and either dysphagia or odynophagia. Diagnosis depends on clinical suspicion and imaging examination (computed tomography of the cervical spine is the gold standard), with calcification found in the anterior region of the first and second vertebrae. The disease usually presents good clinical course, with satisfactory response to the use of either non-steroidal anti-inflammatory drugs or corticosteroids, with remission of symptoms in days to weeks and of the calcification process in weeks to months.

Keywords: Headache; Deglutition disorder; Tendon injury.

RESUMO

Tendinite retrofaríngea aguda é uma condição rara, autolimitada, benigna e pouco descrita na literatura. Caracteriza-se clinicamente por cervicalgia, rigidez de pescoço e disfagia ou odinofagia. O diagnóstico depende da suspeição clínica e de exame de imagem, sendo a tomografia computadorizada de coluna cervical o padrão-ouro, com o achado de calcificação em região anterior da primeira e segunda vértebras. A doença costuma apresentar uma boa evolução clínica, com resposta satisfatória ao uso de anti-inflamatórios não esteroidais ou corticosteroides, com remissão dos sintomas em dias a semanas e do processo de calcificação em semanas a meses.

Descritores: Cefaleia; Distúrbio da deglutição; Tendinopatia

*Correspondence

Paulo Faro
E-mail: dr.paulo.faro@gmail.com

Received: September 1, 2019.
Accepted: September 8, 2019.

DOI: 10.5935/2178-7468.20190005

INTRODUCTION

Acute retropharyngeal calcific tendinitis is a rare, self-limiting, benign condition that is poorly described in the literature. It was first reported in 1964 by Hartley¹. The incidence of the disease is uncertain and the age it usually manifests is between 30 and 60 years, though there are reports that vary from 21 to 81 years of age². The condition is characterized by an inflammatory process in the longus colli muscle, with the deposition of calcium hydroxyapatite crystals more commonly on the superior oblique tendon of the muscle¹. It is classically characterized by the triad of neck pain, neck stiffness and either dysphagia or odynophagia¹. A computed tomography of the cervical spine is the gold standard for investigations³. Though the disease presents a self-limited course, it can be very impairing and require the prescription of non-steroidal anti-inflammatory drugs or corticosteroids so to accelerate the process of clinical improvement⁴. The objective of the present study was to describe three cases of individuals that sought urgent medical care at a neurological hospital due to intense neck pain and were suspected of having retropharyngeal tendinitis after they reported a worsening in the pain with deglutition.

Case 1

Male, 45 years old, presented intense pulsating left occipital headache with ipsilateral parietal radiation, that worsened with speech, deglutition and head movement. The pain began while sleeping three days prior. During examination, the patient showed antalgic limitations regarding neck rotation and extension, with no further findings. Magnetic resonance and cervical spine tomography images showed prevertebral calcification between C1 and C2. After treatment with intravenous analgesic, anti-inflammatory and corticoid drugs, there was complete remission of the condition.

Case 2

Female, 33 years old, with insidious yet intense occipital headache and neck pain, associated with odynophagia and functional limitation of the neck over the past two weeks and without improvement using common analgesics. When examined, the patient reported pain when extending and rotating the neck and pain during palpation of the cervical spine apophyses. Computed tomography images of the cervical spine revealed calcification and edema of the prevertebral soft tissue at the C2 level (Figure 1). Treatment with an oral corticoid led to symptom improvement during the first week.

Case 3

Male, 31 years old, suffering from neck pain for five days and with worsening over the previous 24 hours, limited range of neck movement, and associated with

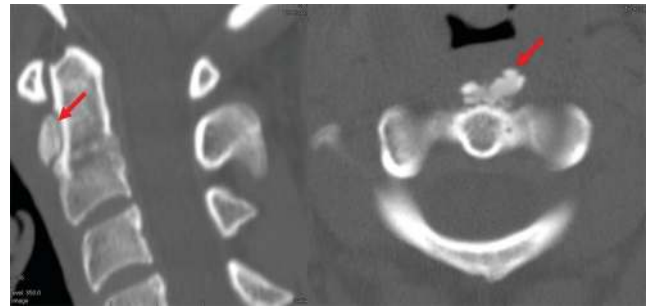


Figure 1. Computed tomography of the cervical spine: presence of calcification in the anterior region of C2 (sagittal and axial sections, respectively). Source: personal archive.

paresthesia and hypoesthesia in the left ear and left cervical region. Denied having a fever. When examined, the patient showed limited neck movement in all directions and hypoesthesia in the left cervical region. Initially submitted to a computed tomography of the cervical spine that showed hyperdensity at the back of C1 and C2 cervical processes. A magnetic resonance of the cervical spine was then requested, which showed a hypersignal in T2 at the back of vertebrae C1, C2 and C3, compatible with edema of the longus colli muscle (Figure 2). The patient was treated with corticosteroids (prednisone) for seven days but did not return for follow-up.

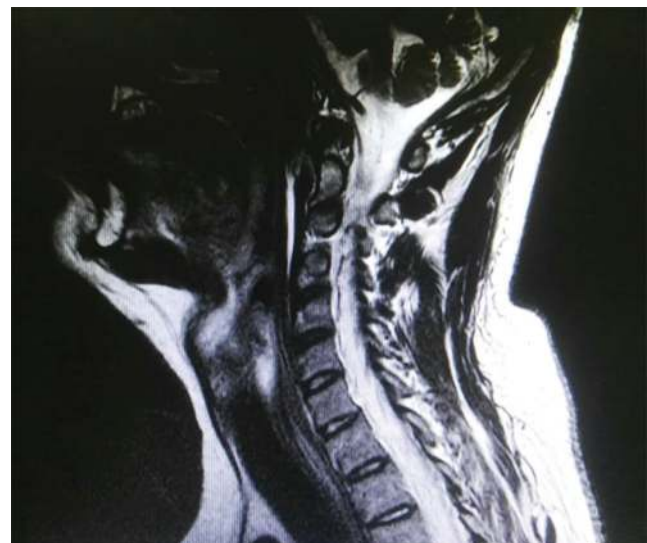

Figure 2. Magnetic resonance of the cervical spine: hypersignal in T2 at the back of C1, C2 and C3. Source: personal archive.

DISCUSSION

Since acute retropharyngeal tendinitis was first described in 1964, little more than 80 cases have been reported in the literature⁵. The incidence of the disease is unknown, though it is estimated as 0.5 case per 100,000 inhabitants⁶. Though there seems to be no difference between sexes affected, some studies indicate that women are slightly more prone to the condition, accounting for close to 58% of cases^{7,8}.

In a literature review conducted by Park *et al.*¹, with 71 cases described, age varied from 21 to 65 years and the time of establishing a diagnosis since the beginning of the symptoms ranged from less than seven days to 21 days.

Regarding anatomy, the longus colli muscle is one of the four muscles that form the anterior cervical region. It originates from the vertebral bodies of C3-C7 and T1-T3, becoming inserted along the bodies of C2-C4 and anterior tubercles of vertebrae C1-C6. This muscle is divided in vertical, superior oblique and inferior oblique portions⁹. The superior oblique portion, which originates from the anterior tubercles of transverse processes in C3 to C5, is the part that is involved in acute retropharyngeal tendinitis¹⁰.

The etiology of the disease is still unclear, but it is believed that repetition trauma, ischemia, necrosis, tendon degeneration, chronic kidney disease, collagen vascular disease and osteoarthritis are involved in the pathogenesis of retropharyngeal tendinitis¹. Regarding the physiopathology of the disease, a model has been proposed dividing the process into five phases: pre-calcification, formative, rest, reabsorption and post-calcific¹¹. The process is believed to begin after exposure to an unknown triggering factor, which leads to fibrocartilaginous metaplasia of tendon cells associated with an accumulation of calcium crystals in the matrix vesicles. The formation of calcium centers separated by fibrocartilage (formative phase) is followed by the rest phase. The later appearance of vascular channels and phagocytosis of fragments mediated by macrophages (reabsorption phase) precedes the post-calcific phase, which is characterized by deposition mediated with type-III collagen fibroblasts and formation of granulation tissue⁴.

The disease has variable clinical presentations¹. Its beginning is typically either acute or subacute with neck pain that can spread to the occipital region, associated with neck stiffness, odynophagia or dysphagia¹. A relevant aspect is that neck pain may worsen with deglutition and head movement¹. Moreover, headaches, longus colli muscle spasms, limitation in neck movement, particularly extension, pharyngeal edema, nasopharyngeal erythema, fever, increase inflammatory markers, and leukocytosis can also be present¹².

Physical examination of the patient reveals spasms in cervical spinal musculature and palpation of the anterior cervical region between the sternocleidomastoid muscle and larynx can be painful due to direct manipulation of the longus colli muscle¹. The posterior aspect of the nasopharynx is usually swollen and erythematous¹³.

Regarding diagnostic imaging, computed tomography of the cervical spine is considered the gold standard¹⁴. Pathognomonic findings are represented by amorphous calcification anterior to the vertebral body of either the first or second cervical vertebrae and edema in prevertebral soft tissues, which can extend from the first to the fourth cervical vertebra associated with a collection of fluid in the retropharyngeal space¹⁴. In turn, while a nuclear magnetic resonance is an excellent

method to identify edema of soft tissues and collection of fluids, it is not appropriate to observe calcification¹⁵. T2-weighted sagittal section hyperintensity in the prevertebral region at the level of C2 to C6, though potentially extending to the base of the skull, is a characteristic finding in retropharyngeal tendinitis¹⁶. It indicates edema of the longus colli muscle¹⁷. Cervical spine lateral view radiographs do not detect calcification in a small percentage of patients¹⁹.

The possibility for differential diagnoses is broad and with potentially severe conditions that should be quickly excluded, such as: retropharyngeal abscess, cervical osteomyelitis and vertebral artery dissection¹⁴. Other conditions include meningitis, neoplasia, cervical myelopathy, traumatism, foreign body aspiration and spondylodiscitis¹³. In turn, differential diagnoses by imaging include bulging cervical disc and bone fragment from an avulsion fracture when there is a history of recent trauma¹⁴.

The natural history of the disease is marked by spontaneous resolution, approximately two weeks after the symptoms begin¹⁷. However, the use of nonsteroidal anti-inflammatory drugs accelerates the healing process, thus promoting an improvement in the condition within 24 to 48 hours¹³. In cases of severe pain, the use of corticosteroids and opioids is necessary. Patients become asymptomatic after seven to 15 days and the calcification process disappears in one to two months¹⁹.

CONCLUSION

Although retropharyngeal tendinitis is a rare clinical condition, it should be part of clinical suspicion when in face of a case of neck pain, particularly when it worsens during deglutition, and should be a differential diagnosis for occipital headaches.

REFERENCES

1. Park R, Halpert DE, Baer A, Kumar D, Holt PA. Retropharyngeal calcific tendinitis: Case report and review of the literature. *Semin Arthritis Rheum* 39:504-509.
2. Horowitz G, Oded Ben-Ari MPH, Brenner A, et al. Incidence of Retropharyngeal Calcific Tendinitis (Longus Colli Tendinitis) in the General Population. *Otolaryngology Head and Neck Surgery*, 2013; 148(6): 955-958.
3. Tagashira Y, Watanuki S. Acute calcific retropharyngeal tendonitis. *CMAJ*, 2015, 187(13): 995.
4. Zibis AH, Giannis D, Malizos KN, Kitsioulis P, Arvanitis DL. Acute calcific tendinitis of the longus colli muscle: case report and review of the literature. *Eur Spine J* (2013) 22 (Suppl 3):S434-S438.
5. Suh B, Eoh J, Shin J. Clinical and Imaging Features of Longus Colli Calcific Tendinitis: An Analysis of Ten Cases. *Clinics in Orthopedic Surgery* 2018;10:204-209.
6. Zapolsky N, Heller M, Felberbaum M, Rose J, Steinberg E. Calcific tendonitis of the longus colli: an uncommon but benign cause of throat pain that closely mimics retropharyngeal abscess. *J Emerg Med*. 2017; 52(3):358-360.
7. Boikov AS, Griffith B, Sthemer M, Jain R. Acute Calcific Longus Colli Tendinitis. An Unusual Location and Presentation. *Arch Otolaryngol Head Neck Surg*. 2012;138(7):676-9.

8. Lewi Z, Carrol J, Farley H. Begin nuchal rigidity: the emergency department evaluation of acute prevertebral calcific tendonitis. *West J Emerg Med*, 2012; 13: 114-6.
9. Ellika SK, Payne SC, Patel SC, Jain R. Acute calcific tendinitis of the longus colli: an imaging diagnosis. *Dentomaxillofacial Radiology*. 2008; 37: 121-124.
10. Hervig SR e Gluckam J. Acute Calcific Retropharyngeal Tendonitis. *Arch Otolaryngol*. 1982;108:41-42.
11. Ring D, Vaccaro AR, Scuderi G, Pathria MN, Garfin SR. Acute Calcific Retropharyngeal Tendinitis. *J Bone Joint Surg Am*. 1994; 76(11):1636-42.
12. Alamoudi U, Al-Sayed AA, AlSallumi Y, Rigby MH, Taylor SM, Hart RD. Acute calcific tendinitis of the longus colli muscle masquerading a retropharyngeal abscess: A case report and review of the literature. *Internacional Journal of Surgery Case reports*. 2017; 41: 343-346.
13. Ramahnian R, Diamond C. Calcific Tendonitis of the Longus Colli Muscle: A Noninfectious Cause of Retropharyngeal Fluid Collection. *Case Reports in Otolaryngology Volume 2014*, Article ID 286190, 4 pages.
14. Arteni DJ, Lipman JK, Scidmore GK, Brant-Zawadzki M. Acute neck pain due to tendonitis of the longus colli: CT and MRI findings. *Neuroradiology*. 1989; 31:166-169.
15. Raggio BS, Ficenec SC, Pou J, Moore B. Acute Calcific Tendonitis of the Longus Colli. *Ochsner J*. 2018; 18(1): 98-100.
16. Southwell K, Hornibrook J, O'Neill-Kerr D. Acute longus colli calcific tendonitis causing neck pain and dysphagia. *Otolaryngol Head Neck Surg*. 2008; 138(3):405-6.
17. Ekbohm K, Torhall J, Anell K, Träff J. Magnetic resonance imaging in retropharyngeal tendinitis. *Cephalalgia* 1994; 14:266-9.
18. Eastwood JD, Hudgins PA, Malone D. Acute calcific retropharyngeal tendinitis. Clinical presentation and pathological characterization. *AJNR Am J Neuroradiol*. 1998;19(9):1789-92.
19. Fumitake Tezuka, Toshinori Sakai, Ryo Miyagi, Yoichiro Takata, Kosaku Higashino, Shinsuke Katoh et al. Complete Resolution of a Case of Calcific Tendinitis of the Longus Colli with Conservative Treatment. *Asian Spine J*. 2014; 8(5): 675-679.