

Intracranial lipoma manifesting with change in preexisting headache characteristics

Lipoma intracraniano que se manifesta com mudança das características de cefaleia preexistente

Patrick Emanuell Mesquita Sousa Santos¹
Ivan Rodrigues Silva²
Mário Fernando Prieto Peres³
Raimundo Pereira Silva-Néto¹

¹Federal University of Delta of Parnaíba, Brazil.

²Dirceu Arcoverde State Hospital, Parnaíba, Brazil.

³Education and Research Israelite Institute Albert Einstein, Brazil; Institute of Psychiatry, HCFMUSP, Brazil.

ABSTRACT

Intracranial lipomas represent 0.1% to 0.5% of all intracranial tumors. Approximately half of the patients are asymptomatic. In symptomatic patients, headache is the most common symptom. We describe the case of a 71-year-old woman with history of generalized seizures and episodic migraine for about 30 years. In recent months, there has been a change in the characteristics of headache. She was admitted to the emergency room with muscle weakness in left hemibody and intense headache onset approximately four hours ago. Neuroimaging exams revealed a median frontal expansive lesion suggestive of intracranial lipoma.

Keywords: Migraine; Epilepsy; Intracranial lipoma.

RESUMO

Lipomas intracranianos representam 0,1% a 0,5% de todos os tumores intracranianos. Cerca de metade dos pacientes portadores dessa rara formação são assintomáticos. Naqueles sintomáticos, a cefaleia é o principal sintoma. Nós descrevemos o caso de uma mulher de 71 anos com história de convulsões e migrânea episódica há cerca de 30 anos. Nos últimos meses, houve mudanças nas características da dor. Ela foi admitida na emergência com fraqueza muscular no hemicorpo esquerdo e intensa cefaleia, com início há cerca de quatro horas. Os exames de imagem revelaram uma lesão expansiva frontal mediana sugestiva de lipoma intracraniano.

Descritores: Migrânea; Epilepsia; Lipoma intracraniano.

*Correspondence

R. P. Silva-Néto
Federal University of Delta of Parnaíba,
Avenida São Sebastião, 2819, Fátima,
Parnaíba, PI 64001-020, Brazil. E-mail:
neurocefaleia@terra.com.br

Received: December 15, 2019.
Accepted: December 22, 2019.

DOI: 10.5935/2178-7468.20190031



We describe the case of a 71-year-old woman with history of generalized seizures and episodic migraine for about 30 years. Headache presented pressure characteristics, worsening in the last two months. Before, she had three headache attacks a week, but in recent months, headache occurs daily. Headache attacks don't remit with simple analgesics. Recently, she was admitted to the emergency room with muscle weakness in left hemibody and intense headache onset approximately four hours ago. Her neurologic examination was normal. Diagnostic hypothesis of stroke was considered. She underwent a CT scan of the skull that showed an interhemispheric hypodense mass. MRI revealed a median frontal expansive lesion suggestive of intracranial lipoma (Figure 1).

Intracranial lipomas (IL) represent 0.1% to 0.5% of all intracranial tumors and are located mainly in the area of corpus callosum¹. A retrospective study with 17 patients diagnosed with IL was conducted at a tertiary center. He showed that 47% of these patients complained of

headache². There is another study stating that half of the cases of IL was asymptomatic. In the other half, the main symptoms were seizures, headache and muscle weakness³.

Surgical intervention is rarely required, because there may be vascular structures near or within the lipomas and complications may develop due to surgical excision². Thus, the best therapeutic option for IL symptoms remains unclear.

REFERENCES

1. Ben Elhend S, Belfquih H, Hammoune N, Athmane EM, Mouhsine A (2019) Lipoma withagenesis of corpus callosum: 2 case reports and literature review. *World Neurosurg*, 125:123-125.
2. Seidl Z, Vaneckova M, Vitak T (2007), Intracranial lipomas: A retrospective study. *Neuroradiol J*, 20(1):30-36.
3. Piovesan EJ, Tatsui CE, Kowacs PA, Prazeres RF, Lange MC, Antoniuk SA, et al (2000), Lipoma do corpo caloso associado a hipertrofia do corpo caloso: Relato de caso. *Arq Neuropsiquiatr*, 58(3B):947-951.

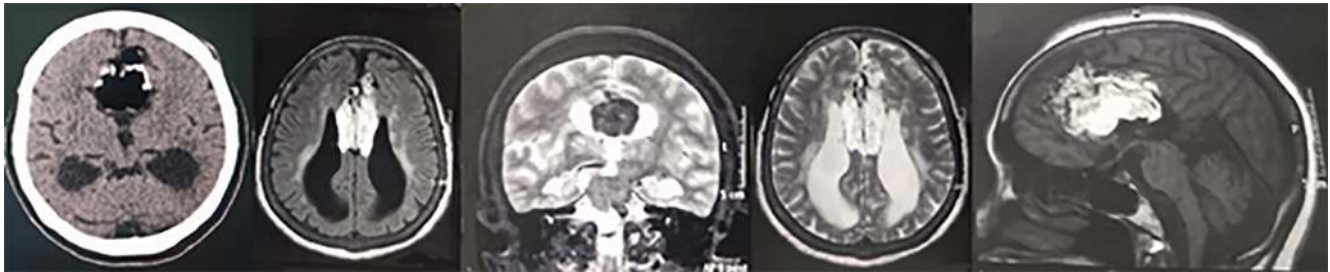


Figure 1. (A) CT. (B) Axial RNM T1W. (C) Coronal RNM T2W. (D) Axial RNM T2W. (E) Sagittal RNM T1W. Frontal median lesion of fat content measuring about 6.6 x 4.5 x 3.5 cm associated with signs of corpus callosum dysgenesis and colpocephalic aspect of the lateral ventricles.