Functional anatomy of headache: hypothalamus

Anatomia funcional da cefaleia: hipotálamo

Marcelo Moraes Valença[1], Luciana P. A. Andrade-Valença[1], Carolina Martins[2]

[1]Neurology and Neurosurgery Unit, Universidade Federal de Pernambuco, Recife, PE, Brazil and Hospital Esperança, Recife, PE, Brazil
[2]Medical School of Pernambuco IMIP, Recife, PE, Brazil

Valença MM, Andrade-Valença LP, Martins C
Functional anatomy of headache: hypothalamus. Headache Medicine. 2011;2(4):165-72

ABSTRACT

There is now compelling evidence that the hypothalamus exerts a major role in the mechanism of headache triggering. Pain and concomitant changes in the hormonal secretory pattern occur during an attack of headache when hypothalamic structures are involved. During spontaneous migraine or cluster headache attacks activation of the hypothalamus is shown by positron emission tomography. Over the past 10 years a number of patients with refractory chronic cluster headache have received neurostimulation of the posteroinferior hypothalamus as a form of treatment. The clinical use of deep brain stimulation (DBS) is based on the theory of posterior hypothalamic nucleus dysfunction as the cause of cluster headache attacks. In this article the authors review the functional anatomy of the hypothalamic region and its neighborhood, using silicone-injected cadaveric head and MRI. In conclusion, a better understanding of the functional anatomy of the hypothalamus and its neighborhood is imperative for understanding the pathophysiology of several of the primary headaches, particularly migraine and the trigemino-autonomic headaches. Direct stimulation of the posterior hypothalamic region using DBS devices is now the "state of the art" form of treatment indicated for refractory chronic cluster headache. The exact mechanism and the actual region where the DBS may act are still unknown, and studies on the functional anatomy of the hypothalamus are crucial to the progress in this marvelous field of functional neurosurgery.

Keywords: Anatomy; Hypothalamus; Cluster headache; Migraine; DBS; MRI

RESUMO

Há agora evidência suficiente indicando exercer o hipotálamo um importante papel no mecanismo de deflagração de uma crise de cefaleia. Dor e alterações concomitantes no padrão secretório hormonal ocorrem durante uma crise de cefaleia quando o hipotálamo é envolvido. Ativação do hipotálamo foi mostrada na tomografia por emissão de pósitrons durante crises espontâneas de migrânea ou de cefaleia em salvas. Durante a última década, um número de pacientes com cefaleia em salvas crônica refratária recebeu neuroestimulação no hipotálamo posterior como forma de tratamento. O uso clínico de estimulação cerebral profunda foi baseado na teoria de haver uma disfunção no núcleo hipotalâmico posterior como causa das crises de salvas. Neste artigo, os autores estão revisando a anatomia funcional da região hipotalâmica e sua vizinhança, utilizando cabeça cadavérica injetada com silicone e imagens de ressonância magnética. Concluindo, um melhor entendimento da anatomia funcional do hipotálamo e sua vizinhança é imperativo para compreender a patofisiologia de várias das cefaleias primárias, em particular da migrânea e das cefaleias trigêmino-autonômicas. Estimulação direta da região hipotalâmica posterior é agora o "estado da arte" no tratamento da cefaleia em salvas crônica refratária. O mecanismo exato e a região onde a estimulação atuaria ainda são desconhecidos; estudos no campo da anatomia funcional do hipotálamo são críticos para que haja progresso neste novo e encantador setor da neurocirurgia funcional.

Palavras-chave: Anatomia; Hipotálamo; Cefaleia em salvas; Migrânea; Ressonância magnética; Estimulação cerebral profunda

INTRODUCTION

There is now compelling evidence that the hypothalamus exerts a major role in the mechanism of headache triggering.[1-11] Pain and concomitant changes in the hormonal secretory pattern occur during an attack of headache when hypothalamic structures are involved.[5] For instance, the hypothalamus, especially in the posterior region, is activated during attacks of trigeminal autonomic headaches, such as cluster headache, paroxysmal hemicrania and short-lasting unilateral neuralgiform headache attacks with conjunctival injection and tearing (SUNCT), while during migraine attacks the activation occurs preponderantly in the brainstem (e.g., dorsal pontine region), but hypothalamic activation also occurs.[1,2]

The hypothalamus and the adjacent brainstem form a complex interconnected structure responsible for the chronobiological features of some types of primary headache, especially sleep-related attacks, a characteristic feature of trigeminal autonomic headaches, hypnic headache and migraine.[12]

The hypothalamus, through hormonal and autonomic regulation, controls a number of physiological functions, such as blood pressure, fluid and electrolyte balance, body temperature, and body weight, maintaining a fairly constant value known as the "set point".[13,14]

The hypothalamic nuclei constitute part of the corticodiencephalic circuitry activating, controlling, and integrating the peripheral autonomic mechanisms, endocrine activity, and many somatic functions, e.g., regulation of water balance, body temperature, sleep, food intake, and the development of secondary sexual characteristics.[7]

The hypothalamus is wired in the brainstem to the periaqueductal gray substance, the locus coeruleus, and the median raphe nuclei, all of which are involved in autonomic, sleep, and in the descending control of pain perception mechanisms. The hypothalamus also receives input from different locations of the central nervous system, obtaining information on the state of the body, thereby initiating compensatory physiological changes.[7]

These inputs come from: (1) nucleus of the solitary tract, with information on blood pressure and gut distension; (2) reticular formation, receiving information on skin temperature; (3) retina and optic nerve, whose fibers go directly to the suprachiasmatic nucleus and are involved in the regulation of circadian rhythms; (4) circumventricular organs, nuclei located along the ventricles, which lack a blood-brain barrier, allowing them to monitor substances in the blood (e.g., *organum vasculosum of the lamina terminalis*, which is sensitive to changes in osmolarity, and the *area postrema*, which is sensitive to toxins in the blood and can induce vomiting); and[5] the limbic and olfactory systems. Structures such as the amygdala, the hippocampus, and the olfactory cortex, all of which are connected with the hypothalamus, regulate a broad range of psychological and physiological functions, including anger, fear, reproduction, learning and memory, drinking, eating, autonomic activity and pain.[7,13,14]

The hypothalamus is continually informed of the physiological changes occurring in the organism, and immediate adjustments take place to maintain homeostasis by means of two major outputs: first, neural signals to the autonomic nervous system; and second, endocrine signals working through the hypothalamic-pituitary axis.

The lateral hypothalamus projects onto cells that control the autonomic systems located in the medulla. These include the parasympathetic vagal nuclei and a group of cells that descend to the sympathetic system in the spinal cord. Thus the physiological functions of heart rate and force of contraction; constriction and dilation of blood vessels; contraction and relaxation of smooth muscles in various organs; visual accommodation and pupil size; and secretions from exocrine and endocrine glands (i.e., digestion, lacrimation, sweating) are all also influenced by the hypothalamus.[7]

The master coordinator of hormonal endocrine activity in mammals is the hypothalamus. Large hypothalamic neurons positioned around the third ventricle send their axons directly to the neurohypophysis, where the nerve terminals release oxytocin and vasopressin into the bloodstream. Smaller neurons located all over the hypothalamus send their axons to the median eminence in the medial basal hypothalamus, where they discharge releasing factors [corticotropin-releasing hormone (CRH), gonadotropin-releasing hormone (GnRH), growth hormone-releasing hormone (GHRH), thyrotropin-releasing hormone (TRH)] and inhibiting factors (dopamine, somatostatin) into the hypophyseal portal capillary. This specialized system of vessels connects the base of the hypothalamus with the anterior pituitary gland in order to regulate the secretion of hormones such as ACTH, TSH, LH, FSH, and GH. In contrast, inhibiting factors, such as dopamine and somatostatin, cause a strong inhibition of prolactin (PRL) and GH secretions, respectively.[7,13,14]

The hormonal effects vary widely, including stimulation or inhibition of growth; regulation of the metabolism; preparation for a new activity (e.g. fighting, fleeing, or mating); preparation for a new phase of life (e.g. puberty, caring for offspring, menopause); controlling the reproductive cycle; induction or suppression of apoptosis; activation or inhibition of the immune system, among others.[7]

FUNCTIONAL ANATOMY

The hypothalamus (from the Greek *hypo*, meaning "below" and *thalamus*, meaning "bed") is located at the base of the brain, in the diencephalon, in an anteroventral position in relation to the thalamus and above the sella turcica and pituitary. The dimensions of the hypothalamus are 1.5 cm in height, 1.5 cm in the antero-posterior length and 1.3 cm in width. Its weight varies from 2.5 to 5 g, considering a human brain of 1,200-1,300 g.[13,14]

It also forms the roof, lateral walls and floor of the third ventricle. The anatomical limits of the hypothalamus are: anteriorly, the rostral border of the optic chiasm and lamina terminalis; caudally, the posterior border of mamillary nuclei; and rostrally and posteriorly, the thalamus and the hypothalamic sulcus. The lateral boundaries are less clear, varying with the level studied, including the optic tract, internal capsule, *pes pedunculi*, *globus pallidus*, *ansa lenticularis* and the subthalamic region.[13,14] Because the boundaries between these areas are disputable, in anatomy, it has been conventioned to use a coronal plane at the level of mammillary bodies to separate the hypothalamus, anteriorly, from the subthalamic region, just behind.[15]

The hypothalamic region includes the tuber cinereum, the infundibulum, the optic chiasm, mammillary bodies and the neurohypophysis. There are two major tracts in the hypothalamus: (1) the mamillothalamic tract (bundle of Vicq d'Azyr), which emerges from the medial and lateral mamillary nuclei, passing dorsally, and terminates at the anterior thalamic nuclei. At the beginning, it forms a well-defined bundle

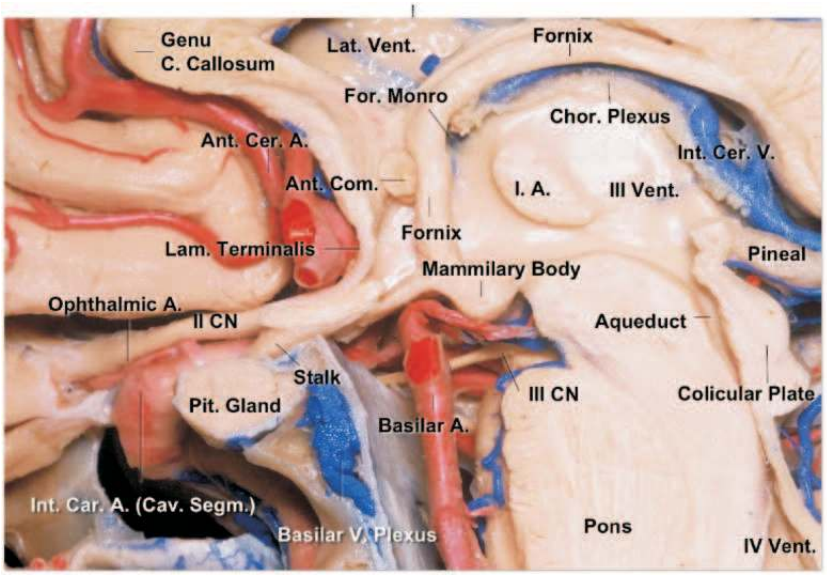

Figure 1. The hypothalamus and its neighborhood. Dissection of a silicone-injected cadaveric head has been performed at George Colter International Microsurgical Lab - University of Florida, Gainesville. A sagittal cut through the head has been made and dissection with preservation of the retrocomissural fornix has been undertaken. The path of the left column of fornix can be followed down to the mammillary body. From the mammillary body, a fiber tract passes up along the lateral wall of the ventricle to the anterior nuclei of thalamus: the mammilothalamic tract - involved in the circuitry of recent memory acquisition. The septum has been removed to expose the right lateral ventricle cavity. The topographic limits of the hypothalamus are arbitrary. Anatomically, the hypothalamus is defined as the area including the lateral walls of the third ventricle in front of a coronal plane passing posterior to the mammillary bodies. The anterior limit of this area is the anterior limit of the third ventricle and is formed by the lamina terminalis. The hypothalamic sulcus can be seen as a groove on the lateral wall of the third ventricle, between the foramen of Monro and the cerebral aqueduct. The hypothalamic sulcus is used as a landmark to divide the diencephalon. Posterior to the sulcus is the pars dorsalis (dorsal thalamus and epithalamus), while anterior to the hypothalamic sulcus is the pars ventralis (hypothalamus and subthalamus). Above the hypothalamic sulcus the walls of the third ventricle are united in 2/3 of the human brains by the interthalamic adhesion, a portion of gray matter that signals the location of the medial nuclei of thalamus.
A.: Artery, Ant.: Anterior, I. A.: Interthalamic Adhesion, C.: Corpus, Car.: Carotid, Cav.: Cavernous, Cer.: Cerebral, Chor.: Choroid, Com.: Commissure,, C.N.: Cranial Nerve, For.: Foramen, Int.: Internal, Lam.: Lamina, Lat.: Lateral, Pit.: Pituitary, Segm.: Segment, V.: Vein, Venous, Vent.: Ventricle.

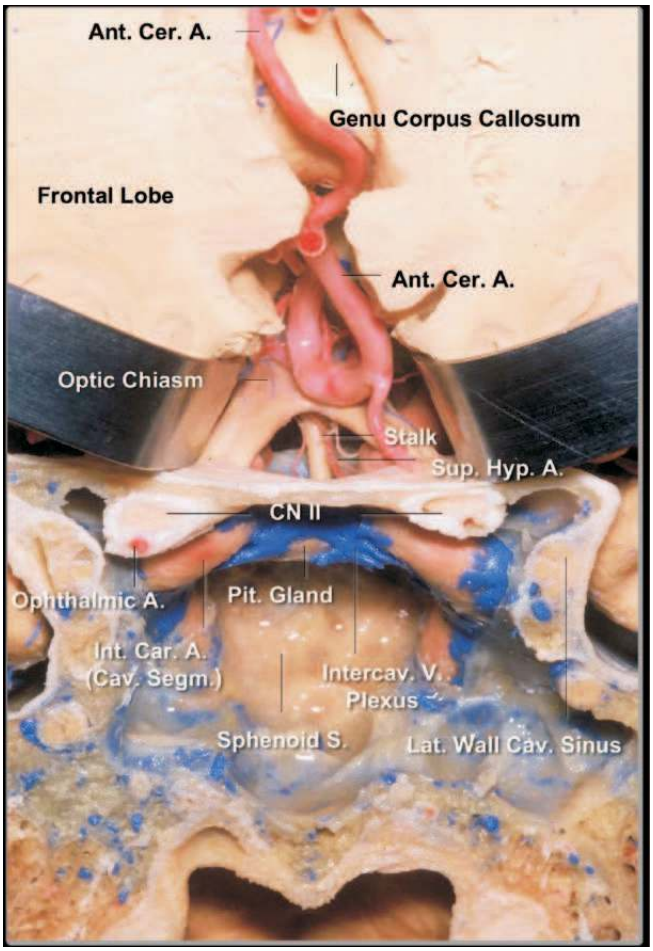

Figure 2 A. Superior panel.

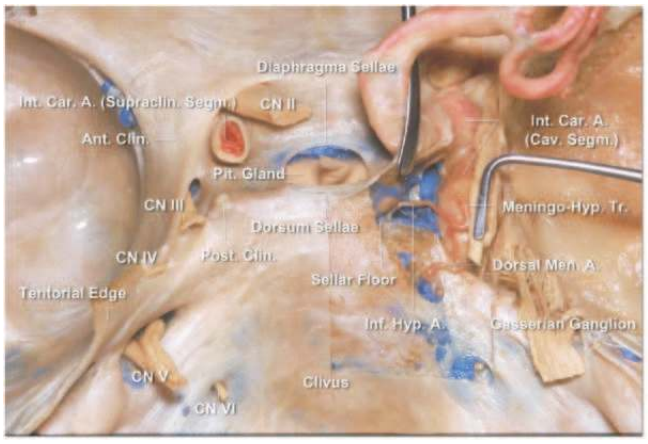

Figure 2 B. Inferior panel.

Figure 2. The sella turcica, infundibular stalk and optic quiasm. Dissection of a silicone-injected cadaveric head has been performed at George Colter International Microsurgical Lab - University of Florida, Gainesville. A – Superior panel, anterior view of the optic quiasm and infundibular stalk. B – Inferior panel, superior view of the sella turcica, optic nerve, infundibular stalk, and neighborhood. This region is very sensitive to stimuli that are painful, such as unruptured cerebral aneurysms, pituitary adenomas, etc.

known as the principal mamillary bundle (*fasciculus mamillaris princeps*). This bundle passes dorsally for a short distance before dividing into two components: the mamillothalamic tract (the larger) and the mamillotegmental tract (the smaller); and (2) the postcommissural fornix. The postcommissural fornix extends from the fornical column, continues behind the anterior commissure to reach the mamillary body. The fornix group fibers connect the hippocampus to the mammillary body. It is divided into fimbriae, crura, commissure, body and columns. The columns, at the level of the anterior commissure, divide into pre- and postcommisural fibers. The former projects fibers to the septal, lateral preoptic, diagonal and anterior hypothalamic nuclei.[13,14] The Figures 1 and 2 show the anatomy of the hypothalamic region and its neighborhood, using silicone-injected cadaveric head.

Using the MRI scan in a sagittal view we can delineate the hypothalamus using "imaginary lines" described by Saleem et al.[16] The anterior boundary of the hypothalamus, a "line" that extends from the anterior commissure to the optic chiasm, corresponds to the lamina terminalis. The posterior boundary, would extend from the mamillary bodies to the posterior commissure (it is imprecise because the hypothalamus blends into the mesencephalic tegmentum) (Figures 3 and 4).

Superiorly the hypothalamic sulcus separates the hypothalamus from the thalamus. The hypothalamic sulcus extends from the interventricular foramen to the cranial opening of the aqueduct. This sulcus is the remnant in the adult of the sulcus limitans of the early development of the neural tube. The sulcus limitans divides the neural tube into a ventral lamina or basal plate – which will eventually originate the motor nuclei of spinal cord and brainstem – and a dorsal lamina or alar plate, that will differentiate into input receiving structures.[15] Another practical way to limit the hypothalamus from the thalamus in radiological images is to draw a line between the anterior commissure and the posterior commissure.[16]

Inferiorly, the hypothalamus presents the *tuber cinereum*. This is a tubular structure composed of gray matter and lies between the two mamillary bodies (posteriorly) and the optic chiasm (anteriorly). The lateral boundary of the hypothalamus is, in its superior part, the medial thalamus. The median eminence or infundibulum is a small prominence in the tuber cinereum, formed by third ventricle floor that continues downward to form the infundibular stalk. The infundibular stalk is connected to the posterior lobe of the pituitary gland (Figures 3 and 4).[13,14,16]

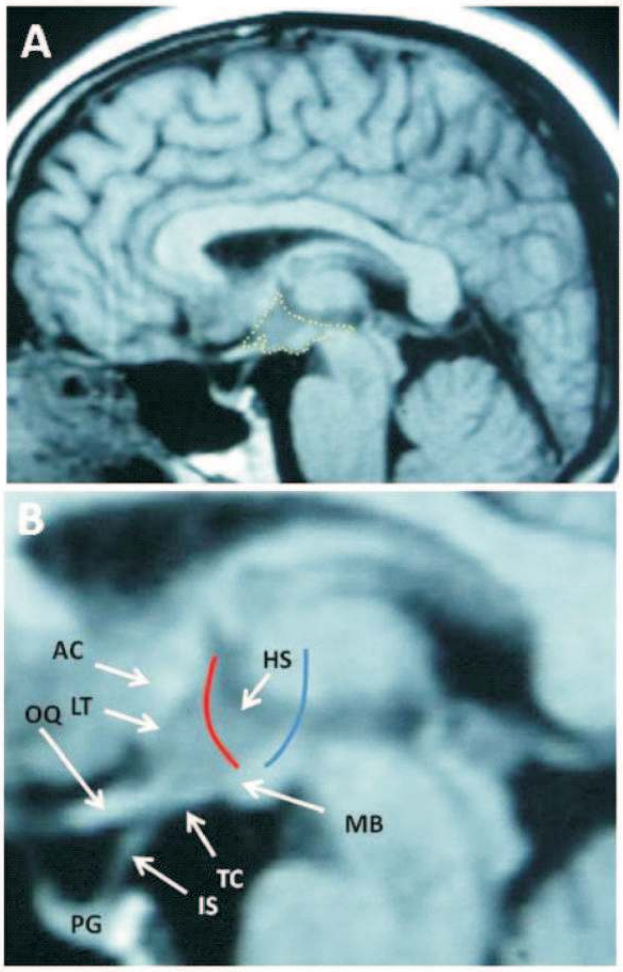

Figure 3. A – MRI scan (T1-weighted sagittal cut, 54-year-old woman) showing the hypothalamic region (dashed line), based on Saleem and colleagues.[16] B – MRI scan showing the different areas visualized in the hypothalamic region. AC, anterior commissure; LT, lamina terminalis; OQ, optic quiasm; IS, infundibular stalk; PG, pituitary gland; TC, tuber cinereum; MB, mamillary body; HS, hypothalamic sulcus; red line, postcommissural fornix; blue line, mamillothalamic tract. The high-signal-intensity area in the posterior part of the sella turcica is the posterior pituitary gland.

Cell proliferation in the posterior lobe and sprouting of hypothalamic nerve fibers in humans result in closure of infundibular recess – the path between the third ventricle and the posterior lobe of the gland – kept naturally opened in other mammals (e.g. cat). In conditions of high ventricular pressure (e.g. hydrocephalus), the infundibular recess can become patent. In this situation, the reddish rue of the gland can be seen from inside the ventricle and might be a cause of disorientation during endoscopic ventriculostomies.[17,18]

Several nuclei and fiber tracts are arranged symmetrically in the hypothalami, into the floor and lower medial surface of the third ventricle. To better identify the

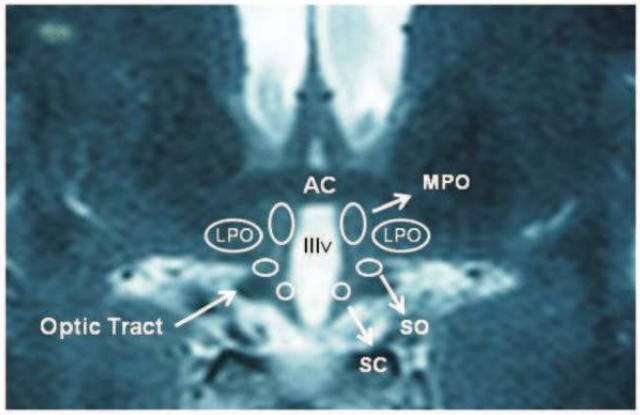

Figure 4. MRI scan (T1-weighted coronal plane, 17-year-old girl four years after surgical removal of a craniopharyngioma) showing the different positions of the hypothalamic nuclei, based on Saleem and colleagues.[16] AC, anterior commissure; LPO, lateral preoptic nucleus; SC, suprachiasmatic nucleus; SO, supraoptic nucleus; MPO, medial preoptic nucleus.

intrahypothalamic structures two imaginary axes are used, the medial-lateral and the rostral-caudal axes. The lateral and medial areas of the hypothalamus are separated by the medial-lateral axis. The rostral-caudal axis subdivides the hypothalamus into three regions: anterior, tuberal, and posterior.[16]

In the proximity of the hypothalamus there are the optic nerves that ascend from the skull base toward the chiasm at an angle of approximately 45 degrees with the nasotuberculum line; the intracranial segment of the optic nerve is 17 ± 2.4 mm in length, and the optic chiasm sits about 10.7 ± 2.4 mm above the dorsum of the *sella turcica*.[19]

ROLE OF THE HYPOTHALAMUS ON THE HEADACHE PATHOPHYSIOLOGY

Trigeminal autonomic headaches

The clinical manifestation of hemicrania continua overlaps with that of other trigeminal autonomic headaches and migraine, and activations observed in the hypothalamus and dorsal rostral pons, respectively, appear to play an important pathophysiological role.[1,2,20-23] Functional brain imaging has demonstrated significant activation of the ipsilateral dorsal rostral pons in association with the headache attacks of hemicrania continua.[20,21] There was also a significant activation of the contralateral posterior hypothalamus and ipsilateral ventrolateral midbrain, which extended over the red nucleus, the substantia nigra and the pontomedullary junction. The distinction between two

headache subtypes is that the ipsilateral hypothalamus mediates cluster headache, while the contralateral hypothalamus mediates hemicrania continua.

Proton MR spectroscopy of subjects with cluster headache showed a reduction in the NAA marker of neuronal integrity.[10,11] These results were confirmed by Wang et al.,[11] who also found a decrease in the Cho/Cr metabolite ratio, both during and between episodes. This suggests that both neuronal dysfunction and changes in the membrane lipids occur in the hypothalamus in cluster headache patients.

During the last decade more than 50 patients with refractory chronic cluster headache received neurostimulation of the posteroinferior hypothalamus as a form of treatment.[24] Clinical use of deep brain stimulation (DBS) was based on the theory of posterior hypothalamic nucleus dysfunction as the cause of cluster headache attacks.[1,2,10,11,20-22]

In a recent publication Seijo and colleagues[24] implanted five patients with a tetrapolar electrode (always ipsilateral to the pain side) into the hypothalamus, using the stereotaxic coordinates of 4 mm lateral to the third ventricle wall, 2 mm behind the midintercommissural point and 5 mm under the intercommissural line. An improvement of the headache was obtained in all patients. The authors postulated that the stimulated brain area included a lateral hypothalamic area (LHA) and the fasciculi mammillotegmentalis (FMTG), mammillothalamicus (FMTH) and medialis telencephali (FMTL) or medial forebrain bundle.[24]

As a result of stimulation (target of a brain volume of approximately 3 mm in radius) persistent myosis and euphoria/well-being feeling were observed in 3 subjects. Occasional dizziness (n=3), blurring vision/diplopia (n=2), concentration difficulties (n=1), cervical dystonia (n=1), generalized headache (n=1) and increase in appetite (n=1) were symptoms transiently induced.[24]

The "calming effect" was observed in three subjects.[24] In this regard, Sano and coworkers[25] reported their experience with hypothalamic stimulation and lesion in order to treat 51 patients with aggressive behavior. An increase in blood pressure, tachycardia, and maximal pupillary dilatation were provoked after stimulation in the posteromedial hypothalamus (more than 1 mm and less than 5 mm lateral to the lateral wall of the third ventricle), a triangular area (ergotropic triangle) formed by the midpoint of the intercommissural line, the rostral end of the aqueduct, and the anterior border of the mammillary body. Sano et al.[25] reported that sympathetic or parasympathetic responses would depend on the region of hypothalamic stimulation: an internal area of 0-1 mm that has parasympathetic responses; a medial area of 1-5 mm that has sympathetic responses; a lateral area of >5 mm, parasympathetic responses; and 3 mm under the midintercommissural point and 5 mm from the lateral wall of the third ventricle, parasympathetic responses.

Electrical stimulation of this ergotropic triangle resulted in desynchronization of the electroencephalogram (EEG) with hippocampal theta waves, or diffuse irregular delta waves of high voltage, demonstrating that the hypothalamus may regulate the cerebral cortex as well.[25]

Interestingly, in the series of patients of Seijo and colleagues[24] two typical cluster headache attacks were triggered on the contralateral side after the performance of the procedure in a 48-year-old woman. This is an unquestionable indication that abnormalities in the hypothalamus can induce cluster headache. Another interesting fact was that all individuals were painfree up to 2 weeks after the implantation of the DBS in the absence of electrical stimulation. Probably related to a local microlesion or a neuronal shock.[24]

In another series, Fontaine and colleagues[26] studied 10 patients with refractory chronic cluster headache who were implanted with DBS electrodes located in the posterior and ventral wall of the third ventricle (theoretical target 2 mm lateral to the midline, 3 mm posterior and 5 mm below the mid-commissural point). All of electrodes were posterior to the mamillary body and the mamillothalamic tract, at the diencephalo-mesencephalic junction tract (retro-mamillary posterior hypothalamus?). In the 5 responder patients the electrodes were in the proximity of the following structures: grey mesencephalic substance (5/5), red nucleus (4/5, superficial; 3/5 core), fascicle retroflexus (4/5), fascicle longitudinal dorsal (3/5), nucleus of ansa lenticularis (3/5), fascicle longitudinal medial (1/5) and the thalamus superficial medial (1/5), suggesting a participation of some of these anatomical structures. They admitted two possibilities to explain the pain relief effect: a direct stimulation on a local cluster headache generator, or through activation of an anti-nocioceptive systems. Since there is a latent period after the onset of DBS, neuroplastic mechanisms seem to play a role.

Migraine

A disruption in the normal function of the hypothalamus is implicated in the genesis of some prodromal symptoms

and signs of migraine, such as mood changes, drowsiness, thirst, craving for food, and yawning.[7]

Some of the migraine prodromal symptoms are controlled by the limbic system.[27] In a study involving 97 patients, premonitory symptoms predicted migraine attacks in 72%.[28] The most common premonitory symptoms were feeling tired and weary, observed in 72% of attacks with warning features, followed by difficulty in concentrating (51%) and a stiff neck (50%). These signs and symptoms may occur over several hours, or for even as long as 2 days, before the onset of pain.

During spontaneous migraine attacks activation of the hypothalamus is shown by positron emission tomography scanning.[3] During the headache Denuelle and coworkers[3] reported significant activations in the hypothalamus, midbrain and pons that persists after headache relief by sumatriptan treatment. A theory explaining the relationship between the hypothalamus and migraine attacks is that the joint effect of several migraine triggers may cause temporary hypothalamic dysfunction and this will result in a migraine attack.[4]

Furthermore, some of the hypothalamic peptides appear to be involved in the physiopathology of migraine.[7] Acute migraine headache attack can be relieved by intravenous oxytocin administration.[29] In addition, a lactational headache was attributed to oxytocin surges in association with the milk-ejection reflex.[30] A case of a woman suffering from brief attacks of headache that happened on every occasion of nursing was reported.[30] On the other hand, another case was described when the apparent headache trigger was breast overfulness, and not the oxytocin surge.[31] In this case the headaches were alleviated by putting the baby to the breast by the activation of the milk-ejection reflex.[31]

Another indication that the hypothalamus is involved during a migraine attack is the report of 6 subjects with a history of increased urinary frequency during migraine episodes.[32] An evident diuresis and natriuresis occurred within 12 hours of the onset of the headache, associated with a significant decrease in urinary arginine vasopressin.

Intracranial lesions in the hypothalamic region and its neighborhood (e.g. cerebral aneurysm and pituitary adenomas)[33,34] may trigger headache with similar features to those encountered in primary headaches. Figure 5 shows an MRI scan of a man with a recent history of headache caused by a hypothalamic cystic tumor.

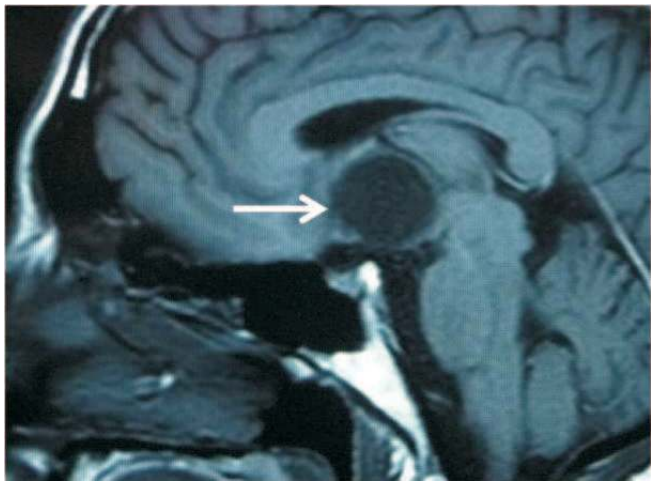

Figure 5. The MRI scan (T1-weighted sagittal cut) of a 44-year-old man with a 3-month history of headache, visual acuity decline, hypothyroidsm and sexual impotence. The arrow shows a cystic hypothalamic tumor.

CONCLUSION

In conclusion, a more thorough understanding of the functional anatomy of the hypothalamus and its neighborhood is imperative for understanding the physiopathology of several of the primary headaches, particularly migraine and the trigemino-autonomic headaches. Direct stimulation of the posterior hypothalamic region, using DBS devices, is now the "state of the art" form of treatment indicated for refractory chronic cluster headache. The exact mechanism and the actual region where the DBS may act are still unknown, and studies on the functional anatomy of the hypothalamus are crucial to the progress in this marvelous field of functional neurosurgery.

REFERENCES

1. Iacovelli E, Coppola G, Tinelli E, Pierelli F, Bianco F. Neuroimaging in cluster headache and other trigeminal autonomic cephalalgias. J Headache Pain. 2012;13(1):11-20.
2. Friberg L, Sandrini G, Perrotta A. Neuroimaging and clinical neurophysiology in cluster headache and trigeminal autonomic cephalalgias. Handb Clin Neurol. 2010;97:413-20.
3. Denuelle M, Fabre N, Payoux P, Chollet F, Geraud G. Hypothalamic activation in spontaneous migraine attacks. Headache. 2007;47(10):1418-26.
4. Alstadhaug KB. Migraine and the hypothalamus. Cephalalgia. 2009;29(8):809-17.
5. Peres MF, Sanchez del Rio M, Seabra ML, Tufik S, Abucham J, Cipolla-Neto J, et al. Hypothalamic involvement in chronic migraine. J Neurol Neurosurg Psychiatry. 2001;71(6):747-51.

6. Benjamin L, Levy MJ, Lasalandra MP, Knight YE, Akerman S, Classey JD, et al. Hypothalamic activation after stimulation of the superior sagittal sinus in the cat: a Fos study. Neurobiol Dis. 2004;16(3):500-5.
7. Prieto Peres MF, Valença MM. Headache endocrinological aspects. Handb Clin Neurol. 2010;97:717-37.
8. Peres MF, Valença MM, Gonçalves AL. Misdiagnosis of hemicrania continua. Expert Rev Neurother. 2009;9(9):1371-8.
9. Valença MM, Medeiros FL, Martins HA, Massaud RM, Peres MF. Neuroendocrine dysfunction in fibromyalgia and migraine. Curr Pain Headache Rep. 2009;13(5):358-64.
10. Lodi R, Pierangeli G, Tonon C, Cevoli S, Testa C, Bivona G, et al. Study of hypothalamic metabolism in cluster headache by proton MR spectroscopy. Neurology. 2006;66(8):1264-6.
11. Wang SJ, Lirng JF, Fuh JL, Chen JJ. Reduction in hypothalamic 1H-MRS metabolite ratios in patients with cluster headache. J Neurol Neurosurg Psychiatry .2006;77(5):622-5.
12. Montagna P (2006). Hypothalamus, sleep and headaches. Neurol Sci. 2006;27 (Suppl 2):S138-43.
13. Valenca MM, Martins MC, Antunes-Rodrigues J. Anatomia e embriologia do hipotálamo e da glândula pituitária. In: José Antunes-Rodrigues, Ayrton Moreira, Margarete Castro, Lucy Elias, Eds. Neuroendocrinologia Básica e Aplicada. Rio de Janeiro, 2004, p. 41-51
14. Valença MM, Ellias LLK, Elias PCL, et al. Anatomia e fisiologia do hipotálamo e da glândula pituitária. In: Arthur Cuckier, Ed. Neuroendocrinologia Clínica e Cirúrgica. 2002, p. 21-71.
15. Gray's Anatomy. The Anatomical Basis of Clinical Practice. 31st Ed, 2005.
16. Saleem SN, Said AH, Lee DH. Lesions of the hypothalamus: MR imaging diagnostic features. Radiographics. 2007;27(4):1087-108.
17. Cabanes J. Asymptomatic persistence of infundibularis recessus. Case report. J Neurosurg. 1978;49(5):769-72.
18. Kuhne D, Schwartz RB. Persisting intrapituitary recessus infundibuli. Neuroradiology. 1975;10(3):177-8.
19. Hayreh SS. Anatomy and physiology of the optic nerve head. Trans Am Acad Ophthalmol Otolaryngol. 1974;78(2): OP240-54
20. Matharu MS, Goadsby PJ. Functional brain imaging in hemicrania continua: implications for nosology and pathophysiology. Curr Pain Headache Rep. 2005;99(4): 281-8.
21. Matharu MS, Cohen AS, McGonigle DJ, Ward N, Frackowiak RS, Goadsby PJ. Posterior hypothalamic and brainstem activation in hemicranias continua. Headache. 2004;44(8):747-61.
22. May A, Bahra A, Büchel C, Frackowiak RS, Goadsby PJ. Hypothalamic activation in cluster headache attacks. Lancet. 1998;352(9124):275-8. Comment in: Lancet.1998;352 (9124):253-5.
23. Valença MM, Andrade-Valença LP, da Silva WF, Dodick DW. Hemicrania continua secondary to an ipsilateral brainstem lesion. Headache. 2007;47(3):438-41.
24. Seijo F, Saiz A, Lozano B, Santamarta E, Alvarez-Vega M, Seijo E, Fernández de León R, et al. Neuromodulation of the posterolateral hypothalamus for the treatment of chronic refractory cluster headache: Experience in five patients with a modified anatomical target. Cephalalgia. 2011;31(16): 1634-41.
25. Sano K, Mayanagi Y, Sekino H, Ogashiwa M, Ishijima B. Results of timulation and destruction of the posterior hypothalamus in man. J Neurosurg. 1970;33(6):689-707.
26. Fontaine D, Lanteri-Minet M, Ouchchane L, Lazorthes Y, Mertens P, Blond S, et al. Anatomical location of effective deep brain stimulation electrodes in chronic cluster headache. Brain. 2010;133(Pt 4):1214-23.
27. Raffaelli E Jr, Menon AD. Migraine and the limbic system. Headache. 1975;15(1): 69-78.
28. Giffin NJ, Ruggiero L, Lipton RB, Silberstein SD, Tvedskov JF, Olesen J, et al. Premonitory symptoms in migraine: an electronic diary study. Neurology. 2003. 60(6): 935-40.
29. Phillips WJ, Ostrovsky O, Galli RL, Dickey S. Relief of acute migraine headache with intravenous oxytocin: report of two cases. J Pain Palliat Care Pharmacother. 2006;20(3):25-8.
30. Askmark H, Lundberg PO. Lactation headache - a new form of headache? Cephalalgia 1989; 9(2):119-22.
31. Thorley V. Lactational headache: a lactation consultant's diary. J Hum Lact. 1997;13(1):51-3.
32. Poole CJ, Lightman SL. Inhibition of vasopressin secretion during migraine. J Neurol Neurosurg Psychiatry. 1988;51(11): 1441-4.
33. Valença MM, Andrade-Valença LP, Martins C, de Fátima Vasco Aragão M, Batista LL, Peres MF, et al. Cluster headache and intracranial aneurysm. J Headache Pain. 2007;8(5):277-82.
34. Andrade-Valenca LP, Dodick D, Valenca MM. Alarm bell headache: a sinister secondary headache. Cephalalgia. 2007; 27:715.

Received: 11/23/2011
Accepted: 12/20/2011

Correspondence
Marcelo M. Valença, MD
Neurology and Neurosurgery Unit,
Department of Neuropsychiatry
Universisdade Federal de Pernambuco
50670-420 – Recife, PE, Brazil
mmvalenca@yahoo.com.br