Headache Medicine 2026, 17(2):165-173 ▪ p-ISSN 2178-7468, e-ISSN 2763-6178

Headache Medicine

DOI: 10.48208/HeadacheMed.2026.21

Review

Anatomy of the vagus nerve and its systemic connections: a narrative review of the literature

Izabela Millery da Silva Cruz, Helena Renata Silva Cysneiros, Jaqueline Severo dos Santos, Emanuel Roger dos Santos Reis, Anna Xênya Patrício de Araújo, Marcelo Moraes Valença, Taciana Aline Maciel Bezerra Oliveira, Daniella Araújo de Oliveira

Federal University of Pernambuco, Recife, Pernambuco, Brazil

Izabela Millery da Silva Cruz
izabela.millery@ufpe.br

Edited by:
Juliana Ramos de Andrade

Abstract

Introduction
The vagus nerve is the longest cranial nerve in the human body and plays a crucial role in various functions related to the autonomic nervous system. It is involved in modulating inflammation, pain, and appetite, which makes the study of its anatomy and systemic connections particularly relevant.

Objective
To conduct a narrative review of the anatomy of the vagus nerve and its interactions with other systems in the body.

Methods
This is a narrative literature review based on a systematized search conducted on PubMed, Bireme (Lilacs), and Scopus databases, between August and September 2024, as well as consultation of relevant books.

Results
Of the 3,718 studies identified, 3 were selected. The findings suggest that the anatomy of the vagus nerve facilitates its interaction with various organs and systems, enabling its participation in numerous physiological processes essential to life maintenance. Vagal stimulation has emerged as a promising adjunctive treatment for various health conditions.

Conclusion
The vagus nerve is essential in regulating multiple physiological functions, integrating sensory and motor systems. Further studies on its anatomophysiology may help elucidate these complexes, yet not fully understood, processes. The literature suggests that vagal stimulation holds therapeutic potential for treating inflammatory diseases, pain conditions, and neuropsychiatric conditions. Additional research is necessary to fully explore its clinical implications and enhance treatment options for challenging conditions.

Keywords:
Anatomy
Anatomophysiology
Vagus nerve

Received: April 28, 2026
Revised: June 1st, 2026
Accepted: July 2nd, 2026

© Copyright 2025

Introduction

The vagus nerve is the tenth cranial nerve and has the longest anatomical course among the cranial nerves. Its name originates from Latin and means "the wandering nerve," and it is sometimes referred to as the "great wandering protector" (1,2). It consists of motor and sensory fibers that innervate structures such as the pharynx and larynx, with a predominant role in visceral innervation (3) and marked autonomic characteristics (2). Although vagal neurons constitute a relatively small portion of the nervous system, they regulate a broad range of vital physiological functions (4).

Vagal fibers perform distinct functions according to their conduction velocities and physiological roles. Type A fibers include Aα fibers, which convey somatic information related to touch, pain, and temperature; Aβ fibers, which transmit sensory input from muscles; and Aδ fibers, which carry visceral information associated with pain and temperature. β fibers are myelinated and are primarily involved in autonomic regulation. In contrast, unmyelinated C fibers transmit visceral sensory signals, including those related to pain and gastric distension, to the central nervous system.

The majority of vagal fibers (60–80%) are afferent C fibers, which play a key role in conveying sensory information from peripheral organs to the brain. Vagal efferent fibers are predominantly cholinergic but also include non-adrenergic, non-cholinergic fibers that release neurotransmitters such as nitric oxide and vasoactive intestinal peptide. Through these pathways, the vagus nerve contributes to homeostasis and modulates cardiovascular, respiratory, and gastrointestinal functions (5–7).

Given its involvement in processes that extend beyond interoception and classical autonomic control, the vagus nerve has become a major focus of scientific investigation. Current research seeks to clarify its functional organization and to understand how vagal modulation may influence the integrated activity of multiple physiological systems (8).

The vagus nerve is a major component of the autonomic nervous system, particularly the parasympathetic branch, and plays a central role in the regulation of inflammatory processes and autonomic functions. As an afferent pathway, it conveys information about the internal state of peripheral tissues to the central nervous system, enabling coordinated responses that involve multiple organ systems (9).

Vagal stimulation has been shown to reduce tissue injury and organ inflammation in inflammatory and infectious conditions (10,11). Accordingly, it has been investigated as an adjunctive therapeutic approach to modulate inflammatory responses (12) and to treat conditions such as migraine, epilepsy, arthritis, depression, and anxiety (13–16).

In this context, advancing knowledge of vagal anatomophysiology and its interactions with different systems of the human body is essential. Such understanding may support the development of novel clinical applications for vagal stimulation and foster new therapeutic strategies for conditions that remain difficult to manage. Therefore, the aim of this study is to examine the anatomy of the vagus nerve and its relationships with multiple body systems through a narrative review of the literature.

Methods

This study consists of a narrative literature review aimed at providing a comprehensive overview of the topic, without the requirement for a strictly rigorous or replicable methodology. The narrative review approach allows for the acquisition and updating of specialized knowledge in a given field (17). The review was based on a systematized search of the PubMed, Bireme (LILACS), and Scopus databases, conducted between August and September 2024. In addition, relevant textbooks and the reference lists of related articles were consulted.

The Medical Subject Headings (MeSH) terms and Boolean operators used in the search strategy were "vagus nerve AND anatomy OR anatomophysiology." When available, the following filters were applied: full-text availability, studies published within the last 10 years, research conducted in human subjects, and publications in English or Portuguese. Original or review articles addressing the anatomy and/or physiology of the vagus nerve, as well as its interactions with different body systems, were included. Case reports, letters to the editor, and animal studies were excluded. A total of 3.873 records were initially identified, of which three studies were ultimately included after duplicate removal and application of the inclusion criteria. Figure 1 illustrates the study selection process, and Table 1 summarizes the studies included in this review.

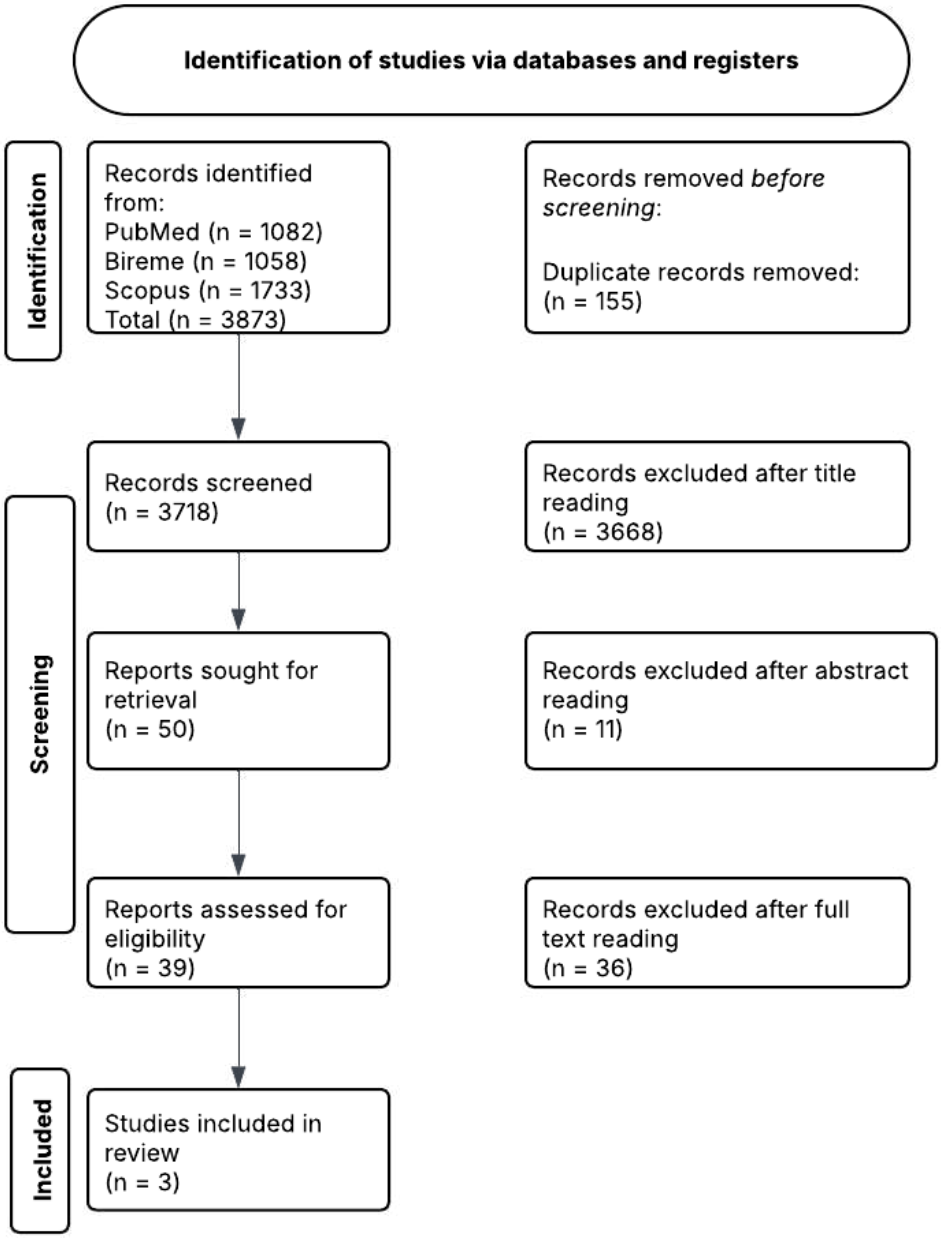

Figure 1. Flowchart of the publications' screening process.

Table 1. Publications included in this review

Authorship	Title	Year of publication
Neuhuber, Berthoud (8)	Functional anatomy of the vagus system: How does the polyvagal theory comply?	2022
Lucas Lucio, de Andrade Lourenção Freddi (18)	Glossopharyngeal, Vagus and Accessory Nerves: Anatomy and Pathology	2022
Prescott and colleagues (4)	Internal senses of the vagus nerve	2022

Results and discussion

Vagus nerve anatomy

The vagus nerve originates in the medulla oblongata just below the nucleus of the eleventh cranial nerve (accessory nerve) and emerges through the jugular foramen, sharing its neural sheath with the glossopharyngeal nerve (cranial nerve IX). It descends through the neck within the carotid sheath, positioned between the internal jugular vein and the carotid artery, reaching the superior portion of the thyroid cartilage, where it passes between the common carotid artery and vein as it continues along the neck (19).

The vagus nerve contains two sensory ganglia: the superior (jugular) ganglion, located in the jugular fossa of the temporal bone, and the inferior (nodose) ganglion, situated distal to the jugular foramen. The inferior ganglion gives rise to ten branches, including the cardiac, auricular, meningeal, gastrointestinal, esophageal, pulmonary, pharyngeal, and superior laryngeal branches (20). Within the vagal ganglia, the sensory neuron somata coexist with satellite glial cells, Schwann cells, endothelial cells, and immune cells (21).

The branches of the vagus nerve include the meningeal branch, which innervates the auricular region and the dura mater of the posterior cranial fossa (18). Other branches emerge distal to the jugular foramen, innervating the pharynx and larynx (20). The vagus also contributes to human phonation through both sensory and motor innervation of the larynx and plays a critical role in protecting the airways from injury caused by allergens, laryngopharyngeal reflux, and liquid aspiration by modulating the protective cough reflex (4).

The vagus nerve connects to four brainstem nuclei: the nucleus of the solitary tract, the nucleus ambiguus, the dorsal motor nucleus, and the spinal trigeminal nucleus (20). All vagal nuclei are influenced by serotonergic nuclei (raphe nuclei) and noradrenergic nuclei, particularly the pontine A5 group, within the brainstem (8).

A large proportion of vagal visceromotor preganglionic neurons are located in the dorsal motor nucleus, positioned between the nucleus of the solitary tract and the hypoglossal nerve nucleus (cranial nerve XII). These cholinergic neurons project throughout the spinal cord, targeting the colon, pancreatic ganglia, esophagus, and enteric nervous system (8).

After entering the abdomen as two trunks (dorsal and ventral), the vagal fibers divide into four or five primary branches at the subdiaphragmatic esophageal level: the ventral and dorsal gastric branches, the ventral and dorsal celiac branches, and a single hepatic branch arising from the ventral trunk (22).

The ventral gastric branch innervates the ventral stomach, the pyloric sphincter, and the proximal duodenum. The dorsal gastric branch enters near the cardia and supplies the dorsal stomach and proximal duodenum via transpyloric fibers. The ventral and dorsal celiac branches travel along the celiac artery and, near the celiac ganglia, distribute to the small intestine and proximal and distal colon, following the superior mesenteric artery. The common hepatic branch divides into the proper hepatic branch, which innervates the liver, and the gastroduodenal/pyloric branch, which supplies the gastric antrum, pylorus, duodenum, and pancreas. The gastric branches, comprising more than half of all abdominal vagal branches, regulate gastric acid secretion, while the hepatic branch modulates gallbladder and biliary tract motility, and distal intestinal and colonic motility is mediated by the celiac branches (23).

The vagus nerve is a mixed nerve, composed of approximately 80% afferent fibers and 20% efferent fibers (24). Its sensory afferent pathways originate from the posterior auricular region and the posteroinferior aspect of the external acoustic meatus, passing through the jugular foramen in close relation to the trigeminal region. Each vagal sensory neuron extends a single pseudounipolar axon projecting bidirectionally toward the cell body and the brain (4). The superior ganglion communicates with the petrosal and accessory nuclei, while the inferior ganglion communicates with the facial nerve and the cranial roots of the accessory nerve. Through the superior ganglion, somatic sensory information associated with the auricular branch is transmitted, whereas the inferior ganglion mediates gustatory and general visceral sensation. Gustatory and visceral afferents project to the nucleus of the solitary tract (20).

The efferent pathways are controlled via the lower portion of the precentral gyrus, descending through the corticobulbar tract to synapse with the nucleus ambiguus. These fibers innervate the musculature of the larynx, soft palate, and pharynx, giving rise to branchiomotor branches such as the superior laryngeal, recurrent laryngeal, and pharyngeal branches. The pharyngeal branch passes alongside the internal and external carotid arter-

ies to enter the pharynx, where it issues branches that form the pharyngeal plexus. The laryngeal branch is subdivided into an internal branch, which carries sensory fibers, and an external branch, which innervates the cricothyroid muscle. The remaining laryngeal muscles are innervated by the recurrent laryngeal nerve, with the exception of the arytenoid muscle (20,25).

Some parasympathetic fibers originate from the medulla, innervating visceral regions, while other branches arise near the nucleus ambiguus to innervate the heart. The parasympathetic pathways travel ventromedially to join the branchiomotor fibers, whereas autonomic fibers emerge from the craniosacral region of the medulla as preganglionic fibers, ultimately terminating in ganglia located near the target visceral organs and issuing short postganglionic fibers to various glands and smooth muscles (20).

Systemic connections of the vagus nerve

The CNS is responsible for regulating bodily homeostasis and maintaining the balance between the SNS and the PNS (9). Within the PNS, several cranial nerves are involved, including the glossopharyngeal, oculomotor, facial, and, most notably, the vagus nerve, which contains approximately 70% of parasympathetic fibers (26). The SNS and PNS have antagonistic functions: while the SNS mediates the "fight or flight" response and increases heart rate (HR), the PNS promotes "rest and digest" functions, reducing HR (26). The right vagus nerve innervates the sinoatrial node, which functions as the heart's pacemaker, whereas the left vagus nerve innervates the atrioventricular node, regulating cardiac contractile force (23).

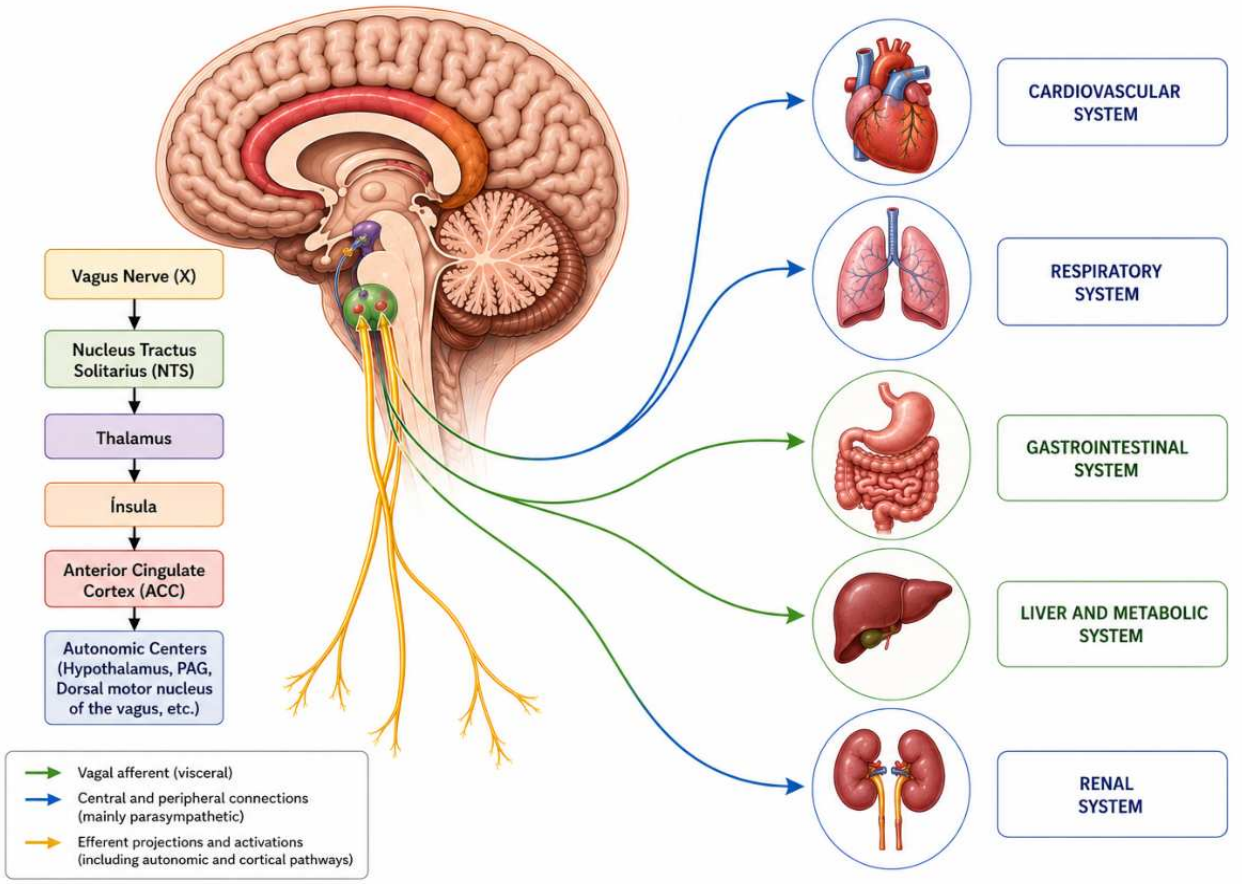

Figure 2. Vagus nerve and its systemic connections.

There is a direct and complex relationship between the CNS and the digestive system, consisting of a bidirectional pathway linking the central nervous system and the gastrointestinal system (GI): the brain-gut axis. This pathway is regulated directly via the vagus nerve and indirectly through hormones (cortisol), neurotransmitters (serotonin, dopamine, calcitonin gene-related peptide), and the gut microbiota itself (27). The vagus nerve integrates peripheral signals with central responses, allowing the brain to respond to changes in the GI system. This includes modulation of appetite and immune responses, linking gut health to overall well-being, and playing a crucial role in GI regulation through its extensive parasympathetic innervation, coordinating sensory and motor functions and influencing multiple aspects of GI physiology (28).

Regarding sensory functions, the vagus nerve transmits information from the GI tract to the CNS about gastric distension, chemical composition, and overall gut health, which are essential for regulating appetite and satiety. In terms of motor functions, it exerts both excitatory and inhibitory control over gastric, intestinal, and pancreatic activities. It stimulates digestive processes such as gastric acid secretion and peristalsis, while also modulating blood flow to the GI tract (28).

In addition to maintaining bodily homeostasis, visceral functions, pancreatic endocrine and exocrine secretion, gastrointestinal motility, and hepatic glucose production, the vagus nerve contributes to the inflammatory reflex. It modulates innate and adaptive immune responses in response to tissue injury or pathogenic agents (29). The vagus sends information about the body's inflammatory status to the brain, enabling the brain to coordinate immune responses that reduce excessive inflammation (9).

The vagus nerve modulates the inflammatory process through several pathways. Its efferent portion is associated with the cholinergic anti-inflammatory pathway, in which acetylcholine is released to inhibit the production of pro-inflammatory cytokines, and with the hypothalamic-pituitary-adrenal (HPA) axis pathway, which detects peripheral inflammatory signals and transmits them to the CNS. The CNS then recruits the HPA axis to release corticosteroids, which suppress systemic inflammation. The sympathetic pathway also contributes to inflammation control via C1 neurons, which activate sympathetic preganglionic neurons that, in turn, engage the splenic pathway. Activation of the splenic pathway leads to norepinephrine release, which binds to β2-adrenergic receptors, stimulating acetylcholine release and inhibiting tumor necrosis factor-alpha (TNF-α) production (30).

The vagus nerve has extensive connections with brain regions that are critical for pain processing, including the nucleus of the solitary tract, the periaqueductal gray (PAG), and the anterior cingulate cortex. Its stimulation can influence these areas, enhancing the brain's ability to modulate pain perception. The PAG is known to play a central role in descending pain modulation, and vagal activation exhibits both analgesic and anti-inflammatory properties (8,12,31).

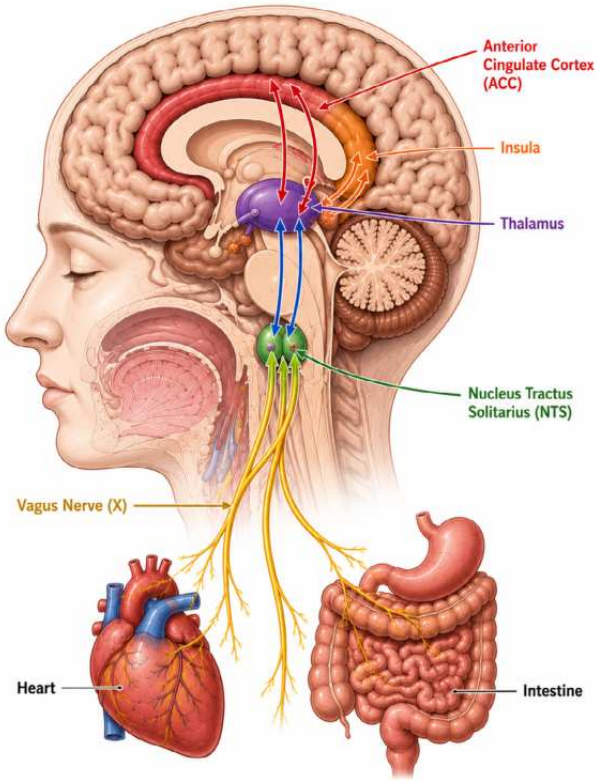

Figure 3. Vagus nerve and the anterior cingulate cortex.

These properties are associated with a reduction in pro-inflammatory cytokine levels and an increase in anti-inflammatory cytokine production as a result of vagal stimulation, which also activates descending pain inhibitory systems. These systems involve the release of neurotransmitters such as serotonin and norepinephrine, as well as interactions with the opioid system. Together, these mechanisms help alleviate pain perception and enhance treatment responses in chronic pain conditions (12). Furthermore, the anterior cingulate cortex (ACC) is an important brain structure that receives sensory information from the thalamus and projects sensory output to several brain regions, including the amygdala, periaqueductal gray (PAG), and motor cortex. The ACC is involved in the endogenous opioid system responsible for pain modulation and plays a key role in the integration of motivation, cognition, pain perception, and emotional processing. Its increased activation has been associated with the development and chronification of migraine. Moreover, because the ACC is interconnected with autonomic control centers, it can influence autonomic nervous system functions and contribute to the regulation of emotional responses. (32,33)

Therapeutic approaches to the vagus nerve

Vagus nerve stimulation is a therapeutic approach within neuromodulation aimed at optimizing CNS functionality. Due to its connections with the parasympathetic nervous system, the vagus nerve supports the maintenance of autonomic functions (34) and has potential applications in the management of conditions such as depression, stroke, epilepsy, obesity, and pain disorders, including migraine (35).

Vagal stimulation can be performed invasively or transcutaneously, most commonly using electrical signals, and is typically applied on the left side. This is because right-sided stimulation tends to produce a greater reduction in heart rate, due to the recruitment of more fibers and the fact that the right vagus innervates the sinoatrial node (23).

The invasive approach involves the use of an implantable device, consisting of an electrode wrapped around the left vagus nerve and an implantable pulse generator positioned below the clavicle, containing the battery and pulse generator. Electrode placement requires precise dissection of the vagus nerve relative to the carotid artery, making the procedure more complex and prone to complications (15).

In contrast, transcutaneous vagus nerve stimulation eliminates the need for a surgical procedure and is more accessible than invasive stimulation. It can be applied to specific regions of the external ear or the cervical branch of the vagus nerve. The impulses reach key brain nuclei, such as the nucleus of the solitary tract, activating the locus coeruleus (15,35). Vagal stimulation can also be achieved through deep breathing or vocalization, such as chanting "OM," practices commonly associated with yoga and meditation (36).

Conclusion

The vagus nerve plays a crucial role in regulating a wide range of physiological functions, integrating both sensory and motor systems. Advancing research on its anatomo-physiology can deepen the understanding of these intricate and not yet fully elucidated processes. Furthermore, literature suggests that vagus nerve stimulation, whether invasive or non-invasive, holds promise for the treatment of inflammatory diseases, pain conditions, and neuropsychiatric disorders. Additional studies are needed to clarify the clinical implications of vagal stimulation, with the aim of expanding scientific knowledge and improving therapeutic options for conditions that are difficult to manage.

References

1. Browning KN, Verheijden S, Boeckxstaens GE. The Vagus Nerve in Appetite Regulation, Mood, and Intestinal Inflammation. Gastroenterology 2017;152:730–44. Doi:10.1053/j.gastro.2016.10.046.
2. Cunningham CJ, Martínez JL. The Wandering Nerve: Positional Variations of the Cervical Vagus Nerve and Neurosurgical Implications. World Neurosurg 2021;156:105–10. Doi:10.1016/j.wneu.2021.09.090.
3. Machado Â, Haertel LM. Neuroanatomia funcional. 3rd ed. Atheneu; 2013.
4. Prescott SL, Liberles SD. Internal senses of the vagus nerve. Neuron 2022;110:579–99. Doi:10.1016/j.neuron.2021.12.020.
5. Craig A. Interoception: the sense of the physiological condition of the body. Curr Opin Neurobiol 2003;13:500–5. Doi:10.1016/S0959-4388(03)00090-4.
6. Dockray GJ. Enteroendocrine cell signalling via the vagus nerve. Curr Opin Pharmacol 2013;13:954–8. Doi:10.1016/j.coph.2013.09.007.
7. Ruffoli R, Giorgi FS, Pizzanelli C, Murri L, Paparelli A, Fornai F. The chemical neuroanatomy of vagus nerve stimulation. J Chem Neuroanat 2011;42:288–96. Doi:10.1016/j.jchemneu.2010.12.002.
8. Neuhuber WL, Berthoud H-R. Functional anatomy of the vagus system: How does the polyvagal theory comply? Biol Psychol 2022;174. Doi:10.1016/j.biopsycho.2022.108425.
9. Cerritelli F, Frasch MG, Antonelli MC, Viglione C, Vecchi S, Chiera M, et al. A Review on the Vagus Nerve and Autonomic Nervous System During Fetal Development: Searching for Critical Windows. Front Neurosci 2021;15. Doi:10.3389/fnins.2021.721605.
10. Courties A, Berenbaum F, Sellam J. Vagus nerve stimulation in musculoskeletal diseases. Joint Bone Spine 2021;88. Doi:10.1016/j.jbspin.2021.105149.
11. Bassi GS, Kanashiro A, Coimbra NC, Terrando N, Maixner W, Ulloa L. Anatomical and clinical implications of vagal modulation of the spleen. Neurosci Biobehav Rev 2020;112:363–73. Doi:10.1016/j.neubiorev.2020.02.011.
12. Shao P, Li H, Jiang J, Guan Y, Chen X, Wang Y. Role of Vagus Nerve Stimulation in the Treatment of Chronic Pain. Neuroimmunomodulation 2023;30:167–83. Doi:10.1159/000531626.
13. Thompson N, Mastitskaya S, Holder D. Avoiding off-target effects in electrical stimulation of the cervical vagus nerve:

Neuroanatomical tracing techniques to study fascicular anatomy of the vagus nerve. J Neurosci Methods 2019;325. Doi:10.1016/j.jneumeth.2019.108325.
14. Zhu Y, Xu F, Lu D, Rong P, Cheng J, Li M, et al. Transcutaneous auricular vagal nerve stimulation improves functional dyspepsia by enhancing vagal efferent activity. American Journal of Physiology-Gastrointestinal and Liver Physiology 2021;320:700–11. Doi:10.1152/ajpgi.00426.2020.
15. Yap JYY, Keatch C, Lambert E, Woods W, Stoddart PR, Kameneva T. Critical Review of Transcutaneous Vagus Nerve Stimulation: Challenges for Translation to Clinical Practice. Front Neurosci 2020;14. Doi:10.3389/fnins.2020.00284.
16. Zhang L, Hall M, Lam SK. Hospital costs associated with vagus nerve stimulation and medical treatment in pediatric patients with refractory epilepsy. Epilepsia 2022;63:1141–51. Doi:10.1111/epi.17208.
17. Vosgerau DSR, Romanowski JP. Estudos de revisão: implicações conceituais e metodológicas. Revista Diálogo Educacional 2014;14. Doi:10.7213/dialogo.educ.14.041.DS08.
18. Sarrazin J-L, Toulgoat F, Benoudiba F. The lower cranial nerves: IX, X, XI, XII. Diagn Interv Imaging 2013;94:1051–62. Doi:10.1016/j.diii.2013.06.013.
19. Campbell WW, Barohn RJ. Dejong O Exame Neurológico. 8th ed. Rio de Janeiro: Guanabara Koogan; 2021.
20. Waise TMZ, Dranse HJ, Lam TKT. The metabolic role of vagal afferent innervation. Nat Rev Gastroenterol Hepatol 2018;15:625–36. Doi:10.1038/s41575-018-0062-1.
21. Lucio LL, Freddi T de AL. Glossopharyngeal, Vagus and Accessory Nerves: Anatomy and Pathology. Seminars in Ultrasound, CT and MRI 2023;44:95–103. Doi:10.1053/j.sult.2022.11.003.
22. Berthoud H-R, Neuhuber WL. Functional and chemical anatomy of the afferent vagal system. Autonomic Neuroscience 2000;85:1–17. Doi:10.1016/S1566-0702(00)00215-0.
23. Bonaz B, Picq C, Sinniger V, Mayol JF, Clarençon D. Vagus nerve stimulation: from epilepsy to the cholinergic anti-inflammatory pathway. Neurogastroenterology & Motility 2013;25:208–21. Doi:10.1111/nmo.12076.
24. Butt MF, Albusoda A, Farmer AD, Aziz Q. The anatomical basis for transcutaneous auricular vagus nerve stimulation. J Anat 2020;236:588–611. Doi:10.1111/joa.13122.
25. Simon É, Mertens P. Anatomie fonctionnelle des nerfs glossopharyngien, vague, accessoire et hypoglosse. Neurochirurgie 2009;55:132–5. Doi:10.1016/j.neuchi.2009.01.018.
26. Tindle J, Tadi P. Neuroanatomy, Parasympathetic Nervous System. 2022.
27. Papassidero P. Enxaqueca e a Alimentação: Nunca mais seja refém da comida. SOS Enxaqueca; 2022.
28. Browning KN, Travagli RA. Central Nervous System Control of Gastrointestinal Motility and Secretion and Modulation of Gastrointestinal Functions. Compr. Physiol., Wiley; 2014, p. 1339–68. Doi:10.1002/cphy.c130055.
29. Pavlov VA, Tracey KJ. The vagus nerve and the inflammatory reflex—linking immunity and metabolism. Nat Rev Endocrinol 2012;8:743–54. Doi:10.1038/nrendo.2012.189.
30. Cheng J, Shen H, Chowdhury R, Abdi T, Selaru F, Chen JDZ. Potential of Electrical Neuromodulation for Inflammatory Bowel Disease. Inflamm Bowel Dis 2020;26:1119–30. Doi:10.1093/ibd/izz289.
31. Chakravarthy K, Chaudhry H, Williams K, Christo PJ. Review of the Uses of Vagal Nerve Stimulation in Chronic Pain Management. Curr Pain Headache Rep 2015;19. Doi:10.1007/s11916-015-0528-6.
32. Breit S, Kupferberg A, Rogler G, Hasler G. Vagus Nerve as Modulator of the Brain–Gut Axis in Psychiatric and Inflammatory Disorders. Front Psychiatry 2018;9. Doi:10.3389/fpsyt.2018.00044.
33. Dai W, Liu R-H, Qiu E, Liu Y, Chen Z, Chen X, et al. Cortical mechanisms in migraine. Mol Pain 2021;17. Doi:10.1177/17448069211050246.
34. Zou N, Zhou Q, Zhang Y, Xin C, Wang Y, Claire-Marie R, et al. Transcutaneous auricular vagus nerve stimulation as a novel therapy connecting the central and peripheral systems: a review. International Journal of Surgery 2024;110:4993–5006. Doi:10.1097/JS9.0000000000001592.
35. Hilz MJ. Transcutaneous vagus nerve stimulation - A brief introduction and overview. Autonomic Neuroscience 2022;243. Doi:10.1016/j.autneu.2022.103038.
36. Kalyani B, Venkatasubramanian G, Arasappa R, Rao N, Kalmady S, Behere R, et al. Neurohemodynamic correlates of 'OM' chanting: A pilot functional magnetic resonance imaging study. Int J Yoga 2011;4. Doi:10.4103/0973-6131.78171.

Izabela Millery da Silva Cruz
https://orcid.org/0009-0000-6611-4770
Helena Renata Silva Cysneiros
https://orcid.org/0000-0001-6467-8177
Jaqueline Severo dos Santos
https://orcid.org/0000-0002-4818-4457
Emanuel Roger dos Santos Reis
https://orcid.org/0000-0001-7119-4103
Anna Xênya Patrício de Araújo
https://orcid.org/0000-0002-7724-6805
Marcelo Moraes Valença
https://orcid.org/0000-0003-0678-3782
Taciana Aline Maciel Bezerra Oliveira
https://orcid.org/0000-0002-2039-2668
Daniella Araújo de Oliveira
https://orcid.org/0000-0002-6013-978X

Authors' contributions: IMSC: Conceptualization, Research; IMSC, TM: Data Curation; IMSC, HC, DAO: Data Curation; IMSC, HC, AXPA: Methodology; MMV, DAO: Supervision; MMV: Validation; Visualization; IMSC, HC: Writing; IMSC, JSS, ERSR: Writing – Review and Editing.
Conflict of interest: The authors declare that there is no conflict of interest.
Funding: None.