▪ Headache Medicine 2026, 17(3):190-194 ▪ p-ISSN 2178-7468, e-ISSN 2763-6178

Headache Medicine

▪ DOI: 10.48208/HeadacheMed.2026.25

Case report

Unraveling the complexity of TAC-tic syndrome: a case report with literature review

Leonardo Jun Cervera Sei[1,2], Rodrigo Pirih Pecoits[1,2], Gabriel Dal Bello Reis[1,2], Renata Gomes Londero[1,2]

[1]Federal University of Rio Grande do Sul, Porto Alegre, Rio Grande do Sul, Brazil
[2]Porto Alegre Clinical Hospital, Porto Alegre, Rio Grande do Sul, Brazil

Leonardo Jun Cervera Sei
leonardosei18@gmail.com

Edited by:
Marcelo Moraes Valença

Abstract

Background
The TAC-Tic syndrome is a rare clinical entity characterized by the coexistence of trigeminal autonomic cephalalgias and trigeminal neuralgia, making diagnosis and treatment challenging. Trigeminal autonomic cephalalgias include conditions such as cluster headache, paroxysmal hemicrania, and short-lasting unilateral neuralgiform headache attacks, including subtypes like short-lasting unilateral neuralgiform headache attacks with conjunctival injection and tearing and those with cranial autonomic symptoms.

Case report
A 64-year-old male presented with recurrent, severe right-sided facial pain, beginning in the orbital region and radiating to the forehead. The episodes, lasting from seconds to minutes, were accompanied by one-sided autonomic features like runny nose and tearing. Magnetic resonance imaging and computed tomography angiography revealed a contact between the superior cerebellar artery and the medial surface of the cisternal segment of the right trigeminal nerve, without evidence of significant distortion or morphological alteration of the nerve. Despite partial relief with carbamazepine, the patient's symptoms persisted, prompting treatment with lamotrigine and intravenous lidocaine. Remarkable pain relief was achieved, and complete remission followed after two weeks of lamotrigine treatment.

Discussion
The TAC-tic syndrome requires careful differentiation between trigeminal autonomic cephalalgias and trigeminal neuralgia, as each condition demands specific therapeutic approaches. While trigeminal neuralgia responds to anticonvulsants, trigeminal autonomic cephalalgias, such as cluster headache and paroxysmal hemicrania, may require oxygen therapy or indomethacin. This case highlights the importance of accurate diagnosis and tailored treatment to prevent persistent pain and improve the patient's quality of life.

Keywords:
TAC-tic syndrome
SUNA
Trigeminal neuralgia
Case report

Received: April 28, 2026
Revised: June 16, 2026
Accepted: August 12, 2026

© Copyright 2026

Introduction

TAC-Tic syndrome is a rare clinical entity characterized by the coexistence of trigeminal autonomic cephalalgias (TACs) and trigeminal neuralgia (TN, also known as tic douloureux). According to the International Classification of Headache Disorders, TACs include cluster headache (CH), paroxysmal hemicrania (PH), short-lasting unilateral neuralgiform headache attacks—which encompass the subtypes SUNCT (short-lasting unilateral neuralgiform headache attacks with conjunctival injection and tearing) and SUNA (short-lasting unilateral neuralgiform headache attacks with cranial autonomic symptoms)—as well as hemicrania continua (HC) (1). The reported incidence of CH is approximately 12.5 cases per 100,000 person-years; PH has an incidence of 0.1 per 100,000 person-years, and short-lasting unilateral headache attacks occur at a rate of approximately 1.2 per 100,000 person-years. In contrast, the incidence of TN ranges from 4.3 to 27 new cases per 100,000 person-years (2,3).

Only a limited number of TAC-Tic syndrome cases have been described in the literature. One of the main diagnostic challenges lies in recognizing TACs and distinguishing them from other short-lasting headache syndromes, particularly trigeminal neuralgia (4,5). Accurate recognition of this syndrome is clinically relevant because each condition requires specific therapeutic approaches to achieve both immediate and sustained pain control. Failure to identify their coexistence may result in inadequate treatment and persistent pain.

Therefore, the aim of this report is to present a case of overlapping clinical features between these two entities, ultimately leading to the diagnosis of TAC-Tic syndrome.

Methods

A 64-year-old male presented with episodes of severe pain in the right hemiface, beginning in the orbital region and radiating to the frontal area. The symptoms had started one week prior to his first presentation to the hospital emergency department and occurred approximately three times per day. The pain was described as throbbing and shock-like, lasting from a few seconds to several minutes, and was accompanied by autonomic symptoms including ipsilateral rhinorrhea, hemifacial erythema, and tearing. On further questioning, the patient identified two distinct headache/pain patterns: Pain 1: One year prior to presentation, the patient experienced an episode resembling the condition that led to the current evaluation. The attacks consisted of brief stabbing pain in the right ophthalmic (V1) division of the trigeminal nerve, lasting seconds and recurring repeatedly over approximately 15 minutes, with a frequency of 3–5 episodes per day. Associated cranial autonomic symptoms included rhinorrhea, facial erythema, and lacrimation. Pain 2: Brief stabbing pain in the right V1 territory, lasting a few seconds and occurring approximately three times daily. The attacks were consistently triggered by tactile stimulation of the lateral portion of the right eyebrow.

The presence or absence of a refractory period was not formally assessed.

Similar episodes had occurred one year earlier and were treated only with simple analgesics, without prophylactic therapy. His past medical history was notable for systemic arterial hypertension, dyslipidemia, and gout.

Physical examination was unremarkable, with a symmetrical face, preserved vision, and normal motor strength (grade V). Magnetic resonance imaging and computed tomography angiography suggested a neurovascular conflict between the anterior cerebellar artery and the right trigeminal nerve, without evidence of nerve contour distortion.

Given the clinical presentation, the differential diagnosis included trigeminal neuralgia and SUNA. Because the patient exhibited overlapping clinical features of both conditions, the final diagnosis was TAC-Tic syndrome.

For pain control, the patient initially received tramadol, morphine, and carbamazepine, resulting in partial symptom relief, likely related to improvement of the trigeminal neuralgia component. However, the episodes associated with autonomic facial symptoms persisted. Oxygen therapy via face mask was then administered without clinical response, followed by prednisolone at a dose of 1 mg/kg/day for five days, also without significant improvement.

Lamotrigine was subsequently initiated, and an intravenous lidocaine protocol was administered. After lidocaine infusion, the patient experienced marked pain relief, with complete remission achieved after two weeks of treatment with lamotrigine at a dose of 100 mg twice daily (figure 1).

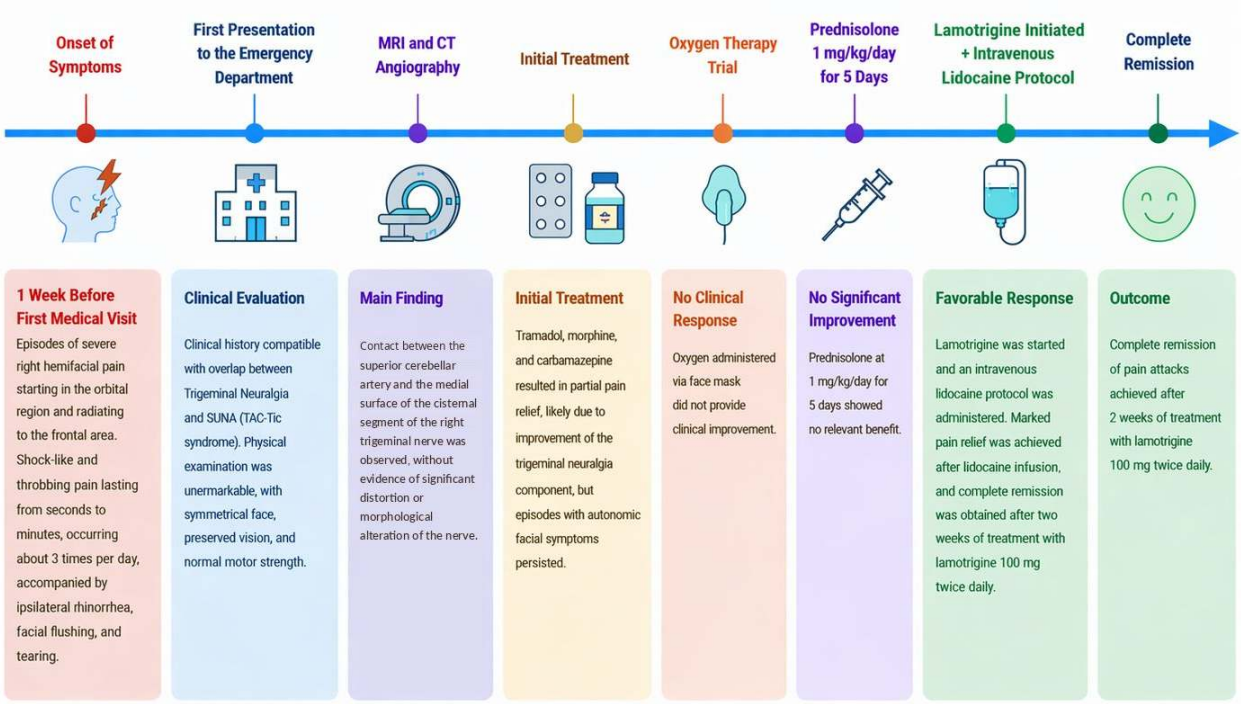

Figure 1. Timeline of the case report.

Discussion

The diagnosis of TAC-Tic syndrome is primarily clinical and remains challenging because TACs must be differentiated from other short-lasting headache disorders, particularly atypical forms of trigeminal neuralgia that may present with mild autonomic features (2,4). Accurate recognition of the overlap between these conditions is essential, as each component often requires distinct therapeutic strategies to achieve complete pain control. For instance, trigeminal neuralgia typically responds to anticonvulsants such as carbamazepine and lamotrigine, whereas certain TACs may require oxygen therapy or demonstrate an absolute response to indomethacin (2,4,6,7).

Regarding etiology, TAC-Tic syndrome may be either idiopathic or secondary to underlying pathological processes. Secondary causes reported in the literature include neurovascular conflicts, such as compression of the trigeminal nerve by intracranial arteries or the petrosal vein, as well as demyelinating lesions of the central nervous system, including multiple sclerosis plaques or clinically isolated syndrome (CIS) (3,6). The proposed pathophysiological mechanism involves a possible hypothalamic dysfunction leading to abnormal activation of the trigeminal autonomic reflex. However, it remains uncertain whether the two conditions share a common pathophysiological continuum or simply represent the coexistence of two rare disorders (2,4,7).

Attacks in TAC-Tic syndrome may occur spontaneously or be triggered by innocuous facial stimuli. Sensitivity to triggers is particularly characteristic of the trigeminal neuralgia component (2,6). Common triggers for the paroxysmal pain episodes (the "tic") include routine activities such as washing the face, shaving, or brushing the teeth (3,6). Simple tactile stimulation of the affected area is another frequent trigger, as are oral functions such as chewing and eating (2,6,7).

While cutaneous triggers are classically associated with trigeminal neuralgia and certain TACs such as SUNCT, the cluster headache component may be specifically triggered by sleep and often exhibits a nocturnal pattern (3). Literature reviews indicate that innocuous stimuli precipitate the "tic" component in approximately 70% to 92% of patients, depending on the syndrome subtype (2). These same stimuli may also trigger the autonomic headache component in some cases, occurring in approximately 15% of Cluster-Tic cases and up to 67% of paroxysmal hemicrania-tic cases (2). Among short-lasting TACs, cutaneous triggers are significantly more frequent in SUNCT (74% of cases) than in SUNA (22% of cases) (2).

Another compelling point of discussion is the higher frequency of V1 involvement observed in patients with TAC-tic syndrome compared to those with isolated trigeminal neuralgia. Tables 1 and 2 summarize data from published case reports and case series, highlighting the specific trigeminal branches affected (7–13).

Table 1. Distribution of trigeminal branch involvement by patient

Autor, Year	Trigeminal branch
Prakash & Rathore (7), 2016	V2 (maxilar)
Prakash & Rathore (7), 2016	V2 (maxilar)
Wilbrink et al.(8), 2013	V2
Wilbrink et al.(8), 2013	V1 + V2
Wilbrink et al.(8), 2013	V2
Wilbrink et al.(8), 2013	V1
Wilbrink et al.(8), 2013	V1
Wilbrink et al.(8), 2013	V1
Wilbrink et al.(8), 2013	V1 + V2
Wilbrink et al.(8), 2013	V1
Wilbrink et al.(8), 2013	V1
Wilbrink et al.(8), 2013	V1
Wilbrink et al.(8), 2013	V1
Martínez-Salio et al.(9), 2001	V3 (mandibular)
Caminero et al.(10), 1998	V2 + V3
Hannerz (11), 1993	V2 + V3
Klimek et al.(12), 1987	V2
Watson & Evans (13), 1985	V2 + V3
Watson & Evans (13), 1985	V1
Watson & Evans (13), 1985	V1
Watson & Evans (13), 1985	V2 + V3
Watson & Evans (13), 1985	-
Watson & Evans (13), 1985	-
Watson & Evans (13), 1985	-
Watson & Evans (13), 1985	V2
Watson & Evans (13), 1985	V2
Watson & Evans (13), 1985	V2 + V3
Watson & Evans (13), 1985	V1
Watson & Evans (13), 1985	V1 + V2 + V3
Watson & Evans (13), 1985	V2
Watson & Evans (13), 1985	V1 + V2 + V3
Watson & Evans (13), 1985	V2

Table 2. Distribution of trigeminal branch involvement

Pattern of involvement	Number of Cases (n=29)	Percentage
(%)		
V1 only	10	34.5
V2 only	10	34.5
V3 only	1	3.4
V1 + V2	2	6.9
V2 + V3	5	17.2
V1 + V2 + V3	2	6.9

Management of TAC-Tic syndrome is complex and often requires different pharmacological strategies for each component. Failure to recognize the coexistence of these conditions may lead to inadequate pain control. For the trigeminal neuralgia component, carbamazepine remains the first-line treatment, although lamotrigine, gabapentin, pregabalin, and baclofen are also effective alternatives. In contrast, treatment of TACs depends on the specific subtype: paroxysmal hemicrania and hemicrania continua demonstrate an absolute response to indomethacin, whereas cluster headache may require oxygen therapy, triptans, verapamil, lithium, or corticosteroids such as prednisone.

In cases of acute or refractory pain, additional interventions may include sphenopalatine ganglion blockade with lidocaine, intravenous lidocaine infusion, or rescue analgesics such as tramadol and morphine. Surgical procedures, particularly microvascular decompression (MVD), may be indicated when a neurovascular conflict is identified, although long-term outcomes for the headache component may be variable. In secondary TAC-Tic syndrome, definitive treatment should address the underlying cause—such as surgical removal of tumors or treatment of demyelinating lesions—which may result in complete remission of symptoms.

References

1. Headache Classification Committee of the International Headache Society (IHS) The International Classification of Headache Disorders, 3rd edition. Cephalalgia 2018;38:1–211. Doi:10.1177/0333102417738202.
2. Wöber C. Tics in TACs: A Step into an Avalanche? Systematic Literature Review and Conclusions. Headache: The Journal of Head and Face Pain 2017;57:1635–47. Doi:10.1111/head.13099.

3. Chen PM, Ben-Haim S, Handwerker J, Ansari H. Cluster-Tic or Tic-Cluster? Trigeminal Neuralgia (Tic) Turning to Trigeminal Autonomic Cephalalgia (TAC) Following Venous Decompression of the Trigeminal Nerve: A Case Report and Review of the Literature. Annals Of Headache Medicine Journal 2019. Doi:10.30756/ahmj.2020.01.02.
4. May A, Leone M, Áfra J, Linde M, Sándor PS, Evers S, et al. EFNS guidelines on the treatment of cluster headache and other trigeminal-autonomic cephalalgias. Eur J Neurol 2006;13:1066–77. Doi:10.1111/j.1468-1331.2006.01566.x.
5. Alves MRPB, Valença MM. Cluster-tic syndrome: case report and literature review. Headache Medicine 2017:58–9. Doi:10.48208/HeadacheMed.2017.15.
6. Ljubisavljevic S, Prazic A, Lazarevic M, Stojanov D. The Rare Painful Phenomena – Chronic Paroxysmal Hemicrania-tic Syndrome as a Clinically Isolated Syndrome of the Central Nervous System. Pain Physician 2017;2:315–22. Doi:10.36076/ppj.2017.E322.
7. Prakash S, Rathore C. Two Cases of Hemicrania Continua–Trigeminal Neuralgia Syndrome: Expanding the Spectrum of Trigeminal Autonomic Cephalalgia-Tic (TAC-TIC) Syndrome. Headache: The Journal of Head and Face Pain 2017;57:472–7. Doi:10.1111/head.12965.
8. Wilbrink LA, Weller CM, Cheung C, Haan J, Ferrari MD. Cluster-Tic Syndrome: A Cross-Sectional Study of Cluster Headache Patients. Headache: The Journal of Head and Face Pain 2013;53:1334–40. Doi:10.1111/head.12161.
9. Martínez-Salio A, Porta-Etessam J, Pérez-Martínez D, Balseiro J, Gutiérrez-Rivas E. Chronic Paroxysmal Hemicrania-Tic Syndrome. Headache: The Journal of Head and Face Pain 2000;40:682–5. Doi:10.1046/j.1526-4610.2000.040008682.x.
10. Caminero A, Pareja J, Dobato J. Chronic Paroxysmal Hemicrania-Tic Syndrome. Cephalalgia 1998;18:159–61. Doi:10.1046/j.1468-2982.1998.1803159.x.
11. Hannerz J. Trigeminal Neuralgia With Chronic Paroxysmal Hemicrania: the CPH-tic Syndrome. Cephalalgia 1993;13:361–4. Doi:10.1046/j.1468-2982.1993.1305361.x.
12. Klimek A. Cluster-Tic Syndrome. Cephalalgia 1987;7:161–2. Doi:10.1046/j.1468-2982.1987.0702161.x.
13. Watson P, Evans R. Cluster-Tic Syndrome. Headache: The Journal of Head and Face Pain 1985;25:123–6. Doi:10.1111/j.1526-4610.1985.hed2503123.x.

Leonardo Jun Cervera Sei
https://orcid.org/0009-0000-3134-2685
Rodrigo Pirih Pecoits
https://orcid.org/0000-0002-3966-9049
Gabriel Dal Bello Reis
https://orcid.org/0009-0005-3766-8615
Renata Gomes Londero
https://orcid.org/0000-0002-9780-4739

Authors contributions: LJCS, RPP, GDBR: collected the data, conducted the literature search, drafted the manuscript, critically revised the content; RGL: supervised the study, provided guidance throughout the research process, critically revised the manuscript. All authors approved the final version of the manuscript and take responsibility for the integrity and accuracy of the work.
Conflict of interest: The authors declare no conflict of interest related to the preparation and content of this work.
Funding: This research did not receive any specific funding from public, commercial, or not-for-profit funding agencies.
Artificial Intelligence(AI) Use: The use of AI was for creating the timeline figure of the case report.