▪ Headache Medicine 2026, v. 17, n. 2 ▪ p. 161-164 ▪ p-ISSN 2178-7468, e-ISSN 2763-6178

Headache Medicine

▪ DOI: 10.48208/HeadacheMed.2026.20

Case report

Epicrania fugax in a patient with an arachnoid cyst in Meckel's cave

Marcelo Palmares Oliveira-e-Silva[1], Pedro Augusto Sampaio Rocha-Filho[2,3]

[1]Hospital das Clínicas, Federal University of Pernambuco, Recife, Pernambuco, Brazil
[2]Federal University of Pernambuco, Recife, Pernambuco, Brazil
[3]Oswaldo Cruz University Hospital, University of Pernambuco, Recife, Pernambuco, Brazil

Pedro Augusto Sampaio Rocha-Filho
pedro.rochafilho@ufpe.br

Edited by:
Marcelo Moraes Valença

Abstract

Introduction
Although epicrania fugax is classified as a primary headache disorder, some cases associated with intracranial and extracranial lesions have been reported.

Methods
Case report.

Results
A 45-year-old woman presented with a three-year history of headache, which she described as a severe stabbing pain, radiating from the right temporal region to the left temporal region, lasting approximately two seconds and occurring once per week. After one month, she also developed an additional headache described as a blade cutting the skin, of severe intensity, radiating along a zigzag trajectory from the left posterolateral cervical region to the left parietal area, occasionally crossing the midline, lasting 8 to 10 seconds. This occurred every two days, at times in clusters, and was not associated with autonomic symptoms. A brain MRI revealed a 2.4×1.9 cm lobulated extra-axial cystic lesion without contrast enhancement, closely related to the left Meckel's cave, suggestive of an arachnoid cyst.

Conclusion
This case underscores the need to investigate epicrania fugax using brain MRI to rule out secondary causes.

Keywords
Epicrania fugax
Headache disorders
Secondary
Arachnoid cysts
Trigeminal nerve

Received: April 5, 2026
Revised: May 31, 2026
Accepted: July 2nd, 2026

© Copyright 2026

Introduction

Epicrania fugax (EF) is a headache disorder characterized by paroxysmal stabbing pain lasting from one to ten seconds, which radiates along either a linear or zigzag trajectory across the surface of one hemicranium and begins and ends within the distributions of different nerves (1). Initial reports described pain irradiation along a postero-anterior trajectory. However, subsequent studies have identified additional variations, which include an antero-posterior trajectory, side-to-side radiation across the head, multidirectional spread, pain restricted to the face, and pain that originates in the head and radiates to another part of the body (2).

Although EF is classified as a primary headache disorder, some cases associated with intracranial and extracranial lesions have been reported. These include a case of EF occurring in the context of a cerebellopontine angle meningioma causing trigeminal nerve compression (3); a case with onset after radiation therapy for a skull base meningioma in contact with the trigeminal root; several cases involving vascular contact with or compression of the trigeminal nerve; a case associated with lateral medullary infarction; another linked to an ipsilateral cerebellar abscess; and a case arising from a keloid scar on the scalp following excision of a subcutaneous hemangioma (2).

Here, we report a patient with EF associated with an arachnoid cyst in Meckel's cave.

Case report

A 45-year-old woman presented with a three-year history of headache, which she described as a severe stabbing pain, radiating from the right temporal region to the left temporal region, lasting approximately two seconds and occurring once per week. After one month, she also developed an additional headache described as a blade cutting the skin, of severe intensity (10 out of 10), radiating along a zigzag trajectory from the left posterolateral cervical region to the left parietal area, occasionally crossing the midline, lasting 8 to 10 seconds. This occurred every two days, sometimes in clusters of up to three attacks within five minutes. No triggers or autonomic symptoms were reported (Figure1).

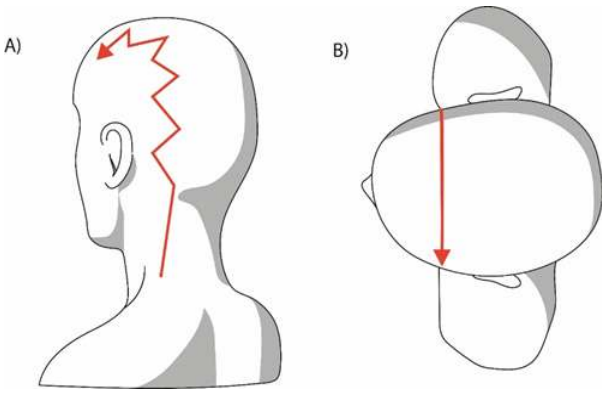

Figure 1. Trajectories of the pain in our patient: a) stemming from the posterolateral cervical region and radiating to the left parietal region and b) stemming from the right parietal region and radiating to the left parietal region.

The patient also presented with seven-year history of chronic migraine, with attacks occurring on 16 days per month, predominantly on the left side but occasionally bilateral or right-sided. Treatment with nortriptyline (25 mg/day) was associated with a partial response, reducing monthly migraine frequency by approximately 25%. Throughout follow-up, escalation of nortriptyline was precluded by dose-limiting xerostomia, while venlafaxine was poorly tolerated because of nausea.

There was no temporal association between her migraine episodes and the EF events. Her medical history reported depressive and anxiety disorders.

Her general and neurological examinations demonstrated no abnormalities.

An initial brain MRI revealed a 2.4×1.9 cm lobulated extra-axial cystic lesion without contrast enhancement, closely related to the left Meckel's cave, suggestive of an arachnoid cyst (Figure 2).



Figure 2. An axial T2 MRI sequence demonstrates a large 2.4x1.9 cm hyperintense cystic lesion, consistent with an arachnoid cyst, confined to Meckel's cave.

After two years, a repeat brain MRI was performed to assess cyst progression, which had remained stable. The case was reviewed with the neurosurgery team, which decided not to pursue surgical intervention.

Given the low frequency of EF attacks, no specific pharmacological treatment was initiated.

Discussion

Our patient exhibited two patterns of ultra-rapid headache that began and ended within the distribution of different nerves, consistent with EF. Although the current International Classification of Headache Disorders specifies that the pain should remain confined to one hemicranium (1), this is not the case in all reported instances (2). It is therefore possible that this criterion will be revised in future editions.

The patient was found to have an arachnoid cyst in Meckel's cave. Arachnoid cysts account for 1% of intracranial space-occupying lesions and are most often asymptomatic, typically identified incidentally (4). However, cases of trigeminal neuralgia and trigeminal neuropathy associated with arachnoid cysts located in Meckel's cave have been reported, in which the trigeminal nerve is compressed by the cyst (4–6).

Based on the available literature, this appears to be the first reported case of EF occurring in association with an arachnoid cyst. However, cases of EF related to vascular compression of the trigeminal nerve or to compression by meningiomas have previously been documented (3,7,8).

The pathophysiology of EF is not well established. The pain is believed to be generated peripherally, with possible intra- or extracranial sources, while its propagation likely occurs through central mechanisms involving the trigeminocervical complex (2). In our patient, the pain was probably generated within the trigeminal nerve, compressed by the arachnoid cyst. The cyst was located on the left side, corresponding to the side of the zigzag-pattern pain, suggesting a potential causal relationship. However, because the arachnoid cyst was not treated, the primary evidence of causality—namely, improvement of symptoms following treatment— is lacking. It is also plausible that the peripheral and central sensitization occurring in chronic migraine may have contributed to the development of EF in our patient.

Conclusion

This case underscores the need to investigate EF using brain MRI to rule out secondary causes.

References

1. Headache Classification Committee of the International Headache Society (IHS) The International Classification of Headache Disorders, 3rd edition. Cephalalgia 2018;38:1–211. Doi:10.1177/0333102417738202.
2. Cuadrado M-L. Epicranial headaches part 2: Nummular headache and epicrania fugax. Cephalalgia 2023;43. Doi:10.1177/03331024221146976.
3. Sitaraman S, Panda AK, Sharma A. Facial variant of epicrania fugax secondary to a cerebellopontine angle meningioma. Headache: The Journal of Head and Face Pain 2025;65:371–2. Doi:10.1111/head.14878.
4. Bigder MG, Helmi A, Kaufmann AM. Trigeminal neuropathy associated with an enlarging arachnoid cyst in Meckel's cave: case report, management strategy and review of the literature. Acta Neurochir (Wien) 2017;159:2309–12. Doi:10.1007/s00701-017-3262-5.
5. Kouyialis AT, Stranjalis G, Boviatsis EJ, Ziaka DS, Bouras TI, Sakas DE. Recurrence of trigeminal neuralgia due to an acquired arachnoid cyst. Journal of Clinical Neuroscience 2008;15:1409–11. Doi:10.1016/j.jocn.2006.10.027.
6. Hanakita S, Oya S, Matsui T. Trigeminal neuralgia caused by an arachnoid cyst in Meckel's cave: A case

report and literature review. Surg Neurol Int 2021;12. Doi:10.25259/SNI_734_2020.
7. Fernández-Matarrubia M, Gutiérrez-Viedma Á, Cuadrado M-L. Case report: Epicranial pain after radiotherapy for skull base meningioma – the first symptomatic epicrania fugax? Cephalalgia 2016;36:1389–91. Doi:10.1177/0333102416642425.
8. Gutiérrez-Viedma Á, González-García N, Yus M, Jorquera M, Porta-Etessam J, García-Moreno H, et al. Facial epicrania fugax: A prospective series of eight new cases. Cephalalgia 2017;37:1145–51. Doi:10.1177/0333102416668656.

Marcelo Palmares Oliveira-e-Silva
https://orcid.org/0000-0002-5538-3753
Pedro Augusto Sampaio Rocha-Filho
https://orcid.org/0000-0001-5725-2637

Author contributions: MPO, PASR: Conception and design; analysis and interpretation of data; drafting the article and revising it critically for important intellectual content; final approval of the version to be published.
Conflict of Interest: The authors declare no conflict of interest related to the preparation and content of this work.
Funding: This research received no specific grant from any funding agency in the public, commercial, or not-for-profit sectors.
Ethics Statement: No ethics approval was required due to the study design. Informed consent was obtained from the patient for the publication of this letter and the accompanying images.