



SUNCT syndrome associated with pituitary Rathke's cyst and responsive to indomethacin: a case report

Francisca Natiele da Silva Cavalcante¹, Raimundo Pereira Silva-Néto², Carlos Alberto Bordini¹

¹Municipal School of Medicine of Franca, Franca, São Paulo, Brazil

²Federal University of the Parnaíba Delta, Parnaíba, Piauí, Brazil



Carlos Alberto Bordini
cabord@com4.com.br

Edited by:
Marcelo Moraes Valença

Keywords:
Rathke's cleft cyst
Secondary SUNCT syndrome
Indomethacin.

Introduction

Short-lasting unilateral neuralgiform headache attacks (SUNCT/SUNA) is a rare group of headaches classified by the International Classification of Headache Disorders (ICHD-3) in its group 3, the trigeminal-autonomic headaches, and, therefore a primary headache. Rathke's cleft cysts are sellar or suprasellar non-neoplastic cystic lesions arising from remnants of Rathke's pouch. These cysts are asymptomatic, but when large, they compress adjacent structures and may present with headache, visual disturbance, and pituitary dysfunction. Cases of secondary SUNCT/SUNA have been reported; however, this is the first report of SUNCT/SUNA associated with a Rathke's cleft cyst.

Case Report

A 47-year-old, other while healthy male has been experiencing for the last five years a strictly right sided pain in the orbital and in the frontoparietal area. The pain was felt as if a nail was being driven into his cranium slowly for 5-15 seconds, with intense pain persisting in the area for a few more seconds. Pain intensity was described as excruciating (10/10), a frequency of 4-18 a day, duration of 4-30 seconds, associated to 2-3 eardrops and moderate conjunctival hyperemia ipsilateral to the pain. Attacks never could be attacks triggered by cutaneous stimuli. Physical and neurological examinations were normal. MRI showed a cystic lesion in the anterior pituitary gland consistent with a Rathke's cleft cyst. The pain was refractory to carbamazepine, amitriptyline, topiramate, and methadone, but was responsive to indomethacin.

Comment

To the best of our knowledge, this case report appears to be the first on SUNCT: a) associated with Rathke's cleft cyst; and b) responsive to indomethacin.

Received: July 29, 2025
Revised: August 17, 2025
Accepted: September 26, 2025



Introduction

SUNCT/SUNA

The trigeminal autonomic cephalalgias (TACs) are a group of primary headache disorders characterized by unilateral head pain that occurs in association with prominent ipsilateral cranial autonomic features, such as lacrimation, conjunctival injection, or nasal symptoms (1). They belong to the group 3 of the ICHD-3 (2). Trigeminal autonomic cephalalgias, encompassing four subgroups, namely, cluster headache, paroxysmal hemicrania, and SUNCT/SUNA and hemicrania continua. The third subgroup, SUNCT/SUNA concerns rare primary headache syndromes. Affected patients experience very frequent, brief attacks of head and facial pain combined with autonomic symptoms. ICHD-3 diagnostic criteria for SUNCT/ SUNA are seen in Table 1.

Table 1. ICHD-3 diagnostic criteria for short-lasting unilateral neuralgiform headache attacks (SUNCT)

A.	At least 20 attacks fulfilling criteria B–D
B.	Moderate or severe unilateral head pain, with orbital, supraorbital, temporal and/or other trigeminal distribution, lasting for 1–600 seconds and occurring as single stabs, series of stabs or in a saw-tooth pattern
C.	At least one of the following five cranial autonomic symptoms or signs, ipsilateral to the pain: <ol style="list-style-type: none"> 1. conjunctival injection and/or lacrimation 2. nasal congestion and/or rhinorrhea 3. eyelid oedema 4. forehead and facial sweating 5. miosis and/or ptosis
D.	Occurring with a frequency of at least one a day
E.	Not better accounted for by another ICHD-3 diagnosis.

SD- standard deviation.

SUNCT (group 3.3.1 of ICHD-3) is characterized by the simultaneous presence of both conjunctival injection and lacrimation, while in SUNA (group 3.3.2 of ICHD-3), either (or no one) 1 of the 2 symptoms is present. The frequency of daily pain attacks can be between 1 and 100 attacks, with the number varying extremely from patient to patient (3).

Pituitary Rathke's cleft cysts

Rathke's cleft cysts are sellar or suprasellar non-neoplastic cystic lesions arising from remnants of Rathke's pouch. Symptomatic cases are relatively rare and the majority are discovered incidentally. Rathke's cleft cysts are sellar or suprasellar non-neoplastic cystic lesions arising from remnants of Rathke's pouch. Symptomatic cases are relatively rare, and the majority are discovered incidentally (4).

Rathke's cleft cysts are mostly asymptomatic and become clinically apparent if they are large enough to compress adjacent structures or rupture. In this case, the most common chronic symptoms at presentation are headache, visual disturbance, and pituitary dysfunction (4, 5). The most common manifestation of Rathke's cleft cyst at presentation is headache. In up to 40% of cases, this may be the only symptom. Headaches associated with Rathke's cleft cyst are most commonly episodic and non-pulsating frontal, bilateral, or deep retro-orbital pain and are occasionally associated with nausea and vomiting (4, 5).

Case Report

A 47-year-old, other while healthy male has been experiencing for the last five years a strictly right sided pain in the orbital and in the frontoparietal area. The pain was felt as if a nail was being driven into his cranium slowly for 5-15 seconds, with intense pain persisting in the area for a few more seconds. Pain intensity was described as excruciating (10/10), a frequency of 4-18 a day, duration of 4-30 seconds, associated to 2-3 eardrops and moderate conjunctival hyperemia ipsilateral to the pain. Attacks never could be attacks triggered by cutaneous stimuli.

Thus, present case completely fulfills ICHD-3 diagnostic criteria for SUNCT syndrome. Sensation of restlessness used to occur in some attacks. The disease has greatly interfered with his life. Physical and neurological examinations were unremarkable. The pain was refractory to carbamazepine (800 mg/d), amitriptyline (25 mg/d), topiramate 100 mg/d, and methadone. Clinical and neurological examinations were unremarkable. After the first consultation patient was prescribed indomethacin 50 mg bid as a temporary therapy for the period in which the patient was to undergo the proper investigations. Fifteen days later, the patient returned to bring the test results. Hormonal investigation (prolactin, THS, T3, T4, ACTH, cortisol, LH, FSH) rendered values inside the normal range. MRI revealed no evidence of neurovascular compression but showed the presence of a cystic lesion in the anterior pituitary gland measuring approximately 7 mm in diameter, consistent with a Rathke's cleft cyst.

Unexpectedly, during his second visit, the patient informed us that after the second dose of indomethacin, he has been completely free of attacks. Patient was seen 3 months later and remains asymptomatic. Case was discussed with neurosurgeon who opted for conservative (non-surgical) treatment.



This case has two peculiar features, namely the association with Rathke's cleft cyst and the complete response to indomethacin that make it worthy of publication.

Discussion

TACs represent one of the most fascinating topics in headache medicine. This case presents many peculiarities that encourage further discussion.

Symptomatic SUNCT syndrome

It is well known that structural lesion can lead to TAC symptoms, which cannot easily be differentiated from those of idiopathic TACs. Recognizing these underlying pathologies is of crucial importance, as they can influence treatment and outcome (6,7). It is also known that a fairly high proportion of all three TACs (cluster headache, paroxysmal hemicrania and SUNCT/SUNA syndrome) were secondary to pituitary lesions (8). In Cittadini et al. (8) on symptomatic SUNCT syndrome, 10 cases of symptomatic SUNCT were reported. The underlying lesions were: seven patients (70%) had a pituitary adenoma of whom 5 had a functioning adenoma (4 prolactinomas, 1 acromegaly) and 2 had a non functioning adenoma. The other three patients had a pilocytic astrocytoma in the cerebellopontine angle, bilateral intraorbital, metastatic bronchial carcinoid, and an orbital cystic lesion not otherwise specified.

In the review by de Coo et al. (9), 29 cases of SUNCT/SUNA were found, 14 of them were defined as probably symptomatic SUNCT/SUNA the remaining were deemed to be less probable ones). The most often found cause in probably symptomatic group was compression of the trigeminal nerve by an artery (8 out of 14), followed by malignancies as a mixed gangliocytoma, an epidermoid tumor, and prolactinomas, an aneurysm and one cavernous sinus dural fistula.

There is one Brazilian report on such cases (10). It concerned a patient with typical SUNCT syndrome associated to pituitary tumor with little suprasellar extent, which symptoms completely remitted following surgery eradicating the tumor.

Association or incidentally?

In ICHD-3 it may be seen: "Primary or secondary headache or both? When a new headache with the characteristics of a TAC occurs for the first time in close temporal relation to another disorder known to cause headache, or fulfills other criteria for causation by that disorder, the new headache is coded as a secondary headache attributed to the causative disorder.

Let us take the statement "Another disorder known to cause headache". In this case, this statement is tricky. Although Rathke's cleft cysts can cause headaches, they generally do not have the features of a TAC. On the Other hand, it is also known that high proportion of all three (cluster headache, paroxysmal hemicranias and SUNCT/SUNA syndrome) trigeminal autonomic cephalalgia syndromes were secondary to pituitary lesions (8). In a review of the clinical characteristics of headache in patients with pituitary tumors, it was found the propensity for pituitary and peri pituitary gland pathology to present as a phenotypic TAC (11). In the cohort of 84 patients with pituitary tumors and headache problems, 10% had a TAC-like headache. This is about 100-fold the distribution of the conditions and it is well known too that a large number of patients of secondary TACs have responded to the standard existent treatment aimed at the primary disorder. Hence, the response to indomethacin does not imply that the presence of Rathke's cleft cyst were merely incidental (12).

Considering all these findings, our opinion is that the pendulum seems to swing towards causality rather than incidentally, this meaning that present case actually should be seen as a symptomatic SUNCT secondary to Rathke's cleft cyst.

As for SUNCT secondary to Rathke's cleft cyst, a search carried out in the medical database PubMed on July 21, 2025, using the descriptors "SUNCT syndrome" AND "Rathke's cleft cyst" retrieved zero results, suggesting that this is first report of such association.

Investigation

The investigation on this case was performed in agreement with the European Headache Federation consensus (13), and recommendations by Levy et al. (11).

SUNCT/SUNA management and the response to indomethacin

The reasons for choosing indomethacin were the following: 1) an attempt to bring some relief to the patient's desolate situation; 2) as a rule in our service, we usually prescribe indomethacin for strictly unilateral headaches, provisionally before a definitive diagnosis is made; e both ICHD-3 (2) and Cohen et al. (14) describe the pain in SUNCT/SUNA may as single stabs, series of stabs or in a saw-tooth pattern may occur. In the current case, pain was stabbing-like, and primary stabbing headache (ICHD-3 group 4.7) uses to be responsive to indomethacin (Figure 1).

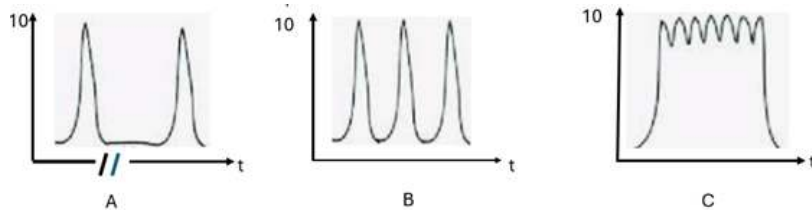


Figure 1. Patterns of pain in SUNCT. A. Attacks are single stabs. B. Each attack is a group of stabs. C. The pain intensity has a saw-tooth pattern. i = pain intensity

According to Burish (15), the first-line preventive treatment for SUNCT and SUNA is lamotrigine, supported by several cohort studies that found lamotrigine to be the most effective treatment. Other effective treatments included carbamazepine, duloxetine, gabapentin, oxcarbazepine, pregabalin, topiramate and verapamil. Interestingly, the author clearly states, "This article discusses the non-indomethacin-responsive trigeminal autonomic cephalalgias". Even though, reports claiming that cluster headache may responsive to indomethacin exists (15).

Watson and Evans (16) treated 11 chronic cluster headache patients with indomethacin at a dose of 25 to 50 mg t.i.d. The percentage of patients responsive to indomethacin (36%) was comparable to lithium (43%), methysergide (37%), and prednisone (36%) (16). Other investigators regard cluster headache as a disease unresponsive to indomethacin (17). On this issue, Cittadini et al. (8) state paroxysmal hemicrania responds in a dramatic and absolute fashion to indomethacin, thereby underlining the importance of distinguishing it from cluster headache and SUNCT, which are not responsive to indomethacin.

Based on our discussion and , and having in mind Watson and Evans' (16) and present report, we would suggest that instead of using the term "indomethacin-unresponsive headaches," a more accurate term would be "indomethacin usually nonresponsive headaches."

The most important points of this report are: this paper seems to be the first on a SUNCT case associated with Rathke's cleft cyst, SUNCT patient responsive to indomethacin.

References

1. Goadsby PJ, Cittadini E, Cohen AS. Trigeminal autonomic cephalalgias: paroxysmal hemicrania, SUNCT/SUNA, and hemicrania continua. *Semin Neurol* 2010;30:186–91. Doi:10.1055/s-0030-1249227.
2. Headache Classification Subcommittee of the International Headache Society. The International Classification of Headache Disorders, 3rd edition. *Cephalalgia* 2018;38:1–211. Doi:10.1177/0333102417738202.
3. Diener HC, Tassorelli C, Dodick DW. Management of trigeminal autonomic cephalalgias Including chronic

- cluster: A review. *JAMA Neurol* 2023;80(3):308–19. Doi:10.1001/jamaneurol.2022.4804.
4. Larkin S, Karavitaki N, Ansorge O. Rathke's cleft cyst. *Handb Clin Neurol* 2014;124:255–269. Doi:10.1016/B978-0-444-59602-4.00017-4.
5. Kim JE, Kim JH, Kim OL, Paek SH, Kim DG, Jung HW. Surgical treatment of symptomatic Rathke cleft cysts: clinical features and results with special attention to recurrence. *J Neurosurg* 2004;100:33–40. Doi:0.3171/jns.2004.100.1.0033.
6. Donat J. A patient with cluster headache—due to a brainstem lesion. *Headache* 2012;52:1035–6. Doi:10.1111/j.1526-4610.2011.02044.x.
7. Williams M, Bazina R, Tan L, Rice H, Bradley SA. Microvascular decompression of the trigeminal nerve in the treatment of SUNCT and SUNA. *J Neurol Neurosurg Psychiatry* 2010;81:992–6. Doi:10.1136/jnnp.2009.182824.
8. Cittadini E, Matharu MS. Symptomatic trigeminal autonomic cephalalgias. *Neurologist* 2009;15:305–12. Doi:10.1097/NRL.0b013e3181ad8d67.
9. de Coo IF, Wilbrink LA, Haan J. Symptomatic Trigeminal Autonomic Cephalalgias. *Curr Pain Headache Rep* 2015;19:39. Doi:10.1007/s11916-015-0514-z.
10. Rocha Filho PA, Galvão AC, Teixeira MJ, Rabello GD, Fortini I, Calderaro M, et al. SUNCT syndrome associated with pituitary tumor: case report. *Arq Neuropsiquiatr* 2006;64:507–10. Doi:10.1590/s0004-282x2006000300029.
11. Levy MJ, Matharu MS, Meeran K, Powell M, Goadsby PJ. The clinical characteristics of headache in patients with pituitary tumours. *Brain* 2005;128:1921–30. Doi:10.1093/brain/awh525.
12. Chowdhury D. Secondary (symptomatic) trigeminal autonomic cephalalgia. *Ann Indian Acad Neurol* 2018;21:S57–S69. Doi:10.4103/aian.AIAN_16_18.
13. Mitsikostas DD, Ashina M, Craven A, Diener HC, Goadsby PJ, Ferrari MD, et al. European Headache Federation consensus on technical investigation for primary headache disorders. *J Headache Pain* 2015;17:5. Doi:10.1186/s10194-016-0596-y.
14. Cohen AS, Matharu MS, Goadsby PJ. Short-lasting unilateral neuralgiform headache attacks with conjunctival injection and tearing (SUNCT) or cranial autonomic features (SUNA)—a prospective clinical study of SUNCT and SUNA. *Brain* 2006;129:2746–60. Doi:10.1093/brain/awl202.
15. Burish M. Cluster Headache, SUNCT and SUNA. *Continuum (Minneapolis)* 2024;30(2):391–410.



Doi:10.1212/CON.0000000000001411.

16. Watson CPN, Evans RJ. Chronic cluster headache: A review of 60 patients. *Headache* 1987;27:158–65. Doi:10.1111/j.1526-4610.1987.hed2703158.x.

17. Prakash S, Shah ND, Chavda BV. Cluster headache responsive to indomethacin: Case reports and a critical review of the literature. *Cephalalgia*. 2010;30:975–82. Doi:10.1177/0333102409357642.

Francisca Natiele da Silva Cavalcante
<https://orcid.org/0009-0000-0245-7280>
Raimundo Pereira Silva-Néto
<https://orcid.org/0000-0002-2343-9679>
Carlos Alberto Bordini
<https://orcid.org/0000-0002-1249-5202>

Authors' contribution: All authors had the same contribution.

Conflict of interests: The authors report no conflict of interest.

Funding: No