



Spontaneous posterior vitreous detachment and chronification of migraine with aura: A case report exploring visual snow syndrome

João Guilherme Bochnia Küster¹, Elcio Juliato Piovesan²

¹Zilda Arns Elderly Hospital, Department of Internal Medicine, Curitiba, Paraná, Brazil

²Federal University of Paraná General Hospital, Neurology Service, Department of Internal Medicine, Curitiba, Paraná, Brazil



João Guilherme Bochnia Küster
jgbkuster@hotmail.com

Introduction

Posterior vitreous detachment is characterized by the separation of the vitreous humor from the retina, with its spontaneous occurrence involving photopsias and floaters. Treatment options in cases without retinal involvement are limited and observation is recommended. Migraine with aura may have visual snow syndrome as a comorbidity, with visual snow corresponding to dynamic visual changes similar to static dots.

Case Report

A 57-year-old woman reported the sudden onset of complex bright flashes filling her visual field, dysmorphic multicolored rays and progressive left-sided headache of severe intensity with a pattern similar to her migraine with aura, although the visual manifestations were distinct from her typical aura presentations. Neurological examination was normal and direct ophthalmoscopy showed no retinal alterations. After complementary investigation, left posterior vitreous detachment was demonstrated with ultra-wide field retinal imaging. She maintained higher migraine frequency and intensity after the event in the following year, with the floaters being occasionally accompanied by photophobia, impaired night vision and small moving snow dots occurring in the vision of both eyes and contributing to the headache.

Conclusion

This case indicates the importance of considering acute ocular abnormalities with the establishment of flashes and floaters and explores the development of secondary visual snow, an atypical clinical condition, after posterior vitreous detachment, which may be related to the chronification of the migraine.

Keywords:

Chronic migraine
Migraine with aura
Posterior vitreous detachment
Visual snow syndrome
Case report

Submitted: March 4, 2025
Accepted: June 19, 2025
Published online: June 30, 2025



Introduction

Posterior vitreous detachment (PVD) is characterized by the separation of the vitreous humor from the retina, with an estimated prevalence of 24% in the 50-59 years age group and progressing more rapidly in postmenopausal women, with age-related factors being responsible for the liquefaction of the vitreous gel and weakness in the adhesion of collagen fibers to the ocular extracellular matrix. The spontaneous occurrence of a PVD tends to present with complex visual alterations of photopsias and floaters, respectively perceived as flashes and dark moving lines more evident in bright backgrounds and described as flies or webs, with the neuro-ophthalmological evaluation being essential for its diagnosis. The risk of retinal detachment from vitreoretinal traction during symptomatic PVD is as high as 35%. Treatment options such as vitrectomy and laser or pharmacological vitreolysis are studied to a limited extent in PVD, but are considered of risk because they are invasive procedures and, in the case of pharmacological treatments, may increase the amount of floaters, thus observation is recommended in cases without retinal involvement (1). The sudden changes resulting from PVD are an important cause of negative impact on quality of life, with the presence of symptomatic floaters resulting in a higher prevalence of depressive symptoms, anxiety traits and self-perception of psychological stress (2).

In turn, migraine is a type of primary headache with high prevalence and impact on quality of life, with its diagnosis being performed according to the International Classification of Headache Disorders 3rd edition (ICHD-3). One third of migraine patients have the clinical form of migraine with aura, characterized by the occurrence of transient focal neurological symptoms that precede or accompany the headache. The most common type corresponds to visual aura, affecting about 90% of individuals with migraine with aura and usually presenting with scintillating scotomas (3).

We report a case of spontaneous PVD in a patient previously with migraine with aura that developed secondary visual snow after the onset of the floaters and presented worsening of both frequency and intensity of the primary headache. The PVD was demonstrated with ultra-wide field (UWF) retinal imaging, a type of ophthalmological imaging that permits a wider view of the peripheral retina and adjacent structures of the eye (4). Migraine chronification was observed in strict relation to the onset of PVD and consequent retinal and occipital cortex hyperstimulation. Written informed consent was obtained from the patient for the publication of this case report.

Case Report

A 57-year-old woman evaluated in an outpatient setting reported the sudden onset of complex bright flashes that she described as large clusters of darkened and blinking stars filling her visual field, accompanied by dismorphous multicolored rays and progressive left-sided headache of severe intensity with a pattern similar to her migraine with aura, although the visual manifestations were distinct from her typical aura presentations. She used 100 mg of acetylsalicylic acid with headache improvement but without effect on the ocular symptoms, which persisted for about 3 hours and were replaced by floaters in the left eye with perception of residual photopsias. There were no alterations in the neurological examination and direct ophthalmoscopy showed no alterations with the retina. Complementary investigation with UWF retinal imaging demonstrated the presence of PVD in the left eye (Figure 1). The residual photopsias presented spontaneous resolution in the following 2 weeks with the floaters remaining after this period.

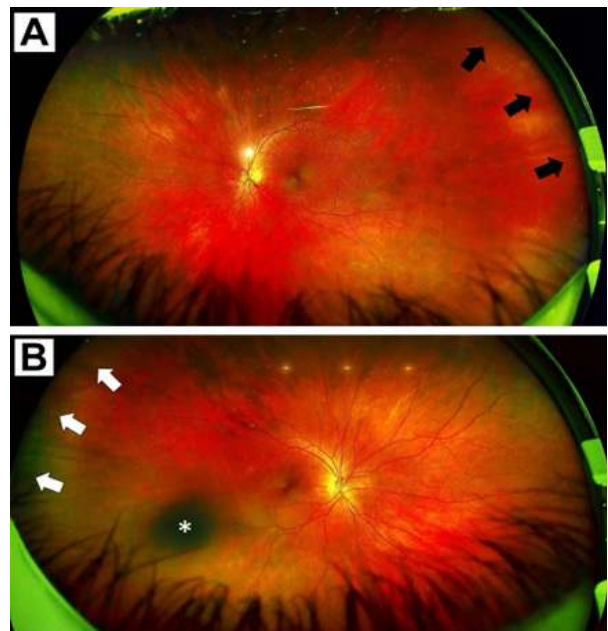


Figure 1. Ultra-wide field retinal imaging of both eyes after the left posterior vitreous detachment. (A) Left eye retinal imaging showing the extent of the posterior vitreous detachment (black arrows). (B) Right eye retinal imaging showing a cloudy nuclear focus of cataract on the lens (*) without posterior vitreous detachment at the time (white arrows). Both retinas showed no alterations or signs of detachment, being compatible with the previous neurological examination.



Her previous medical history included episodic migraine with visual aura since adolescence, sleep bruxism, cataract in the right eye and a transient ischemic attack that occurred 5 years before, involving partial amaurosis fugax lasting 8 minutes in the left eye. After investigation its etiology was defined as microembolization related to atheromatous plaques detected in the carotid arteries. She used acetylsalicylic acid 100 mg/day and rosuvastatin 10 mg/day with regular neurological follow-up ever since.

She maintained higher migraine frequency and intensity in the following year, progressing from 2 days of headache/month with response to simple analgesics and duration of less than 24 hours to 25 days/month with predominantly left unilateral headache in the parietal region, pulsating, associated with photophobia and nausea, worsening on movement, with intensification of associated symptoms of allodynia, neck pain radiating to the shoulders and fatigue, increased pain intensity from moderate to severe and increased duration of episodes if left untreated. It now required the combined use of paracetamol and dipyrone with caffeine and, if the crisis persists, a second dose of acetylsalicylic acid to present improvement, with analgesic use being considered an important marker of migraine progression. The main floaters remained on the left eye with greater discomfort with head movements, being occasionally accompanied by photophobia and bilateral impaired night vision, most noticeable during times of reading. She reported the coexistence of symptoms similar to small falling snow dots, transparent and moving, which seemed to subtly accompany the floaters, occurring in the vision of both eyes and contributing to the headache (Figure 2).




Figure 2. Illustration representing the visual symptoms reported after the left posterior vitreous detachment. (A) Symptoms in the left eye. Center: Representation of the main floaters that result in greater discomfort, perceived as large dark moving lines with undulating movements and whose color is close to gray. Background: Representation of subtle small dots similar to falling snow, transparent and moving. While zooming on the figure, it is also possible to observe a subtle static, something occasionally reported by the patient when observing details of objects. Finally, also in the background and accompanying the visual snow, there are small variable dark lines distinct from the main floaters, both

because of their size and for being less noticeable, which may be associated with secondary visual snow. (B) Symptoms in the right eye before the second posterior vitreous detachment. Center: Representation of a region of blurring related to the cataract. Background: Presence of bilateral symptoms of secondary visual snow and small discrete moving lines that also occur in the left eye.

After 5 months of the left PVD the patient also presented PVD in the right eye, this time with a slower onset lasting a few days and involving self-limited photopsias and distinct floaters. In this new episode there were also no alterations in the neurological examination and there was no retinal involvement, with the right PVD being confirmed by ophthalmological evaluation. After the right PVD she reported that symptoms similar to the main floaters with undulating movements in the left eye could also be observed moving independently in the right eye. After the right PVD both the bilateral additional visual symptoms and the severity of the migraine with aura maintained a similar pattern of worsening and chronification. The patient maintains regular follow-up with a neurologist and an ophthalmologist, being opted for the observation of the now bilateral PVD with periodic reassessments.

Discussion

A clinical condition known as visual snow syndrome (VSS) may present in comorbid form with migraine with aura, with visual snow (VS) being typically characterized by dynamic changes similar to static dots in the entire visual field that appear monochromatic, colored or transparent. Inflammatory fragments floating in the vitreous, such as those that occur after PVD, can anomalously stimulate retinal neurons and result in symptoms similar to VSS (5,6). Symptoms resembling those of migraine aura in spontaneous PVD cases may be related to electrical disturbances in the retina in the context of neuronal spreading depression, resulting in atypical complex visual changes that may lead to a combination of diagnoses between the two distinct pathologies (7).

The prevalence of VSS in the general population is estimated to range from 1.4% to 3.3%, with no difference between genders and with the trigger of positive and negative visual symptoms being generally associated with migraine with aura (8). In a retrospective case series evaluating 210 patients with VS with symptoms other than typical migraine aura, 42.38% (n=89) associated the onset of VS with a previous event, the most prevalent etiology being post-concussion in 7.14% (n=15). Ocular abnormalities were responsible for 3.33% (n=7) of the atypical cases. VS cases secondary to specific events had better prognosis than primary cases (9).

According to the diagnostic criteria of the ICHD-3, VSS is defined as the persistence of VS symptoms for



at least 3 months, at least 2 additional visual changes out of the following 4: palinopsia, enhanced entoptic phenomena (such as excessive floaters), photophobia and/or impaired night vision; and with the symptoms not being consistent with the typical visual aura of migraine (3). It is also necessary to exclude a secondary condition that may be acting as a mimic of a primary condition, identified by red flags such as sudden onset of exclusively unilateral symptoms or of only one quadrant of the visual field (6). The reported case presents a sum of symptoms of floaters, VS, photophobia and impaired night vision in the 4 months following the PVD, thus presenting criteria for VSS, but due to its secondary temporal association with a specific event its classification as secondary VS should be considered more adequate.

The evolution from episodic to chronic migraine may be related to mechanisms of cortical sensitization from an increase in retinal inputs on the occipital cortex leading to hypersensitivity of the parieto-occipito-hypothalamic tract (10). The functional alterations present in VSS also suggest that it is a pathology related to higher neural networks, which could be influenced by alterations in the perception of ocular stimuli over the mechanisms of image interpretation by the visual cortex (11). Considering the increase in frequency and severity of migraine with aura attacks of the patient after the PVD, it can be supposed that, in addition to the influence of hyperstimulation of retinal neurons, stressors experienced by the sudden change in visual perception may have intensified the superior nociceptive response of the trigeminal nucleus, thus collaborating with the process of migraine chronification.

Conclusion

We report a case of spontaneous PVD with development of secondary VS after the onset of floaters and worsening of frequency and severity of previous migraine with aura. This case indicates the importance of considering acute ocular abnormalities with the establishment of flashes and floaters and explores the development of secondary VS, an atypical clinical condition, after PVD, a process which may be related to the chronification of migraine.

João Guilherme Bochnia Küster
<https://orcid.org/0000-0002-1828-2726>
 Elcio Juliato Piovesan
<https://orcid.org/0000-0002-0915-0430>

References

1. Ramovecchi P, Salati C, Zeppieri M. Spontaneous posterior vitreous detachment: A glance at the current literature. *World J Exp Med* 2021;11:30–6. Doi:10.5493/wjem.v11.i3.30.
2. Kim Y-K, Moon SY, Yim KM, Seong SJ, Hwang JY, Park SP. Psychological Distress in Patients with Symptomatic Vitreous Floaters. *J Ophthalmol* 2017;2017:1–9. Doi:10.1155/2017/3191576.
3. Headache Classification Committee of the International Headache Society (IHS) The International Classification of Headache Disorders, 3rd edition. *Cephalalgia* 2018;38:1–211. Doi:10.1177/0333102417738202.
4. Kumar V, Surve A, Kumawat D, Takkar B, Azad S, Chawla R, et al. Ultra-wide field retinal imaging. *Indian J Ophthalmol* 2021;69:824–35. Doi:10.4103/ijo.IJO_1403_20.
5. Puledda F, Ffytche D, O'Daly O, Goadsby PJ. Imaging the Visual Network in the Migraine Spectrum. *Front Neurol* 2019;10. Doi:10.3389/fneur.2019.01325.
6. Hang C, Leishangthem L, Yan Y. Not All Cases of Visual Snows are Benign: Mimics of Visual Snow Syndrome. *Neuropsychiatr Dis Treat* 2021;Volume 17:3293–300. Doi:10.2147/NDT.S338111.
7. Coppeto JR. Migraine-like accompaniments of vitreous detachment. *Neuro-Ophthalmology* 1988;8:197–203. Doi:10.3109/01658108808996042.
8. Barral E, Martins Silva E, García-Azorín D, Viana M, Puledda F. Differential Diagnosis of Visual Phenomena Associated with Migraine: Spotlight on Aura and Visual Snow Syndrome. *Diagnostics* 2023;13:252. Doi:10.3390/diagnostics13020252.
9. Mehta DG, Garza I, Robertson CE. Two hundred and forty-eight cases of visual snow: A review of potential inciting events and contributing comorbidities. *Cephalalgia* 2021;41:1015–26. Doi:10.1177/0333102421996355.
10. Kamali A, Ghazi Sherbaf F, Rahmani F, Khayat-khoei M, Ain A, Gandhi A, et al. A direct visuosensory cortical connectivity of the human limbic system. Dissecting the trajectory of the parieto-occipito-hypothalamic tract in the human brain using diffusion weighted tractography. *Neurosci Lett* 2020;728:134955. Doi:10.1016/j.neulet.2020.134955.
11. Klein A, Schankin CJ. Visual Snow Syndrome as a Network Disorder: A Systematic Review. *Front Neurol* 2021;12. Doi:10.3389/fneur.2021.724072.

Author contributions: JGBK: Conceptualization, Data curation, Investigation, Project administration, Visualization, Writing – original draft, Writing – review & editing. EJP: Investigation, Project administration, Supervision, Validation, Writing – review & editing.



Conflict of Interest: No potential conflict of interest was reported by the authors.

Funding: The manuscript did not receive any type of funding. The authors have no disclosures relevant to the topic.