



Short-lasting unilateral neuralgiform headache attacks: case reports and review

André Luiz Vieira Lockmann¹, Iasmim Portela Maifrede¹, Mauro Eduardo Jurno², Luiz Paulo Bastos Vasconcelos¹

¹University Hospital, Federal University of Juiz de Fora, Juiz de Fora, Minas Gerais, Brazil

²Faculty of Medicine of Barbacena, José Bonifácio Lafayette de Andrada Foundation, Barbacena, Minas Gerais, Brazil



André Luiz Vieira Lockmann
andrelockmann@gmail.com

Edited by:

Marcelo Moraes Valença

Background

Short-lasting unilateral neuralgiform headache attacks are the rarest type of trigeminal-autonomic cephalalgias (TACs), typically classified into two subtypes: SUNCT (short-lasting unilateral neuralgiform headache attacks with conjunctival injection and tearing) and SUNA (with cranial autonomic symptoms). These disorders are characterized by brief, unilateral headache attacks accompanied by cranial parasympathetic symptoms and can be difficult to diagnose and manage in clinical practice.

Objective

To present two clinical cases of SUNCT and provide a comprehensive review of the current diagnostic criteria, pathophysiology, and treatment options, while distinguishing SUNCT/SUNA from other headache syndromes.

Methods

We describe two patients diagnosed with SUNCT at our outpatient headache clinic. A literature review was conducted focusing on clinical features, diagnostic criteria from the International Classification of Headache Disorders (ICHD-3), proposed pathophysiological mechanisms, and available treatment strategies.

Results

Both patients presented with multiple daily, short-lasting, unilateral headache attacks accompanied by cranial autonomic symptoms. Diagnostic workup ruled out secondary causes. The clinical presentation aligned with SUNCT criteria as defined in ICHD-3. Treatment approaches varied and included pharmacological interventions with partial symptom relief. The review highlights the challenges in differentiating SUNCT/SUNA from other headache disorders such as trigeminal neuralgia and cluster headache.

Conclusion

Accurate recognition of SUNCT/SUNA is essential for appropriate management, as misdiagnosis is common due to symptom overlap with other headache syndromes. Improved awareness and understanding of these rare conditions can lead to better diagnosis, targeted treatment, and patient outcomes.

Keywords:

SUNCT
SUNA
Trigeminal-autonomic cephalalgias
Headache diagnosis
Cranial autonomic symptoms

Received: February 12, 2025
Revised: March 21, 2025
Accepted: May 25, 2025



Introduction

Trigeminal-autonomic cephalalgias (TACs) are a group of headache disorders characterized by strictly unilateral pain in the trigeminal territory, which is often accompanied by cranial parasympathetic symptoms ipsilateral to the

pain side (1). Pathophysiologically, it has been suggested that TACs activate the trigeminal-parasympathetic reflex (schematically illustrated in Figure 1) (2).

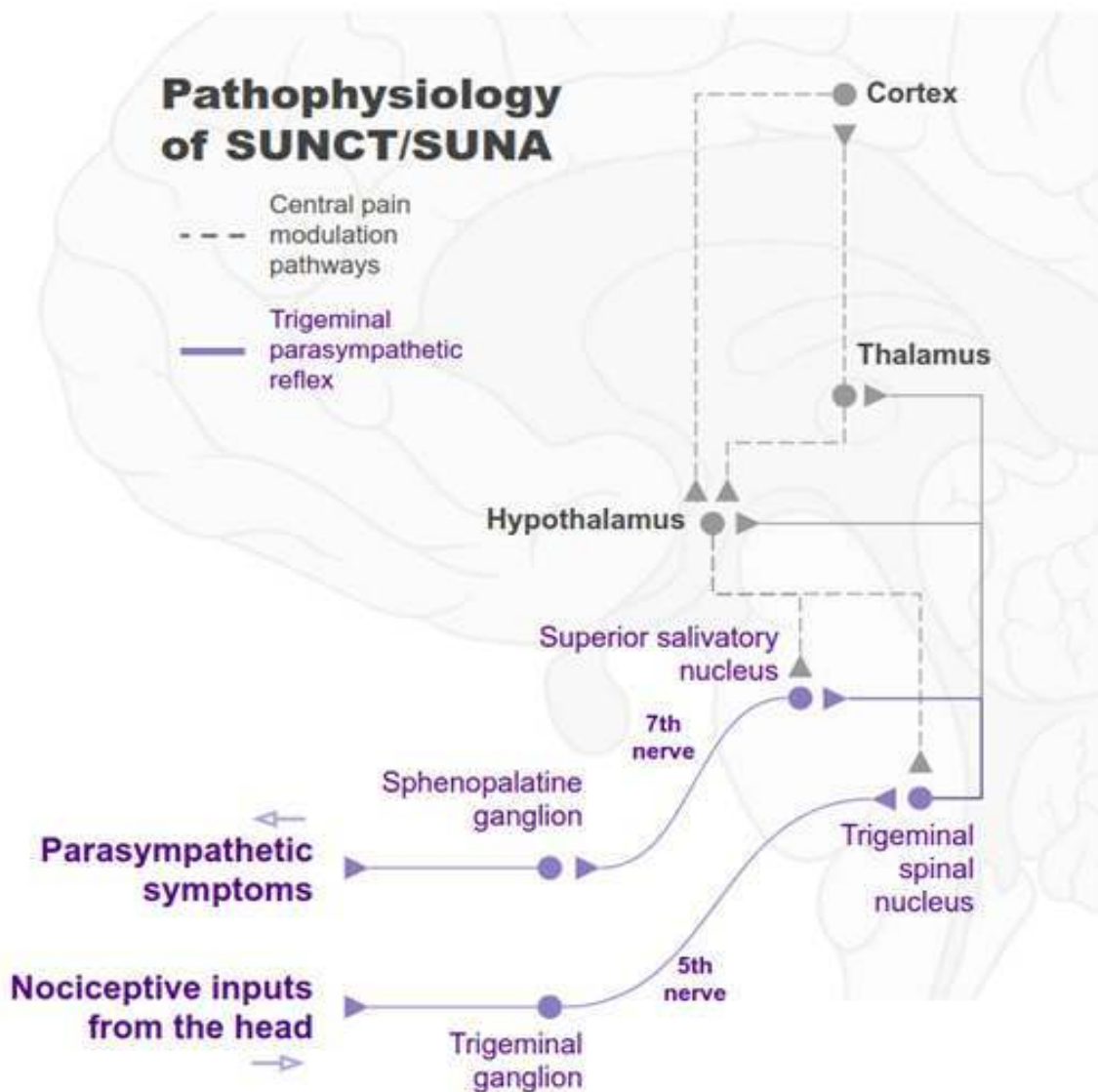


Figure 1. Trigeminal-parasympathetic reflex and central pain modulation pathways are abnormal in SUNCT/SUNA. A. Trigeminal-parasympathetic reflex. Afferents (purple): sensitive stimuli activate the peripheral fibers of the trigeminal ganglion (first-order sensitive neuron), which subsequently synapse on the brainstem trigeminal spinal nucleus (second-order sensitive neuron). Note that the trigeminal spinal nucleus projects to the thalamus (somatosensory pathway), hypothalamus (pain modulation pathway), and superior salivatory nucleus (parasympathetic efferent). Efferents (purple): superior salivatory nucleus (preganglionic parasympathetic neuron) synapse on the sphenopalatine ganglion (postganglionic parasympathetic neuron). The neurons in the sphenopalatine ganglion activate cranial smooth muscle and glands (e.g., lacrimal glands, nasal mucosa) to drive the parasympathetic symptoms typical of SUNCT/SUNA attacks. Central modulation pathways (grey): the hypothalamus interconnects to cortical circuitry that processes pain information (anterior cingulate, insula, somatosensory cortex) and sends top-down projections to modulate the trigeminal and parasympathetic brainstem neurons.



The third edition of the International Classification of Headache Disorders (ICHD-3) defines four types of TACs: short-lasting unilateral neuralgiform headache attacks (SUNCT/SUNA), paroxysmal hemicrania, cluster headache, and hemicrania continua (3,4).

These types differ in their pain characteristics, including the duration and frequency of pain episodes, pain triggers, and how well they respond to specific medications (3). See Figure 2 for comparison between TACs.

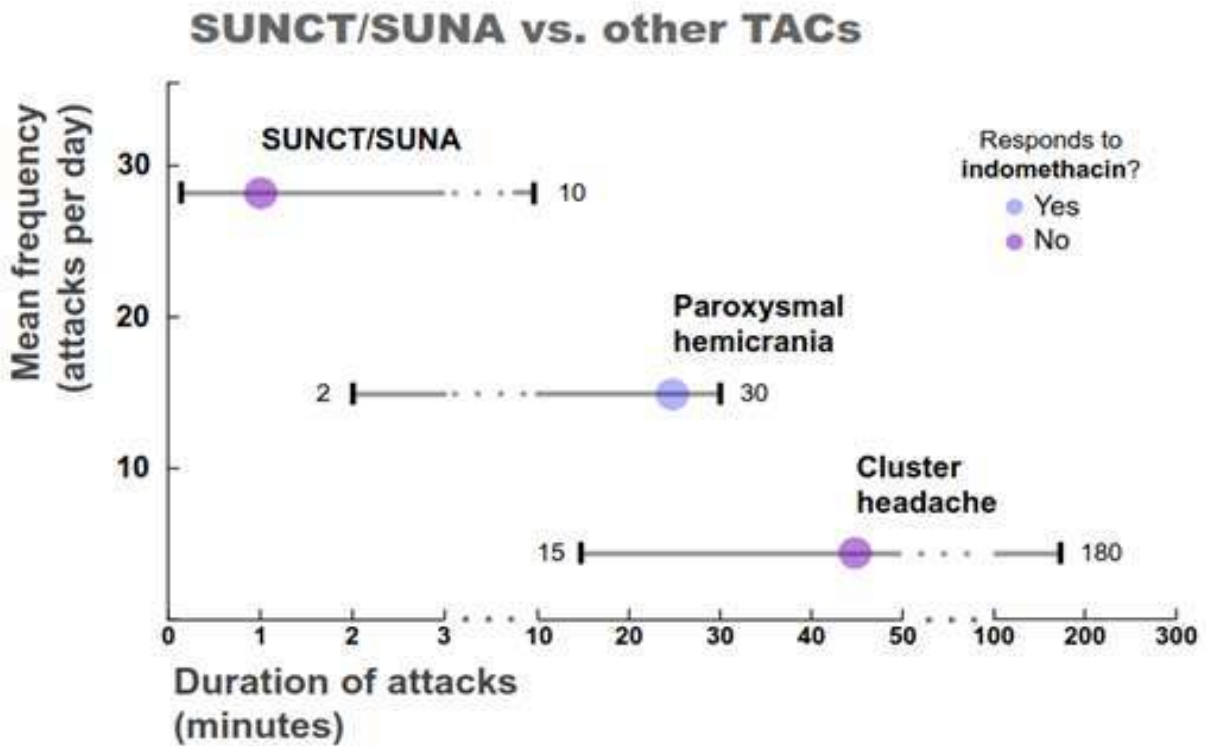


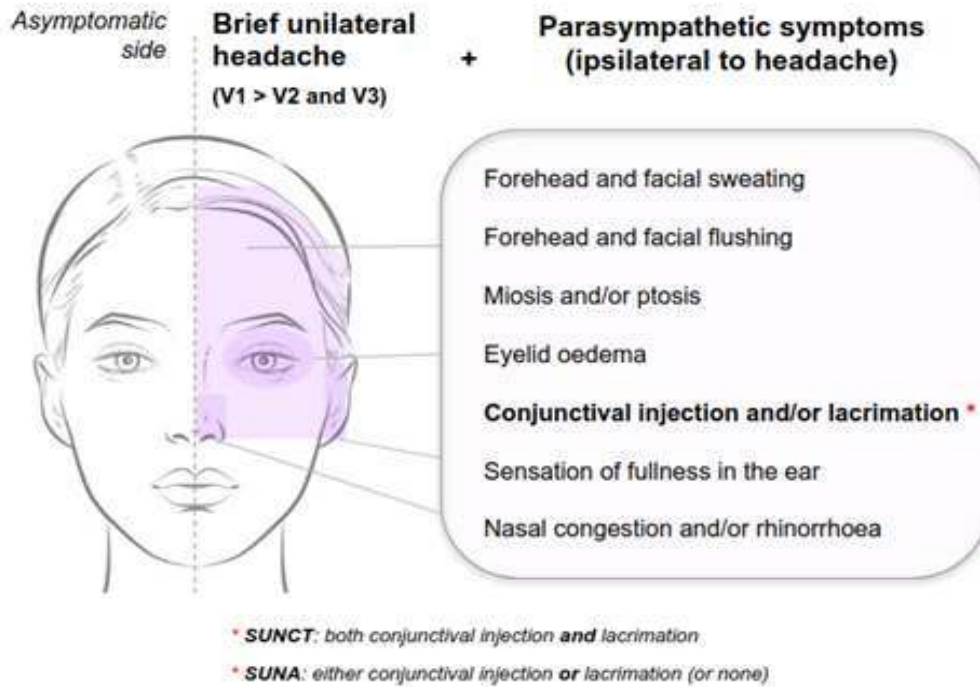
Figure 2. Clinical features of SUNCT/SUNA in comparison to other trigeminal-autonomic cephalalgias. SUNCT/SUNA has shorter and more frequent pain episodes, as compared to other TACs. Hemicrania continua is not depicted, since it consists of continuous pain with occasional exacerbations. Purple circles represent the mean frequency and duration of attacks, as reported by Diener et al. (5). Grey bars represent the duration range of the attacks, as defined by ICHD-3. Of note, TACs have some overlap in their duration range.

SUNCT/SUNA attacks are brief, lasting from 1 to 600 seconds, and present as unilateral headaches localized to areas innervated by the trigeminal nerve, mainly its V1 subdivision. The pain is moderate to severe in intensity and has a stabbing or saw-tooth quality (6). Figure 3

depicts the semiological characteristics of SUNCT/SUNA pain attacks. Each pain episode must also include at least one cranial parasympathetic symptom occurring on the same side as the pain. Commonly, facial stimuli would trigger an attack, but spontaneous episodes can also occur.



A Symptoms of SUNCT/SUNA



B Headache types in SUNCT/SUNA

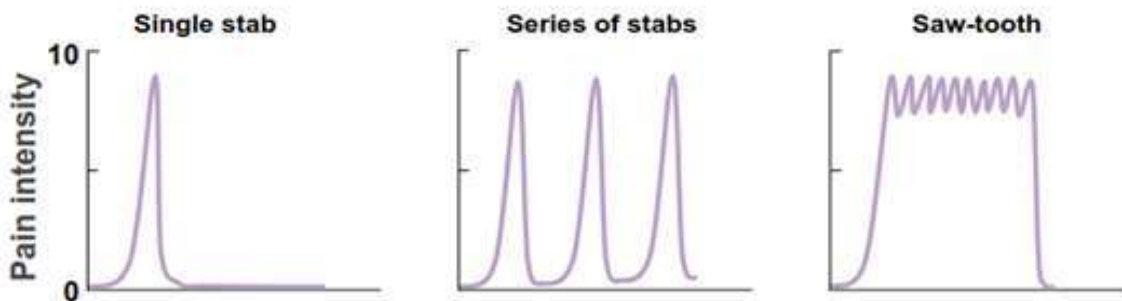


Figure 3. Symptomatology of SUNCT/SUNA attacks. A. SUNCT/SUNA attacks are short episodes of unilateral pain that primarily affect the trigeminal V1 regions (orbital, supraorbital, and temporal areas, as depicted in the pink area) and are associated with several parasympathetic symptoms in the same region. ICHD-3 requires that at least one of the seven key autonomic symptoms (listed in the figure) may be present to define SUNCT/SUNA. The definition of SUNCT or SUNA depends on how conjunctival injection and/or lacrimation presents. B. SUNCT/SUNA attacks can occur in three types: single stabs, a series of stabs, or saw-tooth (a longer attack in which the pain does not return to the baseline between repetitive single stabs). Patients can present one or more types of attacks (6).

Note: Data from Cohen et al. (6).



According to the ICHD-3 criteria, to diagnose SUNCT/SUNA, a patient must experience a minimum of 20 typical attacks with a daily frequency. Both forms exhibit the same pain characteristics but differ in their autonomic symptom presentation, specifically regarding lacrimation and conjunctival injection (Figure 3). By definition, SUNCT must present with both lacrimation and conjunctival injection, while SUNA can present with either one or none of these symptoms.

ICHD-3 criteria for short-lasting unilateral neuralgiform headache attacks, SUNCT and SUNA

Short-lasting unilateral neuralgiform headache attacks

- A. At least 20 attacks fulfilling criteria B–D
- B. Moderate or severe unilateral head pain, with orbital, supraorbital, temporal and/or other trigeminal distribution, lasting for 1–600 seconds and occurring as single stabs, series of stabs or in a saw-tooth pattern
- C. At least one of the following five cranial autonomic symptoms or signs, ipsilateral to the pain:
 1. conjunctival injection and/or lacrimation
 2. nasal congestion and/or rhinorrhoea
 3. eyelid oedema
 4. forehead and facial sweating
 5. forehead and facial flushing
 6. sensation of fullness in the ear
 7. miosis and/or ptosis
- D. Occurring with a frequency of at least one a day
- E. Not better accounted for by another ICHD-3 diagnosis.

SUNCT

Attacks fulfill criteria for short-lasting unilateral

neuralgiform headache attacks and there are both ipsilateral to pain: 1. conjunctival injection and 2. lacrimation (tearing).

SUNA

Attacks fulfill criteria for short-lasting unilateral neuralgiform headache attacks and there are no more than one ipsilateral to pain: 1. conjunctival injection or 2. lacrimation (tearing).

SUNCT/SUNA is the rarest of TACs, with an estimated annual incidence of 1.2/100,000 and a prevalence of 6.6/100,000 (7). Since its first identification in 1978, our understanding of this disease has largely relied on case reports and series of cases, as there are currently no well-powered clinical trials available (8–12). Although ICHD-3 provides a clear clinical description of the disease, diagnosing SUNCT/SUNA can still be challenging. As demonstrated in the clinical cases reported below, misdiagnoses frequently occur, often with other types of TACs or facial pain syndromes (Table 1). This can result in a prolonged diagnostic journey and ineffective treatments until the correct diagnosis is established. In this report, we present two cases of SUNCT from our outpatient clinic and review the pathophysiology, diagnostic criteria, differential diagnoses, and treatment options.

Clinical case 1

A 54-year-old man presented to the neurology outpatient clinic with complaints of short-lasting headache attacks that had been recurrent over the past eight years. His medical history was significant only for the use of lithium at a dosage of 1,200 mg per day, prescribed for bipolar disorder. The localization and characteristics of the

Table 1. SUNCT/SUNA vs. other facial pain syndromes

	SUNCT/SUNA	Trigeminal neuralgia	Stabbing headache	Temporomandibular dysfunction
Location of maximal pain	Trigeminal areas (V1 > V2/V3)	Trigeminal areas (V2/V3 > V1)	Trigeminal and non-trigeminal areas	Face, temporal and preauricular regions
Duration	1–600 seconds	1–120 seconds	1–120 seconds	Variable
Frequency (daily attacks)	1–100	Variable, depending on triggers	1–40	Variable
Cranial autonomic symptoms	Pronounced	Absent or mild	Absent	Absent
Triggers	Cutaneous	Cutaneous	Absent	Jaw movement and temporalis muscle palpation
Refractory period	Absent	Present	Absent	Absent
1st line treatment	Lamotrigine	Carbamazepine	Indomethacin	Nonsteroidal anti-inflammatory drugs, physical therapy

Note: Data from Vale et al. (4)



headaches attacks had remained consistent throughout the years. He described the pain as brief (approximately one minute), of moderate to severe intensity (7/10 on the visual analogue scale), and resembling an electric shock (sometimes like needles and pins). The pain was always localized to the right temporal and retro-orbital regions. Each headache attack was accompanied by tearing and ocular hyperemia. Chewing and touching the right supraorbital region would trigger the pain. Initially, the headache attacks occurred 3 to 4 times per week, but their frequency increased recently. In the weeks leading up to his consultation, he reported experiencing 15 to 20 episodes of pain each day. His neurological examination was unremarkable. Fasting blood glucose levels, as well as renal and liver function tests, were normal. A brain magnetic resonance imaging scan also returned normal results. He had initially been diagnosed with trigeminal neuralgia a few months prior and had been treated with carbamazepine (400 mg per day for one year) and gabapentin (900 mg per day for two months) with mild improvement in his symptoms.

Based on this clinical presentation, we proposed that the diagnosis was SUNCT rather than trigeminal neuralgia. We started treatment with lamotrigine, gradually increasing the dose to 100 mg twice daily. During a follow-up two months later, the patient reported a significant improvement in both the frequency and intensity of their pain, experiencing only one mild headache episode throughout the entire period.

Clinical case 2

A 71-year-old male with a history of hypertension reported experiencing multiple daily headache episodes for the past eight years. He described the pain as lancinating, always localized in the left parietal region. The intensity was severe, rated as 10/10 on the visual analog scale, and the episodes lasted only a few seconds. These headaches were accompanied by autonomic symptoms on the left side of his face, including tearing, conjunctival hyperemia, and rhinorrhea. He denied experiencing any sudomotor or vascular changes, such as hyperemia or pallor. Over the past six years, his symptoms had worsened, with the pain extending to the gingival and mandibular regions. Recently, he noticed that the headaches were triggered by wearing dentures and chewing. Initially diagnosed with trigeminal neuralgia, he underwent a treatment trial with carbamazepine, which was later supplemented with gabapentin, but he found these treatments to be ineffective. Due to the poor response to the therapies for trigeminal neuralgia and the presence of significant autonomic symptoms, he was subsequently reclassified as having cluster headache. Verapamil was added to his treatment regimen but provided only mild relief from the headache. He also reported that oxygen therapy for acute headache attacks was ineffective. When he first presented to our outpatient clinic, he was taking three

different medications (carbamazepine, gabapentin, and verapamil) but still experienced unsatisfactory pain control, with an intensity rated at 7/10 on the visual analog scale.

Considering the short-duration neuralgiform characteristics of his pain and the marked autonomic symptoms (conjunctival hyperemia and lacrimation), we proposed a diagnosis of SUNCT. We prescribed lamotrigine, gradually increasing the dosage to 200 mg per day, while also reducing the doses of his other medications. He returned a few months later with a significant reduction in headache intensity, now rated at 2/10. This encouraged us to increase the lamotrigine dosage to 300 mg per day and to discontinue all other medications. Following this adjustment, the patient reported complete resolution of his pain episodes.

Discussion

The two clinical cases were typical of short-lasting unilateral neuralgiform headache attacks (SUNCT/SUNA), presenting as brief episodes of strictly unilateral headache accompanied by parasympathetic symptoms ipsilaterally. Both cases fulfilled the ICHD-3 diagnostic criteria.

SUNCT/SUNA is typically an idiopathic disorder, and ancillary tests often return normal results, as seen in our patients. However, there are rare cases where SUNCT/SUNA is secondary to structural lesions (13). The most common cause of secondary SUNCT/SUNA is neurovascular compression, which usually affects the trigeminal nerve and its entry point in the pons (14). The second most common cause is pituitary tumors, which can exert pressure on the cavernous sinus (15). Therefore, conducting a brain MRI is advisable after the diagnosis of SUNCT/SUNA, as some secondary causes respond well to specific treatments (16,17).

In the clinical cases we report, both patients received their correct diagnosis approximately eight years after the onset of their symptoms. Such a delay in diagnosing SUNCT/SUNA is not uncommon, probably because it is a rare condition, and its symptoms often overlap with those of other headache syndromes. Prior studies, such as Cohen et al. (6), reported a mean diagnostic delay of 7.1 years for SUNA and 6.7 years for SUNCT.

Differential diagnosis between SUNCT/SUNA and other TACs

The patient in clinical case 2 was initially diagnosed with cluster headache before receiving the correct diagnosis of SUNCT/SUNA. This situation highlights the importance of differentiating SUNCT/SUNA from other TACs. The four disorders within the TACs group — SUNCT/SUNA,



paroxysmal hemicrania, cluster headache, and hemicrania continua — share a similar clinical presentation of unilateral headache and cranial autonomic symptoms (3). Figure 2 illustrates the characteristics of the pain episodes in different TACs, including the duration and frequency of episodes. Remarkably, some overlap exists. Among TACs, SUNCT/SUNA is characterized by shorter pain episodes (lasting 1-600 seconds) that occur more frequently (ranging from 1 to 100 episodes per day). As also observed in case 2, SUNCT/SUNA is typically triggered by innocuous facial stimuli and would respond to treatment with lamotrigine.

In contrast, cluster headache episodes are significantly longer (lasting 15-180 minutes) and less frequent (occurring 1-8 times daily) and usually are triggered by alcohol ingestion rather than facial stimuli. Cluster headaches typically respond well to prophylactic treatment with verapamil, and exacerbations often improve with oxygen or sumatriptan (18). Whenever a patient diagnosed with TACs does not respond to the first-line medications - as seen in case 2, who only mildly responded to verapamil - it is crucial to reconsider the diagnosis.

TACs can be categorized into indomethacin-responsive headaches (paroxysmal hemicrania and hemicrania continua) and indomethacin-unresponsive headaches (cluster headache and SUNCT/SUNA). Specifically, paroxysmal hemicrania significantly overlaps in duration with SUNCT/SUNA (Figure 2). In such cases, a therapeutic trial with indomethacin may aid in differentiating between these disorders. Table 1 summarizes the most clinically relevant differences among TACs.

Differentiating SUNCT/SUNA from trigeminal neuralgia and other facial pain syndromes

In both clinical cases, the patients were referred to our outpatient clinic with a diagnosis of trigeminal neuralgia refractory to pharmacological treatment. Indeed, trigeminal neuralgia overlaps with SUNCT/SUNA in many aspects (Table 1). These two conditions present as brief episodes of unilateral headaches usually triggered by facial stimuli. Moreover, neuroimaging can reveal trigeminal neurovascular conflicts in both facial pain syndromes. As illustrated by case 2, SUNCT/SUNA may also respond to drugs traditionally used to treat trigeminal neuralgia, like carbamazepine and oxcarbazepine (19,20). Altogether, this evidence points to the possibility of a common pathophysiology in SUNCT/SUNA and trigeminal neuralgia (21).

In contrast to SUNCT/SUNA, trigeminal neuralgia has a shorter pain duration (less than 2 minutes), predominating in the trigeminal V2 and V3 regions, and is not accompanied by dysautonomia. Finally, trigeminal neuralgia is unique because it presents a refractory period between pain episodes (22), usually not seen in SUNCT/SUNA.

Stabbing headache may also present as brief lancinating pain in V1 territory, but lacks dysautonomia. Temporomandibular dysfunction rarely mimics SUNCT/SUNA. See Table 1 for differential diagnosis.

Peripheral pathophysiology: the role of the trigeminal-parasympathetic reflex

In SUNCT/SUNA, headache attacks and dysautonomia simultaneously occur, which could be explained by abnormal activation of the brainstem trigeminal-parasympathetic reflex (Figure 1) (2). The peripheral endings from the trigeminal ganglion (first-order sensitive neurons) transmit nociceptive information and synapse on the trigeminal spinal nucleus located in the brainstem. These second-order brainstem neurons transmit pain signals to the thalamus and send collaterals to the superior salivatory nucleus, which contains preganglionic parasympathetic neurons. This initiates autonomic responses, such as conjunctival injection and lacrimation (23).

Physiologically, this reflex has a protective function and should be triggered only by noxious stimuli (23). In SUNCT/SUNA and other TACs, activation of the reflex arc by innocuous stimuli indicates hyper-excitability. Clinical cases 1 and 2 illustrate that, in SUNCT/SUNA, headaches could be triggered by stimuli like touching the face, chewing, and wearing dentures. The most common triggers in SUNCT/SUNA are touching the face, chewing, winding, washing the face, and brushing the teeth. Usually, patients with SUNCT/SUNA would present both triggered and spontaneous attacks (6).

Trigeminal compression by vascular loops can cause SUNCT/SUNA symptomatology ipsilaterally (14), and some patients diagnosed with SUNCT/SUNA benefit from microvascular decompression (24), supporting a peripheral pathophysiological mechanism. However, other patients did not improve after decompressive surgery, pointing out that an additional central mechanism may play a role (25).

Central pathophysiology: the role of the hypothalamus

It has been suggested that descending projections from higher-order pain processing circuits control the flow of information through the trigeminal-autonomic reflex (2). Specifically, a descending hypothalamic-trigeminal pathway (Figure 1) connects the posterior hypothalamus to the ipsilateral trigeminal brainstem neurons (25). Interestingly, functional magnetic resonance imaging showed that SUNCT episodes correlate with abnormal activation of the posterior hypothalamus and other brain regions involved in pain processing, like the thalamus, anterior cingulate cortex, and insula (26-28).

The orexins A and B, synthesized in the posterior hypothalamus, can modulate the activity of peripheral pain and autonomic circuits. In a series of experiments in rats, it



has been demonstrated that microinjections of orexin B in the posterior hypothalamus increased the activity of trigeminal brainstem neurons. Contrarily, orexin A decreased neuronal activity in this region (29). Therefore, the overproduction of orexin B by a dysfunctional hypothalamus is a putative mechanism for central disinhibition of the trigeminal-parasympathetic reflex in SUNCT/SUNA (2).

Some patients diagnosed with intractable pain from SUNCT/SUNA have been successfully treated with deep brain stimulation of the posterior hypothalamus (30). Additionally, clomiphene citrate - an ovulatory stimulant that binds to hypothalamic estrogen receptors - completely alleviated SUNCT/SUNA episodes in one patient (31). This evidence further supports the modulatory role of the hypothalamus in the pathophysiology of SUNCT/SUNA.

Treatment

The management of SUNCT/SUNA focuses on preventing pain attacks (see Figure 4). We recommend following the algorithm developed by Lambru et al. (19), which is based on a cohort of 161 patients - the largest series of SUNCT/SUNA cases to date - and a meta-analysis of five additional studies (7,12,20,32,33).

Lamotrigine is the first-line treatment for SUNCT/SUNA. It was equally effective in SUNCT and SUNA, and improved headaches in 56% of patients (19). The dosage should be increased until the patient achieves satisfactory pain control, up to the maximum dosage of 700 mg per day. It is advisable to titrate lamotrigine slowly to avoid adverse effects. Treatment failure is considered if a patient does not improve after maximum doses. If a patient does not

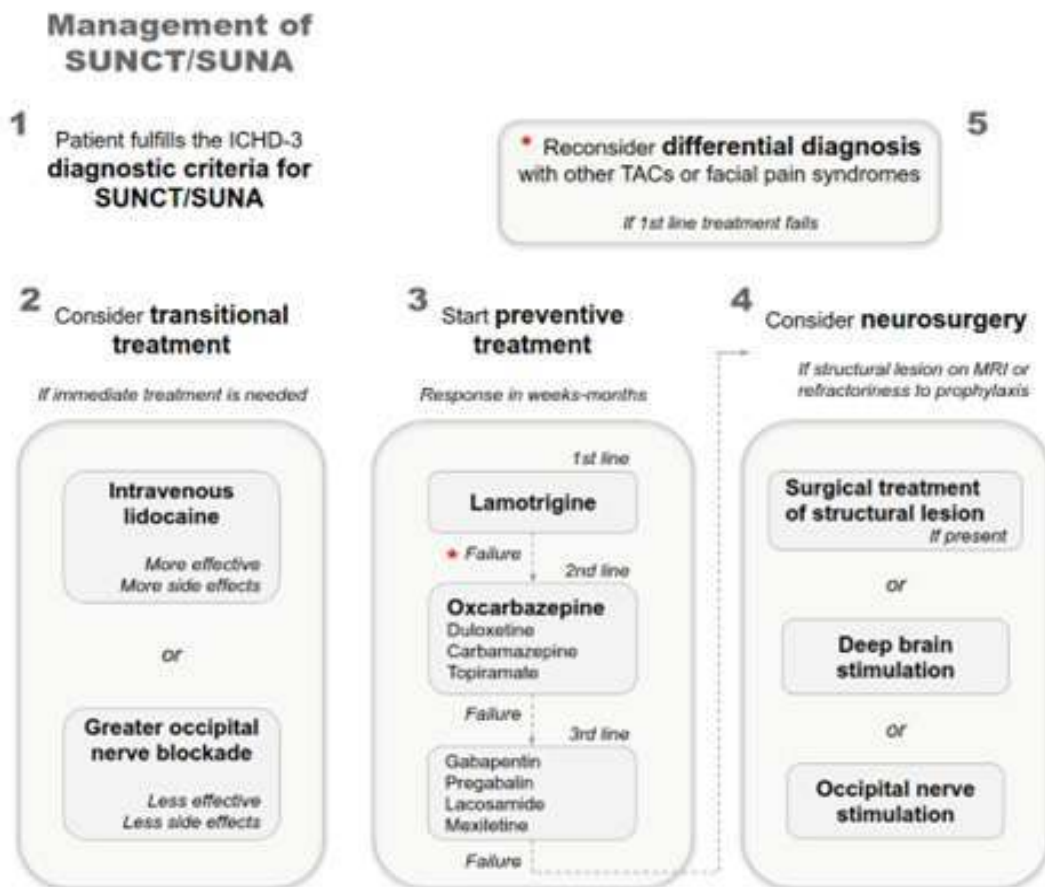


Figure 4. Management of SUNCT/SUNA. Once SUNCT/SUNA is diagnosed, we should conduct a brain MRI to investigate secondary causes (step 1). Consider transitional treatment (step 2) if pain is disabling and needs immediate treatment at the moment of evaluation. Start preventive treatment (step 3). It may take several weeks to months to titrate preventive medications for adequate pain control. Lamotrigine is the treatment of choice in SUNCT/SUNA. If the response to lamotrigine is unsatisfactory, the preferred second-line medication is oxcarbazepine, either as a substitute or an add-on to lamotrigine. Third-line treatments could help as adjunctive therapies. If brain MRI returns abnormalities known to cause SUNCT/SUNA, consider surgical treatment (step 4). Other invasive treatments, like deep brain stimulation or occipital nerve stimulation, are an option in refractory patients (step 4). SUNCT/SUNA usually responds well to pharmacological treatments. Whenever a patient fails to respond to the first-line treatment, reconsider the possibility of other diagnostic mimicking SUNCT/SUNA (step 5), like other TACs or facial pain syndromes (Table 1).



respond to lamotrigine, we should always reconsider other diagnoses that could mimic SUNCT/SUNA (Table 1).

Oxcarbazepine (up to 2,400/day) is the preferred second-line treatment, either as a substitute or an add-on to the first-line treatment. It should be considered if a patient is intolerant to or fails in the treatment with lamotrigine. Other less effective options as second-line treatments are duloxetine, carbamazepine, and topiramate. Notably, SUNA is poorly responsive to topiramate.

Third-line treatments are less effective but are helpful as adjunct therapies in refractory patients. These include gabapentin, pregabalin, lacosamide, and mexiletine. Pain improvement with monoclonal antibodies (34) and botulinum toxin (35) has been reported. Patients who maintain refractory to pharmacological treatment or present a structural lesion on neuroimaging should be referred for surgical evaluation.

Preventive treatments, like lamotrigine or oxcarbazepine, may take several weeks to achieve its effects. If immediate treatment is needed, transitional treatments are faster at suppressing the attacks. Intravenous (IV) lidocaine at a dose of 1–4 mg/min (maximum rate 3.4 mg/kg/hour) given for 7 days is the most effective short-term prophylaxis. One should be extremely cautious about contra-indications and side effects when using IV lidocaine. A loading dose (1 mg/kg over 15 min) is optional, depending on the severity of the symptoms. During infusion, patients must be continuously monitored for side effects. See Matharu et al. (36) for detailed protocol of IV lidocaine infusion. Another option for short-term prophylaxis is blocking the greater occipital nerve with a mixture of methylprednisolone 80 mg and 2 mL of 2% lidocaine injected in the suboccipital area (37). Greater occipital nerve blockade is safe, but headache improves in only 31% of patients, compared to 94% of patients treated with IV lidocaine (19). Figure 4 summarizes the management of SUNCT/SUNA.

In our case reports, both patients significantly responded to lamotrigine, supporting the correct diagnosis of SUNCT/SUNA. In case 1, the patient mildly improved with carbamazepine and gabapentin, demonstrating the role of these medications as adjunct therapies. In case 2, the patient had some improvement with verapamil, which has also been reported previously in a single case (38), suggesting a possible pathophysiological overlap with cluster headache.

Conclusion

SUNCT/SUNA is a diagnosis to keep in mind when dealing with headaches that are brief and unilateral. Asking about autonomic symptoms is crucial, as it could significantly narrow differential diagnoses. The correct diagnosis is

usually delayed, leading physicians to prescribe ineffective medications for several years. When SUNCT/SUNA is diagnosed, treatment with lamotrigine can significantly improve the symptoms and quality of life of patients.

References

1. Matharu MS, Goadsby PJ. Trigeminal autonomic cephalgias. *J Neurol Neurosurg Psychiatry* 2002;72 Suppl 2:ii19–26. Doi:10.1136/jnnp.72.suppl_2.ii19.
2. Leone M, Bussone G. Pathophysiology of trigeminal autonomic cephalgias. *Lancet Neurol* 2009;8:755–64. Doi:10.1016/S1474-4422(09)70133-4.
3. Headache Classification Committee of the International Headache Society (IHS) The International Classification of Headache Disorders, 3rd edition. *Cephalalgia* 2018;38:1–211. Doi:10.1177/0333102417738202.
4. Vale T, Pedroso J, Barsottini O. *Guia de Bolso de Neurologia*. 1st ed. São Paulo: Editora Atheneu; 2018.
5. Diener HC, Tassorelli C, Dodick DW. Management of Trigeminal Autonomic Cephalgias Including Chronic Cluster. *JAMA Neurol* 2023;80:308. Doi:10.1001/jamaneurol.2022.4804.
6. Cohen AS. Short-lasting unilateral neuralgiform headache attacks with conjunctival injection and tearing (SUNCT) or cranial autonomic features (SUNA)--a prospective clinical study of SUNCT and SUNA. *Brain* 2006;129:2746–60. Doi:10.1093/brain/awl202.
7. Williams MH, Broadley SA. SUNCT and SUNA: Clinical features and medical treatment. *Journal of Clinical Neuroscience* 2008;15:526–34. Doi:10.1016/j.jocn.2006.09.006.
8. Lambrou G, Rantell K, Levy A, Matharu MS. A prospective comparative study and analysis of predictors of SUNA and SUNCT. *Neurology* 2019;93. Doi:10.1212/WNL.0000000000008134.
9. Zhang S, Cao Y, Yan F, Chen S, Gui W, Hu D, et al. Similarities and differences between SUNCT and SUNA: a cross-sectional, multicentre study of 76 patients in China. *J Headache Pain* 2022;23:137. Doi:10.1186/s10194-022-01509-6.
10. Sjaastad O, Saunte C, Salvesen R, Fredriksen T, Seim A, Roe O, et al. Shortlasting, Unilateral Neuralgiform Headache Attacks with Conjunctival Injection, Tearing, Sweating, and Rhinorrhea. *Cephalalgia* 1989;9:147–56. Doi:10.1046/j.1468-2982.1989.0902147.x.
11. Hagen K. One-year prevalence of cluster headache, hemicrania continua, paroxysmal hemicrania and SUNCT in Norway: a population-based nationwide registry study. *J Headache Pain* 2024;25:30. Doi:10.1186/s10194-024-01738-x.
12. Cação G, Correia FD, Pereira-Monteiro J. SUNCT syndrome: A cohort of 15 Portuguese patients. *Cephalalgia* 2016;36:1002–6. Doi:10.1177/0333102415620252.
13. Cao Y, Yang F, Dong Z, Huang X, Cao B, Yu S. Secondary Short-Lasting Unilateral Neuralgiform Headache with



- Conjunctival Injection and Tearing: A New Case and a Literature Review. *Journal of Clinical Neurology* 2018;14:433. Doi:10.3988/jcn.2018.14.4.433.
14. Favoni V, Grimaldi D, Pierangeli G, Cortelli P, Cevoli S. SUNCT/SUNA and neurovascular compression: New cases and critical literature review. *Cephalalgia* 2013;33:1337–48. Doi:10.1177/0333102413494273.
 15. Chitsantikul P, Becker WJ. SUNCT, SUNA and pituitary tumors: Clinical characteristics and treatment. *Cephalalgia* 2013;33:160–70. Doi:10.1177/0333102412468672.
 16. Guerreiro R, Casimiro M, Lopes D, Marques JP, Fontoura P. Video NeuroImage: Symptomatic SUNCT syndrome cured after trigeminal neurovascular contact surgical decompression. *Neurology* 2009;72. Doi:10.1212/01.wnl.0000342483.46328.1a.
 17. Rozen TD. Resolution of SUNCT after removal of a pituitary adenoma in mild acromegaly. *Neurology* 2006;67:724–724. Doi:10.1212/01.wnl.0000230158.71122.78.
 18. Hoffmann J, May A. Diagnosis, pathophysiology, and management of cluster headache. *Lancet Neurol* 2018;17:75–83. Doi:10.1016/S1474-4422(17)30405-2.
 19. Lambru G, Stubberud A, Rantell K, Lagrata S, Tronvik E, Matharu MS. Medical treatment of SUNCT and SUNA: a prospective open-label study including single-arm meta-analysis. *J Neurol Neurosurg Psychiatry* 2021;92:233–41. Doi:10.1136/jnnp-2020-323999.
 20. Weng H-Y, Cohen AS, Schankin C, Goadsby PJ. Phenotypic and treatment outcome data on SUNCT and SUNA, including a randomised placebo-controlled trial. *Cephalalgia* 2018;38:1554–63. Doi:10.1177/0333102417739304.
 21. Lambru G, Matharu MS. SUNCT, SUNA and trigeminal neuralgia. *Curr Opin Neurol* 2014;27:325–31. Doi:10.1097/WCO.0000000000000090.
 22. Lambru G, Zakrzewska J, Matharu M. Trigeminal neuralgia: a practical guide. *Pract Neurol* 2021;21:392–402. Doi:10.1136/practneurol-2020-002782.
 23. Möller M, May A. The unique role of the trigeminal autonomic reflex and its modulation in primary headache disorders. *Curr Opin Neurol* 2019;32:438–42. Doi:10.1097/WCO.0000000000000691.
 24. Gardella L, Viruega A, Rojas H, Nagel J. A Case of a Patient with SUNCT Syndrome Treated with Jannetta Procedure. *Cephalalgia* 2001;21:996–9. Doi:10.1046/j.1468-2982.2001.00252.x.
 25. Malick A, Strassman RM, Burstein R. Trigeminothalamic and Reticulothalamic Tract Neurons in the Upper Cervical Spinal Cord and Caudal Medulla of the Rat. *J Neurophysiol* 2000;84:2078–112. Doi:10.1152/jn.2000.84.4.2078.
 26. Sprenger T, Valet M, Platzer S, Pfaffenrath V, Steude U, Tolle TR. SUNCT: bilateral hypothalamic activation during headache attacks and resolving of symptoms after trigeminal decompression. *Pain* 2005;113:422–6. Doi:10.1016/j.pain.2004.09.021.
 27. Cohen A. Short-Lasting Unilateral Neuralgiform Headache Attacks with Conjunctival Injection and Tearing. *Cephalalgia* 2007;27:824–32. Doi:10.1111/j.1468-2982.2007.01352.x.
 28. May A, Bahra A, Büchel C, Turner R, Goadsby PJ. Functional magnetic resonance imaging in spontaneous attacks of SUNCT: Short-lasting neuralgiform headache with conjunctival injection and tearing. *Ann Neurol* 1999;46:791–4. Doi:10.1002/1531-8249(199911)46:5<791::AID-ANA18>3.0.CO;2-8.
 29. Bartsch T, Levy MJ, Knight YE, Goadsby PJ. Differential modulation of nociceptive dural input to [hypocretin] orexin A and B receptor activation in the posterior hypothalamic area. *Pain* 2004;109:367–78. Doi:10.1016/j.pain.2004.02.005.
 30. Leone M, Franzini A, D'Andrea G, Broggi G, Casucci G, Bussone G. Deep brain stimulation to relieve drug-resistant SUNCT. *Ann Neurol* 2005;57:924–7. Doi:10.1002/ana.20507.
 31. Rozen TD. Complete alleviation of treatment refractory primary SUNCT syndrome with clomiphen citrate (a medicinal deep brain hypothalamic modulator). *Cephalalgia* 2014;34:1021–4. Doi:10.1177/0333102414527647.
 32. D'Andrea G, Granella F, Ghiotto N, Nappi G. Lamotrigine in the treatment of SUNCT syndrome. *Neurology* 2001;57:1723–5. Doi:10.1212/WNL.57.9.1723.
 33. Etemadifar M, Maghzi A, Ghasemi M, Chitsaz A, Esfahani MK. Efficacy of Gabapentin in the Treatment of SUNCT Syndrome. *Cephalalgia* 2008;28:1339–42. Doi:10.1111/j.1468-2982.2008.01673.x.
 34. Bsteh G, Bsteh C, Broessner G. Refractory short-lasting unilateral neuralgiform headache attacks with conjunctival injection and tearing responsive to anti-calcitonin gene-related peptide monoclonal antibodies: A case report. *Cephalalgia* 2021;41:127–30. Doi:10.1177/0333102420954558.
 35. Zabalza RJ. Sustained response to botulinum toxin in SUNCT syndrome. *Cephalalgia* 2012;32:869–72. Doi:10.1177/0333102412452045.
 36. Matharu M, Cohen A, Goadsby P. SUNCT Syndrome Responsive to Intravenous Lidocaine. *Cephalalgia* 2004;24:985–92. Doi:10.1111/j.1468-2982.2004.00886.x.
 37. Lambru G, Abu Bakar N, Stahlhut L, McCulloch S, Miller S, Shanahan P, et al. Greater occipital nerve blocks in chronic cluster headache: a prospective open-label study. *Eur J Neurol* 2014;21:338–43. Doi:10.1111/ene.12321.
 38. Narbone M, Gangemi S, Abbate M. A Case of SUNCT Syndrome Responsive to Verapamil. *Cephalalgia* 2005;25:476–8. Doi:10.1111/j.1468-2982.2004.00876.x.



André Luiz Vieira Lockmann
<https://orcid.org/0000-0002-1456-4689>
Iasmim Portela Maifrede
<https://orcid.org/0000-0002-0371-3386>
Mauro Eduardo Jurno
<https://orcid.org/0000-0002-8743-9395>
Luiz Paulo Bastos Vasconcelos
<https://orcid.org/0000-0003-4397-7172>

Authors contribution: All authors contributed equally to the article.

Conflict of interest: We declare no conflicts of interest.

Funding: We have not received significant financial support.