▪ Headache Medicine 2024, 15(4): 317-321 ▪ p-ISSN 2178-7468, e-ISSN 2763-6178

Headache Medicine

▪ DOI: 10.48208/HeadacheMed.2024.52

Short communication

From surgical morphology to microscopy anatomy: visualizing choroid plexus and its role in headache research

Juliana Ramos de Andrade, Carolina Martins, Marcelo Moraes Valença

Federal University of Pernambuco, Recife, Pernambuco, Brazil

Marcelo Moraes Valença
mmvalenca@yahoo.com.br

Edited by:
Mario Fernando Prieto Peres

Abstract

The choroid plexus (ChP) is pivotal in cerebrospinal fluid (CSF) production, intracranial pressure regulation, and brain homeostasis, intricately linked to headache pathophysiology. This study integrates macroscopic, microsurgical, and microstructural analyses to explore the anatomy and function of the ChP, highlighting its structural and functional significance.

Methods

Macroscopic and microsurgical dissections were performed on cadaveric specimens, with arteries and veins injected with colored silicone to enhance visualization. Microstructural analysis was conducted using scanning electron microscopy to reveal detailed surface morphology.

Results

The ChP in the lateral ventricles exhibits a characteristic C-shaped configuration, attached to the taenia along the choroidal fissure, a critical surgical landmark. Microsurgical views emphasize the ChP at the interventricular foramen, a key region frequently encountered during neurosurgical procedures. The ChP's luminal surface displays intricate architecture, including villi, microvilli, cilia, and interdigitations, reflecting its active role in CSF dynamics.

Conclusions

These findings underscore the ChP's specialized surface features and cellular organization, which are fundamental for maintaining CSF homeostasis and regulating intracranial pressure. Disruptions in ChP morphology or function could contribute to headache development, particularly in conditions associated with CSF flow and pressure dysregulation. By bridging macroscopic neuroanatomy, microsurgical techniques, and ultrastructural insights, this study lays the groundwork for future research into the ChP's involvement in headache pathophysiology and its potential as a therapeutic target. Exploring this vital yet underexplored structure in neuroscience offers promising avenues for advancing our understanding of neurological disorders.

Keywords:
Choroid plexus
Cerebrospinal fluid (CSF)
Headache pathophysiology
Intracranial pressure
Microsurgical neuroanatomy
Scanning electron microscopy

Submitted: December 24, 2024
Accepted: December 29, 2024
Published online: December 31, 2024

© Copyright 2024

Introduction

The choroid plexus (ChP) is critical in cerebrospinal fluid (CSF) production and intracranial pressure regulation, processes closely linked to headache pathophysiology. The name "choroid plexus" originates from Greek and Latin roots: (1) "Choroid", derived from the Greek word chorion (χορίον), which means "membrane" or "skin. "It was historically used to describe vascular membranes, reflecting the richly vascularized nature of this structure.; and (2) "Plexus", from the Latin word *plexus*, meaning "interwoven" or "network," referring to the intricate network of blood vessels and epithelial cells that form the choroid plexus. Together, "choroid plexus" describes a vascular, membranous network involved in producing cerebrospinal fluid (CSF) and playing a role in the brain's homeostasis.

This study explores the ChP's macroscopic, microsurgical, and microstructural anatomy, offering insights into its structural and functional significance (1–17). By integrating anatomical and microscopic perspectives, this study bridges gaps across disciplines, establishing a foundation for future research into the ChP's involvement in headache pathophysiology and its potential as a therapeutic target.

These findings provide novel insights into the structural and functional roles of this vital yet underexplored structure in neuroscience. This study presents detailed macroscopic and microsurgical anatomy, as well as microstructural observations, aiming to enhance our understanding of the ChP and its significance in the context of headache research.

Methods

Cadaveric specimens were utilized to explore the macroscopic, microsurgical, and microstructural anatomy of the choroid plexus (ChP). For macroscopic and microsurgical dissections, arteries and veins were injected with colored silicone to enhance visualization of the vascular network and structural organization. To examine microstructural details, ChP samples were obtained from cadaveric donors, processed for scanning electron microscopy, and qualitatively assessed for morphological differences.

Results and Discussion

The anatomy of the ChP in the human lateral ventricle is presented through microsurgical dissections of cadaveric specimens, whose arteries and veins, after fixation, have been injected with colored silicone. Injection, dissection and picturing were accomplished by the second author (CM), following the Rhotonian tenets, perfected at the George Schrader-Colter International Microsurgical Neuroanatomical Lab (Gainesville (1), US). The ChP in the lateral ventricles exhibits a C-shape, attached to the taenia on the thalamic and forniceal sides, it conforms to the choroidal fissure (Figure 1). Microsurgical views highlight the ChP at critical locations, such as the area of the interventricular foramen, a point from which it is frequently encountered during surgical procedures.

The choroid plexus (ChP) has gained attention in neuroanatomy (both macroscopic and microsurgical neuroanatomy) and neuroscience due to its critical role in cerebrospinal fluid (CSF) production and its influence on intracranial pressure regulation. These processes are intricately linked to the pathophysiology of headaches, particularly those associated with CSF flow alterations. Studies investigating the morphology of the ChP offer valuable insights into its role in these mechanisms, providing a foundation for understanding how structural and functional characteristics of this unique structure contribute to neurological conditions.

The findings emphasize the ChP's specialized architecture and cellular organization, which are essential for maintaining CSF homeostasis and intracranial pressure regulation. Morphological or functional disruptions in this complex structure could contribute to headache development or exacerbation.

Microstructural examination using scanning electron microscopy (SEM) reveals the intricate surface morphology of the ChP. The microstructural aspects of the ChP in this area are presented using standardized SEM protocols, which disclose its characteristic structures. SEM imaging uncovers villi, microvilli, invaginations, and vesicles (or interdigitations) that define its luminal surface. The epithelial layer, prominently covered by microvilli, displayed distinct apical portions and the presence of cilia, indicative of its active role in CSF dynamics (Figure 2). These detailed observations provide a comprehensive depiction of the ChP's ultrastructure, underscoring its significance in CSF dynamics.

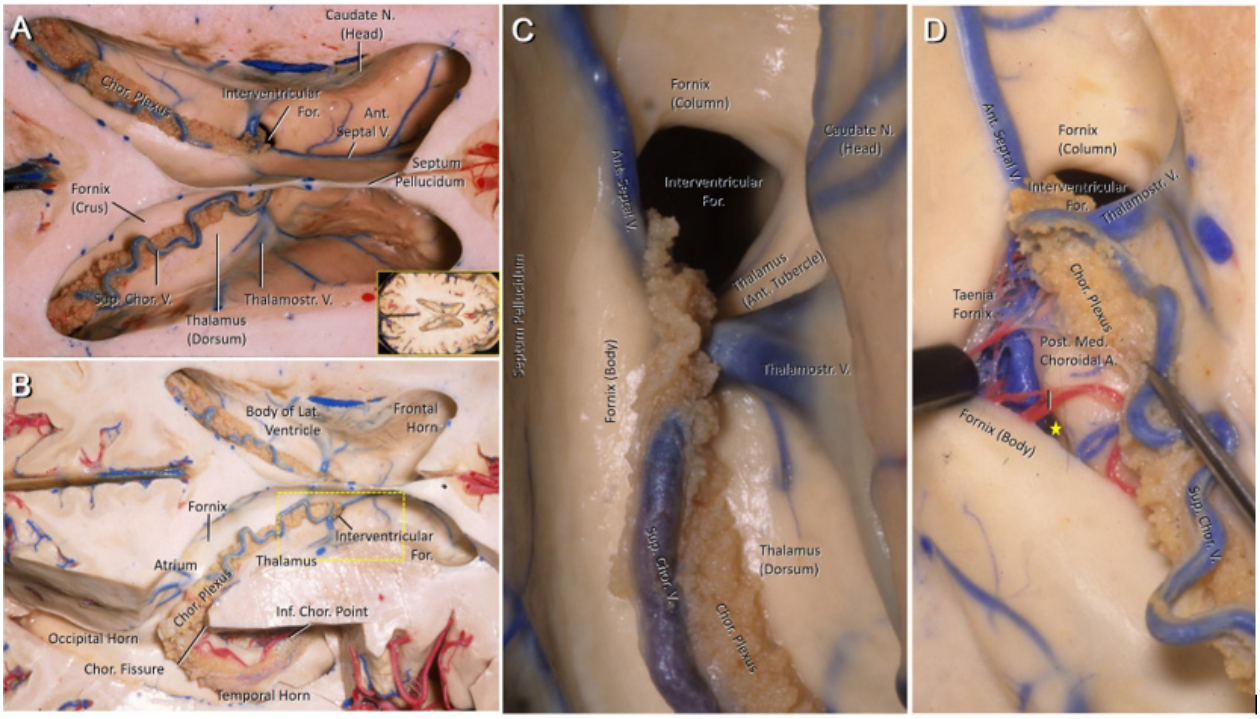

Figure 1. A and B. The macroscopic anatomy of the choroid plexus at the human lateral ventricles is presented following a series of planned cuts that completely expose the choroidal fissure. This planned exposure starts with an axial cut at the level of body of the corpus callosum (insert). The choroidal fissure is an embryonic cleft which acquires a C-shape by the folding of the developing neural tube. At the transition between the frontal horn and the body of the lateral ventricle, the choroidal fissure starts at the level of the interventricular foramen. It extends all the way to the temporal horn, ending at the level of the inferior choroidal point. The choroidal fissure is bounded on one side by the different parts of the fornix and, on the other side by the thalamus. C and D. Microsurgical view of the choroid plexus at the level of the interventricular foramen - which is considered its embryonic enlargement. This microsurgical view - corresponding to the area highlighted by the yellow rectangle in B - was obtained with the magnification of the surgical microscope (which should not be mistaken by the microscopic magnification designed to understand the ultrastructure of tissues). The choroidal plexus is commonly seen and dealt surgically in this area, either by ventricular catheterization/endoscopic procedures, or microsurgically, whenever the choroidal fissure needs to be opened to access other ventricular/cisternal compartments. D. The choroidal fissure is opened by carefully detachment of it from the forniceal taenia. In this fashion, the choroid plexus remains attached to the fissure by its adhesion to the taenia on thalamic side. Note the choroidal arteries and veins crossing the fissure to and from the space of the velum interpositum at the roof of the third ventricle (yellow star). *Ant.: Anterior, Chor.: Choroid, For.: Foramen, Inf.: Inferior, Lat.: Lateral, N.: Nucleus, Sup.: Superior, Thalamostr.: Thalamostriate, V.: Vein.*

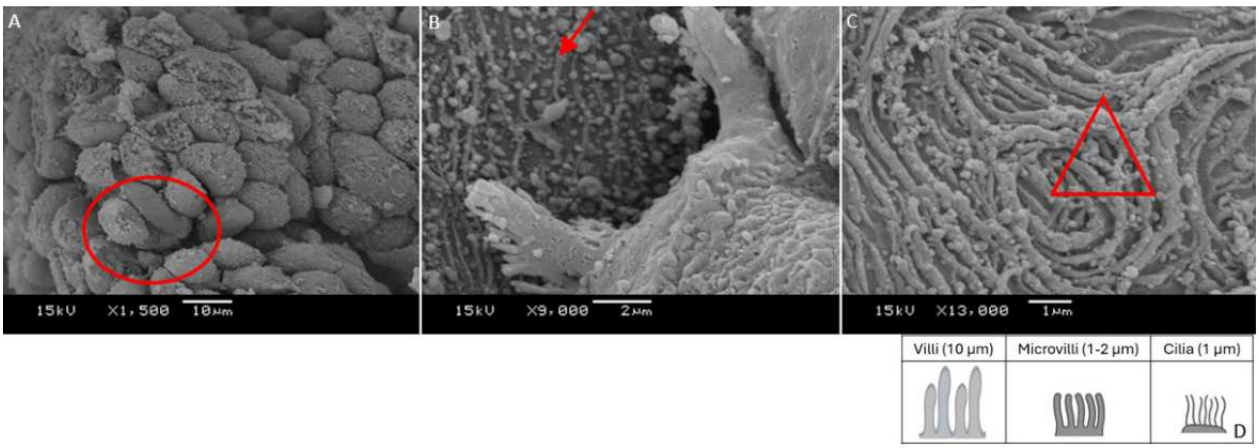

"Figure 2. Scanning electron microscopy of human adult choroid plexus. (A) villi, highlighted by the circle; (B) microvilli, highlighted by the arrow; (C) display interdigitations and cilia, highlighted by the triangle; and (D) schematic representation of the morphological features of the villi, microvilli, and cilia, with scales corresponding to the dimensions observed in the SEM image."

These findings highlight the ChP specialized surface architecture and intricate cellular organization which are fundamental to its role in maintaining CSF homeostasis and regulating intracranial pressure. Disruptions in the morphology or function of this complex structure can have profound implications, potentially contributing to the onset or exacerbation of headaches.

By providing detailed macroscopic, microsurgical anatomical and ultrastructural insights on the ChP, this study establishes a bridge between the fundamental aspects of the ChP seen by different fields of knowledge. It also provides the basis for future research aiming at clarifying the ChP involvement in headache and its pathophysiology, as well as to explore its potential as a therapeutic target, shedding light on this vital, yet underexplored structure.

Conclusion

The ChP is a highly specialized structure with critical roles in cerebrospinal fluid (CSF) production, intracranial pressure regulation, and brain homeostasis. This study integrates macroscopic, microsurgical, and microstructural analyses, comprehensively understanding its anatomical and functional attributes. The macroscopic dissections highlighted the ChP's C-shaped configuration in the lateral ventricles and its attachment along the choroidal fissure while scanning electron microscopy revealed its intricate ultrastructure, including villi, microvilli, and cilia, which underline its active involvement in CSF dynamics.

These findings highlight the ChP's potential contribution to headache pathophysiology, particularly in conditions associated with CSF flow and pressure dysregulation. By bridging neuroanatomy and neuroscience, this work provides a foundation for future investigations into the ChP's role in neurological disorders and its potential as a therapeutic target. A deeper exploration of this vital yet underexplored structure could lead to novel strategies for diagnosing and managing headache disorders and related conditions.

References

1. Martins C, Campero Á, Macêdo BS de, Valença M, Souza Leão CM, Rhoton Jr A. Ventrículos laterales. In: Campero Á, Ajler P, editors. Neuroanatomía quirúrgica, Ciudad Autónoma de Buenos Aires: Ediciones Journal; 2019, p. 22–44.
2. Kratzer I, Ek J, Stolp H. The molecular anatomy and functions of the choroid plexus in healthy and diseased brain. Biochimica et Biophysica Acta (BBA) - Biomembranes 2020;1862:183430. Doi:10.1016/j.bbamem.2020.183430
3. Kuruoglu E, Cokluk C, Marangoz AH, Aydin K. Three-dimensional microsurgical anatomy of the choroid plexus using volume rendering technique. Turk Neurosurg 2014. Doi:10.5137/1019-5149.JTN.11473-14.1
4. Slater L-A, Hoffman C, Drake J, Krings T. Pre-operative embolization of a choroid plexus carcinoma: review of the vascular anatomy. Child's Nervous System 2016;32:541–5. Doi:10.1007/s00381-015-2851-y
5. Mortazavi MM, Griessenauer CJ, Adeeb N, Deep A, Shahripour RB, Loukas M, et al. The choroid plexus: a comprehensive review of its history, anatomy, function, histology, embryology, and surgical considerations. Child's Nervous System 2014;30:205–14. Doi:10.1007/s00381-013-2326-y
6. Hogue MJ. Human fetal choroid plexus cells in tissue

cultures. Anat Rec 1949;103:381–99. Doi:10.1002/ar.1091030306
7. Dohrmann GJ, Bucy PC. Human choroid plexus: a light and electron microscopic study. J Neurosurg 1970;33:506–16. Doi:10.3171/jns.1970.33.5.0506.
8. Shuangshoti S, Netsky MG. Human choroid plexus: Morphologic and histochemical alterations with age. American Journal of Anatomy 1970;128:73–95. Doi:10.1002/aja.1001280107
9. Otani H, Tanaka O. Development of the chorqid plexus anlage and supraependymal structures in the fourth ventricular roof plate of human embryos: Scanning electron microscopic observations. American Journal of Anatomy 1988;181:53–66. Doi:10.1002/aja.1001810107
10. Nógrádi A, Kelly C, Carter ND. Localization of acetazolamide-resistant carbonic anhydrase III in human and rat choroid plexus by immunocytochemistry and in situ hybridisation. Neurosci Lett 1993;151:162–5. Doi:10.1016/0304-3940(93)90011-9
11. Serot JM, Bene MC, Faure GC. Comparative immunohistochemical characteristics of human choroid plexus in vascular and Alzheimer's dementia. Hum Pathol 1994;25:1185–90. Doi:10.1016/0046-8177(94)90035-3
12. Catala M. Carbonic anhydrase activity during development of the choroid plexus in the human fetus. Child's Nervous System 1997;13:364–8. Doi:10.1007/s003810050101
13. Sasaki A, Iijima M, Yokoo H, Shoji M, Nakazato Y. Human choroid plexus is an uniquely involved area of the brain in amyloidosis: a histochemical, immunohistochemical and ultrastructural study. Brain Res 1997;755:193–201. Doi:10.1016/S0006-8993(97)00097-8.
14. Jovanović I, Stefanović N, Antić S, Ugrenović S, Djindjić B, Vidović N. Morphological and morphometric characteristics of choroid plexus psammoma bodies during the human aging. Ital J Anat Embryol 2004;109:19–33.
15. Zagórska-Swiezy K, Litwin JA, Gorczyca J, Pityński K, Miodoński AJ. Arterial supply and venous drainage of the choroid plexus of the human lateral ventricle in the prenatal period as revealed by vascular corrosion casts and SEM. Folia Morphol (Warsz) 2008;67:209–13.
16. Zagorska-Swiezy K, Litwin JA, Gorczyca J, Pityński K, Miodonski AJ. The microvascular architecture of the choroid plexus in fetal human brain lateral ventricle: a scanning electron microscopy study of corrosion casts. J Anat 2008;213:259–65. Doi:10.1111/j.1469-7580.2008.00941.x.
17. Redzic ZB. Studies on the human choroid plexus in vitro. Fluids Barriers CNS 2013;10:10. Doi:10.1186/2045-8118-10-10.

Juliana Ramos de Andrade
https://orcid.org/0000-0002-5445-8872
Carolina Martins
https://orcid.org/0000-0002-0197-3520
Marcelo Moraes Valença
https://orcid.org/0000-0003-0678-3782

Authors contribution: JRA, data collection, writing – original draft, writing – results, writing – review & editing, approval of the final version; CM: data collection, writing – original draft, writing – results, writing – review & editing, approval of the final version; MMV, conceptualization, supervision, writing – original draft, writing – review & editing, approval of the final version as the supervisor.
Conflict of interest: none
Funding: none