



Susac syndrome: ophthalmological and auditory manifestations in a patient with headache - case report

Lucas Brandão Damasceno Góes¹, Carolina Brandão Damasceno Góes², Carolina Brito de Almeida¹, João Lucas Campos Nunes Hübner², Kimble Teixeira Fonseca Matos¹

¹Santa Casa de Santos, Santos, Sao Paulo, Brazil

²Faculty of Medical Sciences of Minas Gerais, Belo Horizonte, Minas Gerais, Brazil



Lucas Brandão Damasceno Góes
lbdgoes@gmail.com

Edited by:

Marcelo Moraes Valença

Keywords:

Susac's Syndrome
Retinocochleocerebral Vasculopathy
Retinal Artery Occlusions
Vasculitis
Retinal

Abstract

Introduction

The first case reports of Susac Syndrome emerged in 1979 due to two young female patients presenting with the clinical triad of multifocal encephalopathy, occlusion of the central retinal artery branch, and sensorineural hearing loss, as well as histopathological findings of microinfarctions in the gray and white matter of the brain. The clinical features of the syndrome have been documented in approximately 500 cases published worldwide, making it extremely rare. Headache is a prominent complaint by patients with Susac syndrome. Its pathophysiology remains unknown, with immune and genetic factors being most related to the retino-cochleo-cerebral clinical manifestations. Since its first description, the scientific community has been paying greater attention to the syndrome, especially with advances in medical technology and the availability of complementary exams.

Case report

In this study, we present a case report of a woman experiencing progressive pulsatile temporal headaches for two years, associated with decreased visual acuity for three months and simultaneous hypoacusis on the left, who was incorrectly diagnosed and treated for multiple sclerosis.

Comment

The literature review discusses Susac Syndrome and its microvascular complications, highlighting the multidisciplinary approach necessary for accurate diagnosis and comprehensive long-term management.

Submitted: April 30, 2024
Accepted: June 24, 2024
Published online: June 29, 2024



Introduction

Susac syndrome (SS) is a rare, inflammatory and autoimmune vasculitis that mainly affects small-caliber vessels. It is characterized by a triple involvement affecting the arterioles of the cochlea, retina and central nervous system (1). Patients with SS usually present with a clinical triad of encephalopathy, hearing loss and asymmetrical visual acuity impairment, which are not always present at the time of diagnosis (2).

Microangiopathic encephalopathy can range from mild to severe, with the main finding being headache, which occurs in 80% of patients (3) and can be a constant manifestation, with a pattern similar to a migraine. Most of the descriptions of headaches experienced with SS show typical migraine characteristics, such as a pulsating quality, aggravated by routine physical activity and possibly associated with nausea, vomiting, photophobia and phonophobia. The recurrence or exacerbation of cephalalgia can be indicative of the involvement and activity of the disease, as well as alerting us to possible changes needed in the management and treatment of the syndrome (2, 3). In addition, encephalopathy can also be characterized by mood swings, vertigo, dysarthria, ataxia, hemiparesis, memory loss, mental confusion, epileptic seizures and even coma (4).

Ocular alterations include decreased visual acuity due to vascular involvement of the central retinal artery with multiple bilateral occlusions and sudden reduction in visual acuity. Angiofluoresceinography is a fundamental tool, as it demonstrates hyperfluorescence of the arterial wall of the arterioles at various locations along the course of the vessels, which is suggestive of a primary endotheliopathy (5), as well as showing areas of hypoperfusion due to arterial occlusions. The multifocal electroretinogram can be used to document focal retinal dysfunctions related to branch occlusions of the central retinal artery (2, 5).

Hearing loss is sensorineural and is identified by unilateral or bilateral audiometry; however, other symptoms such as vertigo, nystagmus, nausea and vomiting may also be present (6).

Although SS is a rare disease, the number of diagnosed cases has increased over the years, probably due to increased awareness among doctors and better diagnostic techniques. However, SS is still frequently underdiagnosed, as the symptoms are often non-specific and can be confused with other pathologies. In cases where only encephalopathy is present, or due to a lack of recognition of the other two components of the SS triad, a misdiagnosis of multiple sclerosis or acute disseminated encephalomyelitis can be made and patients are treated with a course of corticosteroids, where initial improvement is possible, but with eventual relapse when the drugs are

gradually reduced or discontinued (2). Currently, some cases of SS are related to Covid-19 (7, 8).

Therefore, the aim of this paper is to present a rare case of occlusion of the central retinal artery, associated with hypoacusis and headache for 2 years, with SS as the neuroophthalmological diagnosis.

Case Report

The patient was a 48-year-old woman who had been complaining of progressive pulsatile temporal headache for 2 years, associated with low visual acuity for 3 months and hypoacusis referred to the left at the same time. She had a previous history of corticosteroid treatment due to the unconfirmed diagnostic hypothesis of multiple sclerosis. On ophthalmologic examination, she had best-corrected visual acuity of 20/30 in the right eye (RE) and no light perception in the left eye (LE). Fundoscopy of the RE showed only papilla edema in the superior temporal region and in the LE there was optic disc pallor, a macula with reduced brightness, arteriolar narrowing and retinal pallor (Figure 1).




Figure 1. SITA STANDART mode computerized campimetry with reliable parameters, showing altitudinal scotoma in the right eye and total scotoma in the left eye.

Campimetry showed altitudinal scotoma in the RE and total scotoma in the LE (Figure 2). Magnetic resonance imaging of the skull and orbits showed no alterations. Arterial and venous phase magnetic resonance angiography of the skull showed a 3.0 x 2.6 mm saccular aneurysmal dilatation with a 2.5 mm neck of the right posterior communicating artery at the emergence of the right internal carotid artery, as well as diffuse microangiopathy. Cerebral angiography showed a saccular aneurysm of the cavernous segment of the right internal carotid artery. Liquor without alterations. Audiometry showed bilateral sensorineural loss. Based on the clinical and radiological findings, the diagnosis of SS was proposed. The patient was treated with methylprednisolone pulse therapy and discharged to outpatient follow-up with oral corticosteroid therapy in slow regression, with no new complaints during follow-up over the next 5 months with the neurology,



ophthalmology and otorhinolaryngology teams.

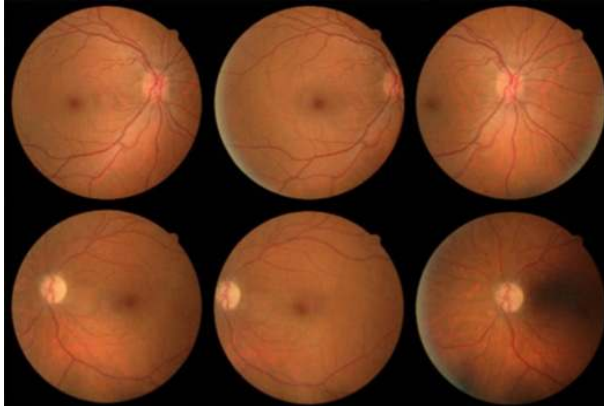


Figure 2. Color retinography of both eyes, showing in the right eye slight papilla edema in the superior temporal region and in the left eye, presence of optic disc pallor, macula with reduced brightness, arteriolar narrowing and retinal pallor.

Discussion

Susac syndrome is a rare, potentially serious condition that can lead to neurological, visual and hearing impairment. Early diagnosis and appropriate treatment are key to preventing sequelae and improving patients' prognosis.

A detailed neurological examination is of the utmost importance to rule out differential diagnoses such as multiple sclerosis or demyelinating episodes. In addition, neuroimaging adds findings, such as magnetic resonance imaging of the skull, which shows small multifocal hyperintensities in T2, predominantly in the white matter, which can affect the center of the corpus callosum. These lesions have a "snowball" appearance, representing areas of microinfarcts (2). Periventricular and other subcortical regions may also be affected, as well as the internal capsule, which may have a "string of pearls" appearance on diffusion-weighted imaging (DWI). The presence of "snowballs" and "pearl necklaces" seems to be relatively specific for SS in the clinical context of suggestive findings (2). Less commonly, lesions can be seen in deep regions of the gray matter. Sequelae include general atrophy of the cortex and cerebellum.

The ophthalmologic findings described above may be the first manifestations of the clinical picture of SS and can occur at any time or stage of the disease. The presence of yellowish-white plaques on color retinography, known as Gass plaques (9) – lipid deposits accumulated in the damaged vascular wall - which, unlike Hollenhorst plaques, are located outside the arteriolar bifurcations, in addition to the finding of hyperfluorescence of the arteriolar wall - are considered pathognomonic of SS. Another finding is the normality of the choroidal circulation, proven by indocyanine green angiography. In the presence of suggestive findings, the patient should be immediately

referred for neurological assessment.

Otorhinolaryngological assessment depends on audiometry, which shows loss of low and middle frequencies due to acute or insidious microinfarctions of the cochlear apex arterioles (10). Hearing loss, when bilateral and severe, is one of the indications for cochlear implants. In cases of encephalopathy associated with hearing loss, brainstem evoked potentials can be used. Finally, ophthalmologists, neurologists and otorhinolaryngologists should be aware of the symptoms of the disease and consider the possibility of SS in cases of patients with encephalopathy, hearing loss and low visual acuity, aiming for early treatment, follow-up and rehabilitation when necessary.

References

1. Susac JO, Hardman JM, Selhorst JB. Microangiopathy of the brain and retina. *Neurology*. 1979;29(3):313-313. Doi 10.1212/wnl.29.3.313
2. Rennebohm R, Susac JO, Egan RA, Daroff RB. Susac's Syndrome — Update. *Journal of the Neurological Sciences*. 2010;299(1-2):86-91. Doi 10.1016/j.jns.2010.08.032
3. Dawe JA, Green AL. Headache in Susac's Syndrome. *Current Pain and Headache Reports*. 2021;25(4). Doi 10.1007/s11916-021-00939-2
4. Heiskala H, Somer H, Kovanen J, Poutiainen E, Karli H, Haltia M. Microangiopathy with encephalopathy, hearing loss and retinal arteriolar occlusions: Two new cases. *Journal of the Neurological Sciences*. 1988;86(2-3):239-50. Doi 10.1016/0022-510x(88)90102-5
5. McLeod DS, Ying HS, McLeod CA, Grebe R, Lubow M, Susac JO, et al. Retinal and Optic Nerve Head Pathology in Susac's Syndrome. *Ophthalmology*. 2011;118(3):548-52. Doi 10.1016/j.ophtha.2010.07.012
6. Petty GW, Engel AG, Younge BR, Duffy J, Yanagihara T, Lucchinetti CF, et al. Retinocochleocerebral Vasculopathy. 1998;77(1):12-40.
7. Venditti L, Rousseau A, Ancelet C, Papo T, Denier C. Susac syndrome following COVID-19 infection. *Acta Neurologica Belgica*. 2020;121(3):807-9. Doi 10.1007/s13760-020-01554-5
8. Malerbi FK, Schoeps VA, T F Matos K. Paracentral acute middle maculopathy in Susac syndrome after dual exposure to SARS-CoV-2 antigen. *BMJ Case Reports*. 2022;15(5). Doi 10.1136/bcr-2021-247159
9. Martinet N, Fardeau C, Adam R, Bodaghi B, Papo T, Piette J-C, et al. Fluorescein and Indocyanine Green Angiographies in Susac Syndrome. *Retina*. 2007;27(9):1238-42. Doi 10.1097/IAE.0b013e31809ff824
10. Bitra RK, Eggenberger E. Review of Susac syndrome. *Curr Opin Ophthalmol*. 2011;22(6):472-6. Doi 10.1097/ICU.0b013e32834bbf6b



Lucas Brandão Damasceno Góes
<https://orcid.org/0000-0001-5937-1744>
Carolina Brandão Damasceno Góes
<https://orcid.org/0009-0006-1250-0709>
Carolina Brito de Almeida
<https://orcid.org/0009-0006-2983-0632>
João Lucas Campos Nunes Hübner
<https://orcid.org/0009-0007-0599-4584>
Kimble Teixeira Fonseca Matos
<https://orcid.org/0000-0003-3609-2667>

Author contributions: All designated authors provided contributions to this manuscript, drafted and revised the text, approved its final version, and agreed to be responsible for all aspects of the work.

Conflict of interest: No conflicts of interest to declare.

Funding: This research has not received specific funding from any funding agency in the public, commercial, or non-profit sectors.